

Arquivos de Zoologia

MUSEU DE ZOOLOGIA DA UNIVERSIDADE DE SÃO PAULO

ISSN 0066-7870

ARQ. Zool., S. PAULO 33(1): 1-70

29.IV.1996

THE JAW APPARATUS OF THE NEOTROPICAL AND OF THE AFROTROPICAL WOODPECKERS (AVES: PICIFORMES)

REGINALDO JOSÉ DONATELLI

ABSTRACT

The jaw apparatus of the Neotropical and of the Afrotropical species of the three subfamilies of woodpeckers are described and illustrated. Eighty five percent of the Afrotropical and about 60% of the Neotropical genera are represented. Campephilus rubricollis was used as the pattern on which these anatomical descriptions were based. The present study showed that there are more differences among the species of the three subfamilies than divergences between the Afrotropical and Neotropical groups. The Jynginae are the most divergent among the Picidae, while the Picumninae and the Picinae share many characteristics. The differences of foraging methods and habits adopted by these woodpeckers are not reflected in the structures of the cranial osteology and ligaments, or in the jaw musculature and tongue.

Keywords: Jaw apparatus, Neotropical, Afrotropical, woodpeckers, Picidae.

INTRODUCTION

For over a century woodpeckers are being a subject of investigation. They are birds that call attention for many reasons: by their size and color, by the way they forage and build their nests, by the way they climb vertical surfaces and by the standpoint of the instrumental signals they make. Curiously, many of the behavior patterns related to the woodpecker's life are closely linked to their anatomical peculiarities. Consequently, an investigation of these parameters should not be dissociated from anatomy.

Through the studies of birds one observes that anatomical investigations serve for many pur-

poses. One of these was pointed out by Raikow (1987) when he studied four groups of the Old World passerine birds: "is to increase our understanding of the evolutionary history by adding to our knowledge of their morphology, reconstructing their phylogeny...". Particularly, in relation to woodpeckers, we could understand many purposes since Garrod (1872) observed that the head of a woodpecker plays the role of a powerful hammer due to the thickness of the bones of the skull, which can afford intense pounding. Many other investigators studied woodpecker's anatomical characteristics and sought for answers on: their taxonomic position (Parker, 1875; Goodwin, 1968), their systematics or relationships among intra-

and inter groups (Shufeldt, 1891; Scharnke, 1930; Goodge, 1972), aspects of their tongue apparatus (Steinbacher, 1934, 1935 and 1955), functional anatomy (Spring, 1965), anatomical aspects associated with behavior (Burt, 1930; Bock & Miller, 1959; Wallace, 1974 and Kirby, 1980), and other anatomical systems (Jenni, 1981).

According to Peters (1948) and Short (1982) there are three subfamilies of the Picidae: Jynginae (wrynecks), Picumninae (piculets) and Picinae (true woodpeckers). The wrynecks occur only in the Old World (Eurasia and Africa); the piculets are found in tropical Asia, Africa, and mainly, in the American tropics; and the true woodpeckers are found in Eurasia, Africa, and throughout the wooded parts of the Americas.

The present paper deals with the description of the woodpecker's jaw apparatus of the Neotropical and Afrotropical species. The similarities and differences among species are shown through a detailed description of the osteological and myological structures of woodpeckers, not available in the literature until now.

This work may be viewed as a referential guide to new approaches of anatomical studies on woodpeckers, as well as on systematics, biogeography and evolution of the family. This kind of analysis will lead us to the observation of Raikow (*op. cit.*) and will also question the observation of Short (1982:41) in which "the external morphology and behavior are much more reliable to establish the taxonomy of the group than any other data."

This is the first of a paper in three parts concerning woodpeckers; the second one deals with the jaw apparatus of the woodpeckers from the oriental region; while the third one provides information on the two former ones in order to establish a hypothesis on systematics, biogeography and evolution of the Southern Hemisphere woodpeckers, based on morphological (anatomical) data.

MATERIAL AND METHODS

Twenty-one specimens of thirteen species of Picidae were used in this work, representing 85% of the Afrotropical and 60% of the Neotropical genera. The specimens were provided by the

Museu Paraense Emílio Goeldi (MPEG), Pará, Brazil, by the Transvaal Museum (TM), Pretoria, Republic of South Africa and by capture (CP). Specimens are preserved in 70% alcohol v/v (A) or as a complete skeleton (S). Picinae - *Campephilus rubricollis* (Boddaert, 1783) (MPEG A4320-A); *Piculus flavigula* (Boddaert, 1783) (MPEG A6028-A); *Celeus flavescens* (Spix, 1824) (MPEG A5595-A); *Melanerpes cruentatus* (Boddaert, 1783) (MPEG A6019-A); *Colaptes melanochlorus* (Gmelin, 1788) (MPEG A6044-A); *Veniliornis affinis* (Swainson, 1821) (CP) from which only the tongue could be used (deposited at Departamento de Zoologia, USP, São Paulo); *Geocolaptes olivaceus* (Gmelin, 1788) (TM 61770-A); *Campethera abingoni* (Smith, 1836) (TM 60943-A; TM 33120 and 33121-S); *Mesopicus griseocephalus* (Boddaert, 1783) (TM 38218-A); *Dendropicus fuscescens* (Vieillot, 1818) (TM 40813-A; TM 33122 and 33123-S); *Thripias namaquus* (Lichtenstein, 1793) (TM 39077-A; TM 60132-S). Picumninae: *Picumnus cirratus* (Temminck, 1825) [MPEG 1923-S; MPEG A6017-A and (CP)]; Jynginae: *Jynx ruficollis* (Wagler, 1830) (TM 77766-A; TM 33124-S). Classifications by Simpson & Cracraft (1981) and Swierczewinsky & Raikow (1981) were followed.

The cranial osteology, the ligaments, the jaw apparatus and the tongue were studied comparatively and *Campephilus rubricollis* was used as a standard on which these anatomical descriptions were based.

For nomenclature of the cranial osteology I followed the *Nomina Anatomica Avium* (N.A.A., Baumel et al., 1979) and Höfling & Gasc (1984); nevertheless for the jaw musculature description I used Richards & Bock's (1973), with some modifications.

A numbering of the aponeuroses followed the proposal of Höfling & Gasc (1984). Table 1 presents a synonymy of the jaw musculature.

Peters (1948) and Short (1982) agreed with the number of species of Jynginae and Picumninae's, but diverge on the number of species of Picinae: Peters (*op. cit.*) accepts 182 species while Short (*op. cit.*) accepts 169. Short (*op. cit.*) synonymies were not formally proposed, so I am following Peters' (*op. cit.*) classification.

RESULTS

1. Osteology (Figs. 1-62)

1.1. Skull

The frontal (F - Figs. 1-12) region is rostrally articulated with the nasal region through the nasofrontal suture (SNF - Figs. 1-12). *P. cirratus* has a small projection from the frontal bone, which extends over the nasal region (PjF - Fig. 6). This structure was not seen in the other species studied.

In all species studied, a complete fusion of the lacrimal bone with the frontal region could be noticed. A conspicuous lateral expansion in *C. rubricollis* (EL - Fig. 1) was observed in the rostrolateral portion of the lacrimal and frontal regions due to the large development of the lacrimal region in this species; taking into consideration other species, this expansion may have several variations, but is not present in *J. ruficollis*. With the exception of *C. abingoni* (Fig. 8) and *T. namaquus* (Fig. 11) it is a thin bone ridge (Eo) in the median portion of the frontal region. This region also shows a narrow groove which stands out where the epibranchials are lodged (SuEP - Figs. 1-5; 7-11), except in *P. cirratus* and *J. ruficollis*. Only *P. flavigula* has a median longitudinal crest over the frontal region (CrL - Fig. 2).

The lacrimal region (L - Figs. 1-24) is fused rostrolaterally with the upper jaw; laterally and medially it is fused to the ectethmoid bone and to the frontal region, respectively.

The postorbital process (PrPO - Figs. 13-24; 37, 39; 42-45 and 47) is short - it extends about 1/3 of the distance between the skull and the jugal bar - in all species except *C. rubricollis* (Fig. 13) in which it extends about 1/2 of this distance. In *C. flavescens* (Fig. 15) and *T. namaquus* (Fig. 23) it is enlarged at the base; however, in the former, it is less developed. In *J. ruficollis* this process is hardly visible laterally.

The parietal region (P - Figs. 1-24; 37-48) is limited ventrolaterally by the squamosal region (E - Figs. 13-24) through the superior temporal crest (CrTS - Figs. 13-24); it extends laterocaudally to the exoccipital region (EX - Figs. 13-48) through the occipital crest (CrO - Figs. 13-26), and in its median caudal portion, up to the supraoccipital region (SO - Figs. 1-48). The parietal region shows

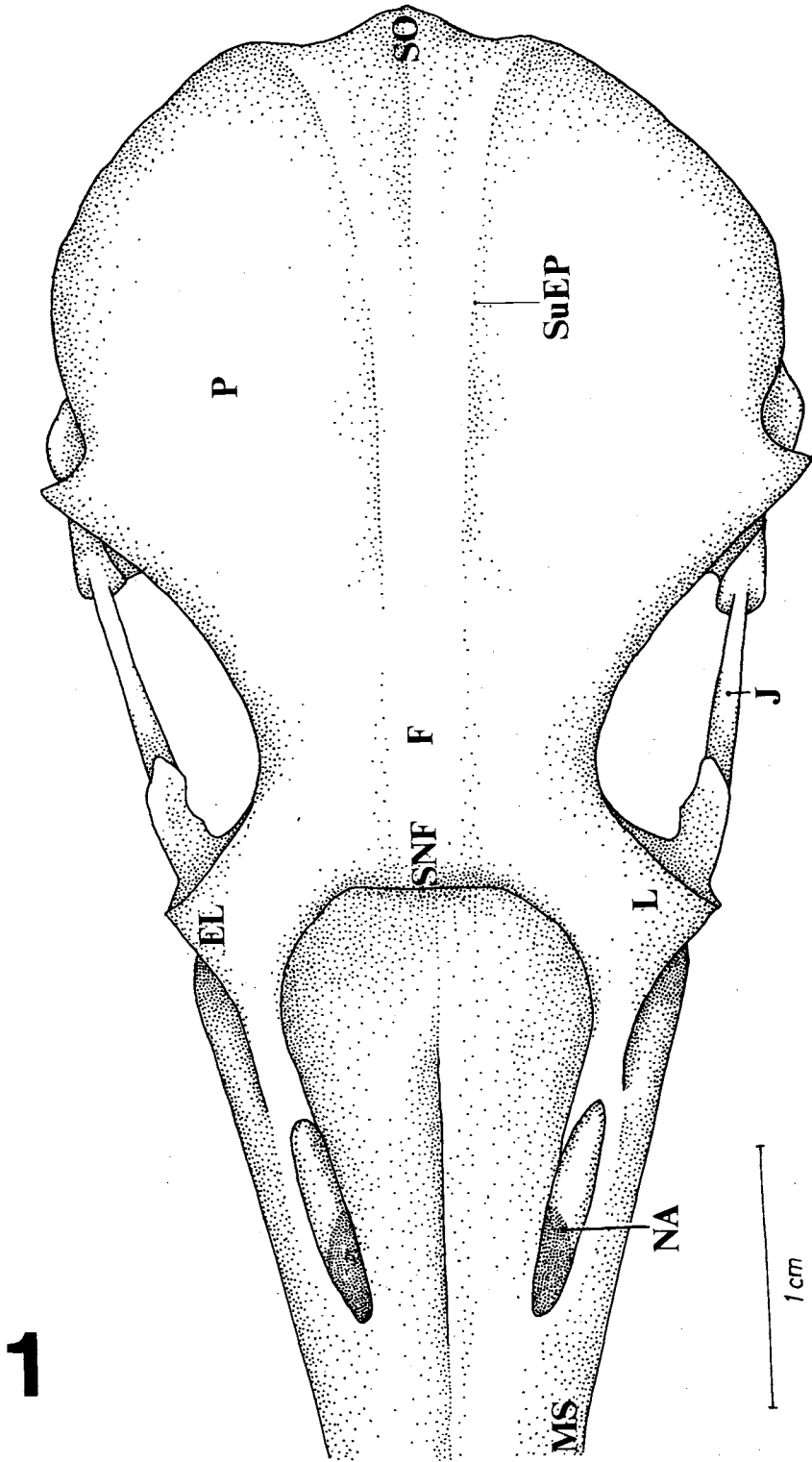
a lateral expansion about 3 times the size of that of the frontal region in most species; in *J. ruficollis* (Fig. 12) it is of about 4.5 times; in *P. flavigula* (Fig. 2), *M. cruentatus* (Fig. 4), *G. olivaceus* (Fig. 7) and *M. griseocephalus* (Fig. 9) it is of about 2 times.

The squamosal region (E - Figs. 13-24) is dorsolaterally bordered by the superior temporal crest (CrTS - Figs. 13-24) and ventrolaterally by the suprêmeatic process (PrSM - Figs. 13-17; 19-23). The latter continues laterorostrally almost reaching the caudal surface of the quadrate and the caudolateral portion of the mandible, in all species except in *P. cirratus* (Fig. 18) and *J. ruficollis* (Fig. 24). It is well-developed in *C. rubricollis* (Fig. 13) and *G. olivaceus* (Fig. 19). In relation to other species, it is thin and somewhat sharp. The temporal fossa is longer vertically than horizontally, except in *T. namaquus* in which the fossa is longer horizontally.

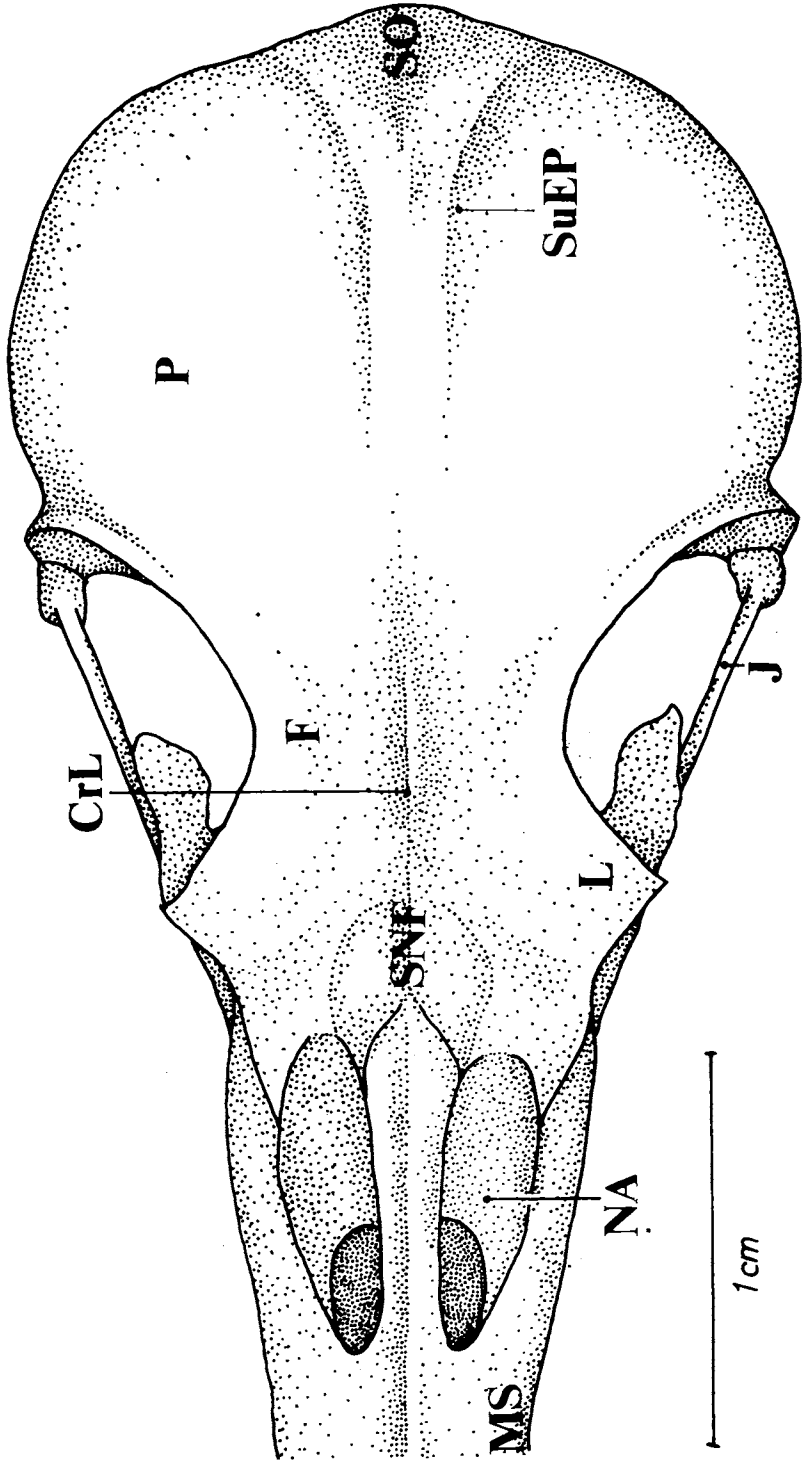
The squamosal process articulates ventrally with the optic process of the quadrate; it shows a well-defined dorsal, lateral, medial and ventral surface. This process is well-developed in *C. rubricollis* (Fig. 13), *C. flavescens* (Fig. 15) and *T. namaquus* (Fig. 23) but less developed in *P. cirratus* (Fig. 18) and *J. ruficollis* (Fig. 24). In relation to the other species, it shows many variations of these conditions. *C. melanochloros* (Fig. 17), particularly, has a thin ventrolateral extension of this process.

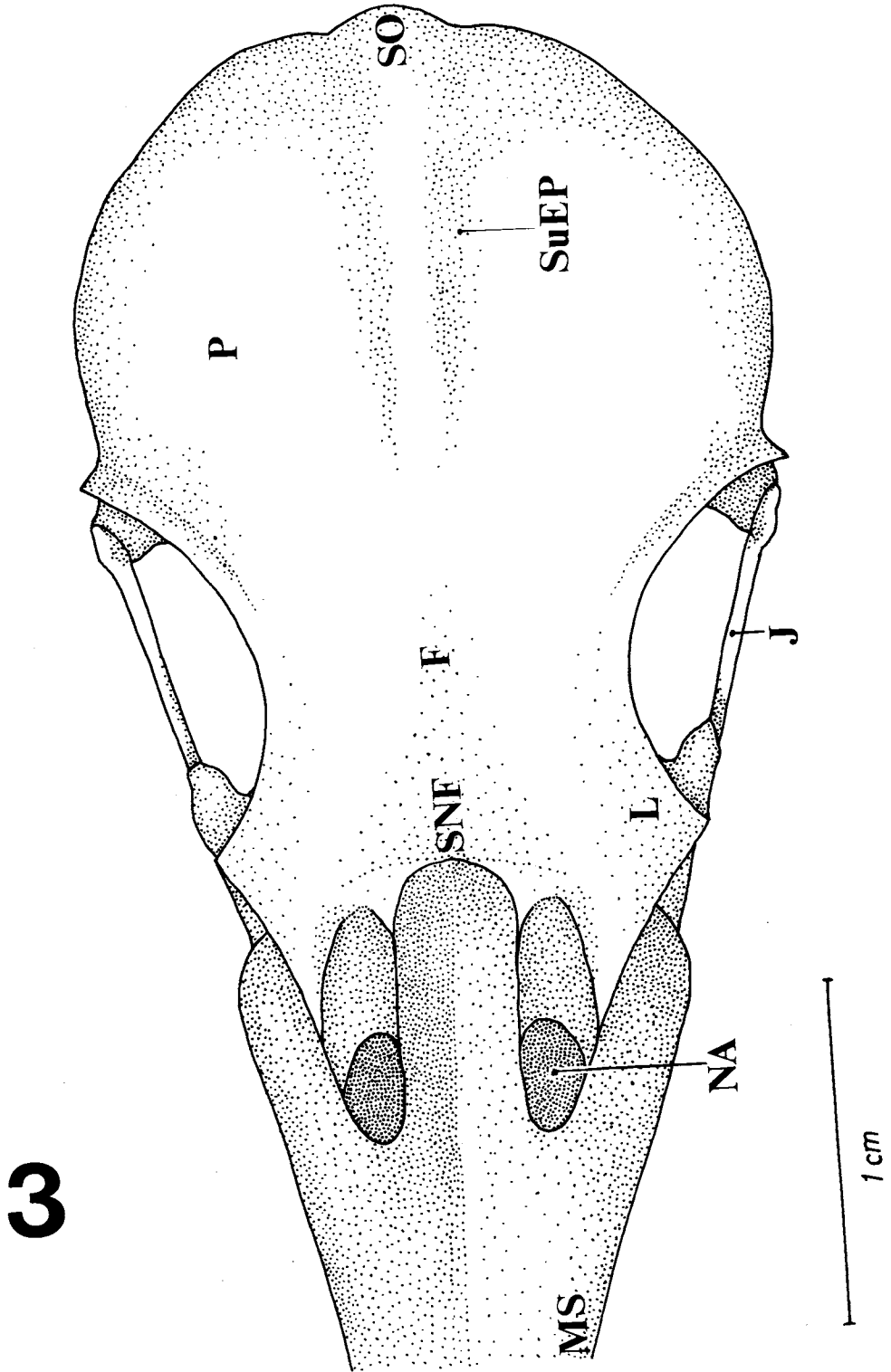
The exoccipital process (PrEX - Figs. 25-29; 31-35) stands out from the occipital region. It is observed in all species except *P. cirratus* and *J. ruficollis*. In general, the larger the species, the more developed the process. The occipital condyle (CO - Figs. 25-48) is surrounded by the subcondilar fossa (fsc - Figs. 26-36), not seen in *C. rubricollis*. The basioccipital region also has a pair of basioccipital processes (PrBA - Figs. 25-29; 31-35) associated to a well-developed basioccipital crest (CrBA - Figs. 25-36). The basioccipital process was not seen in *P. cirratus* and *J. ruficollis*. However, it varies greatly among the species studied.

The sphenoid rostrum (RS - Figs. 25-36) may vary but it is better developed in *C. flavescens* (Fig. 27) and *G. olivaceus* (Fig. 31). In *M. cruentatus* (Fig. 28) it has a large base with a poor forward extension.

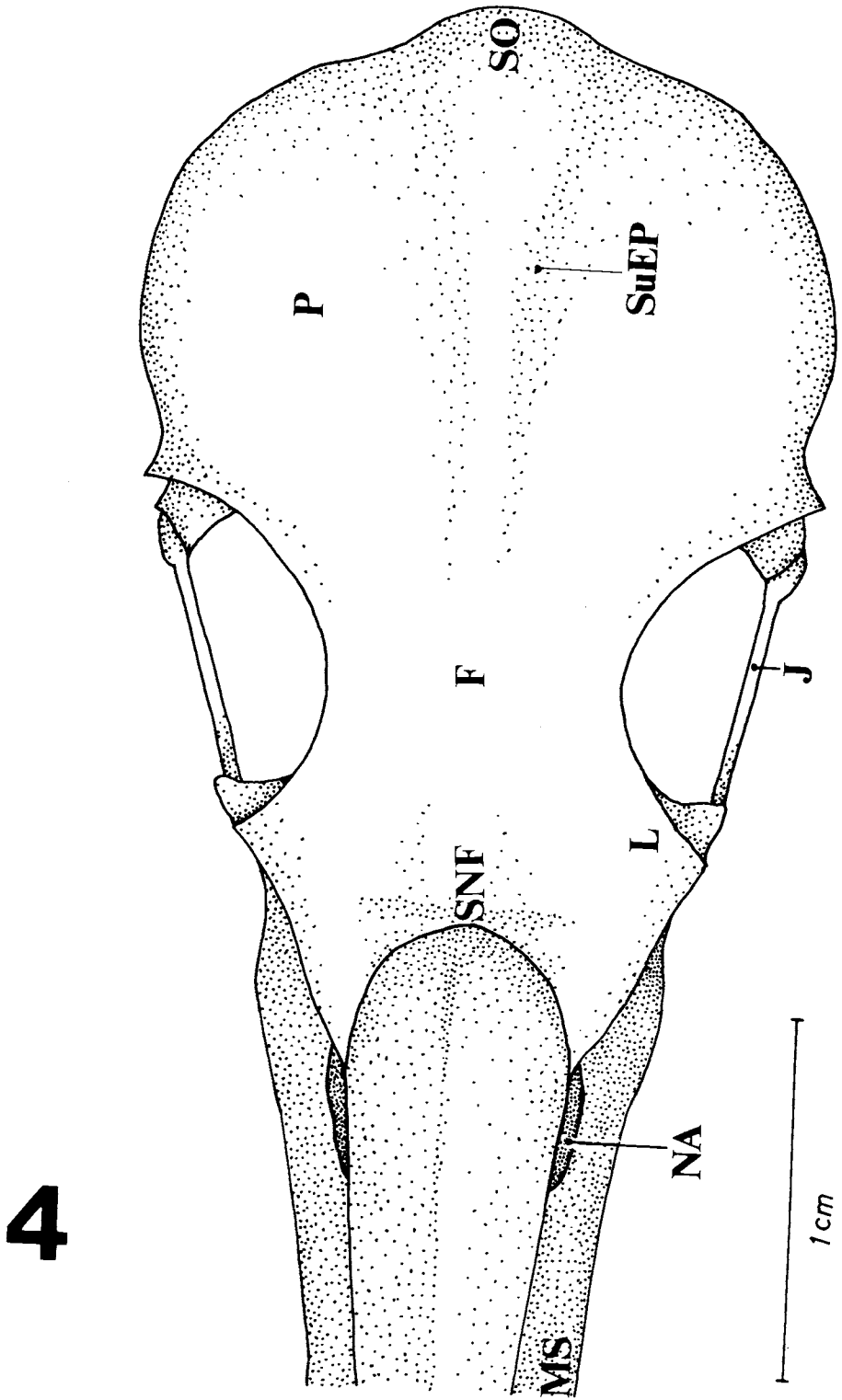


2

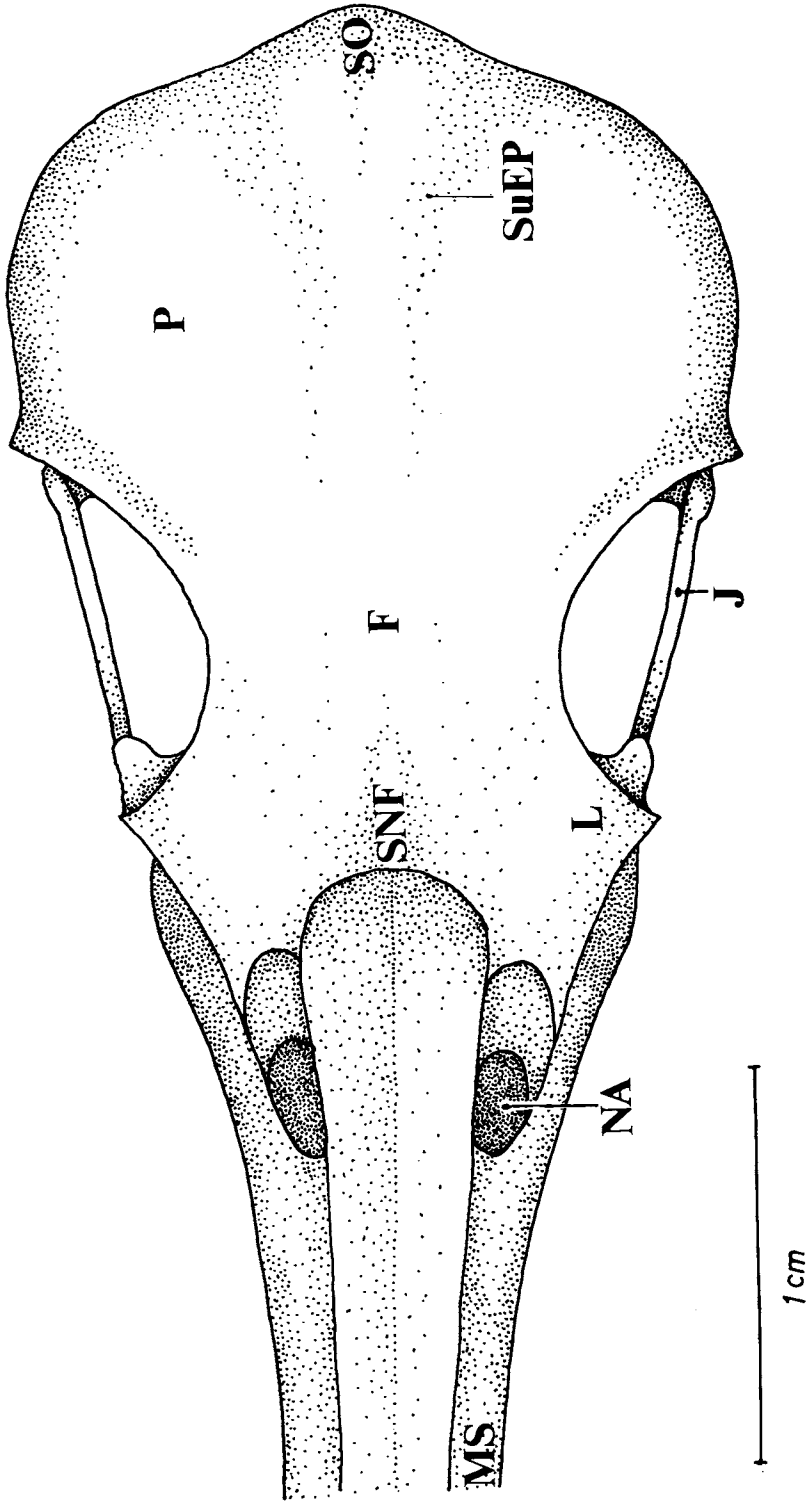




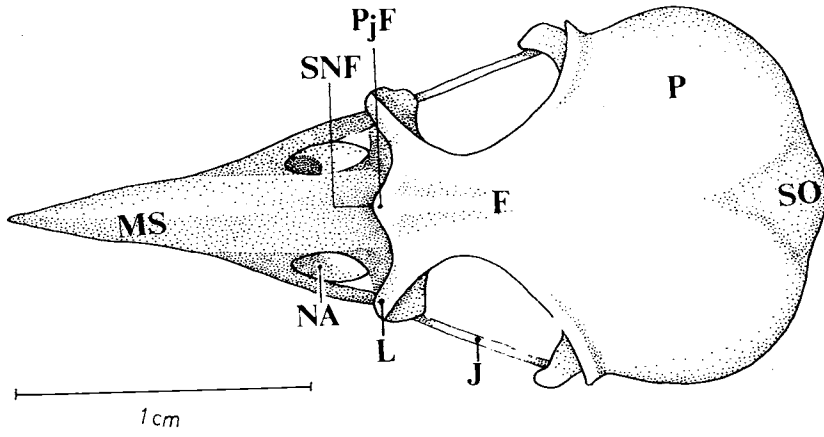
3



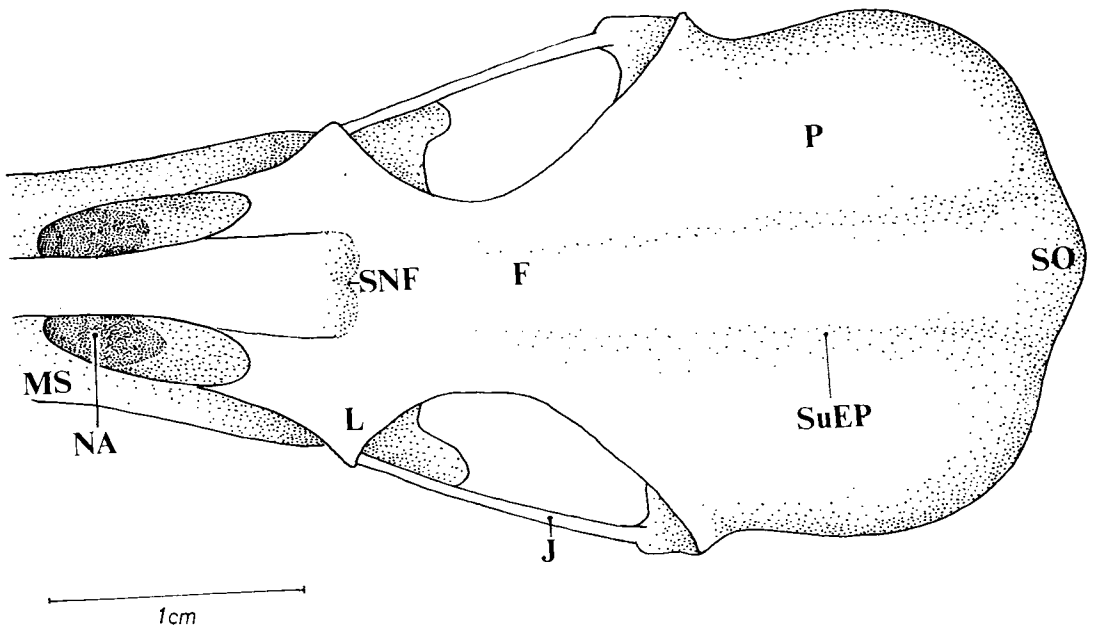
5



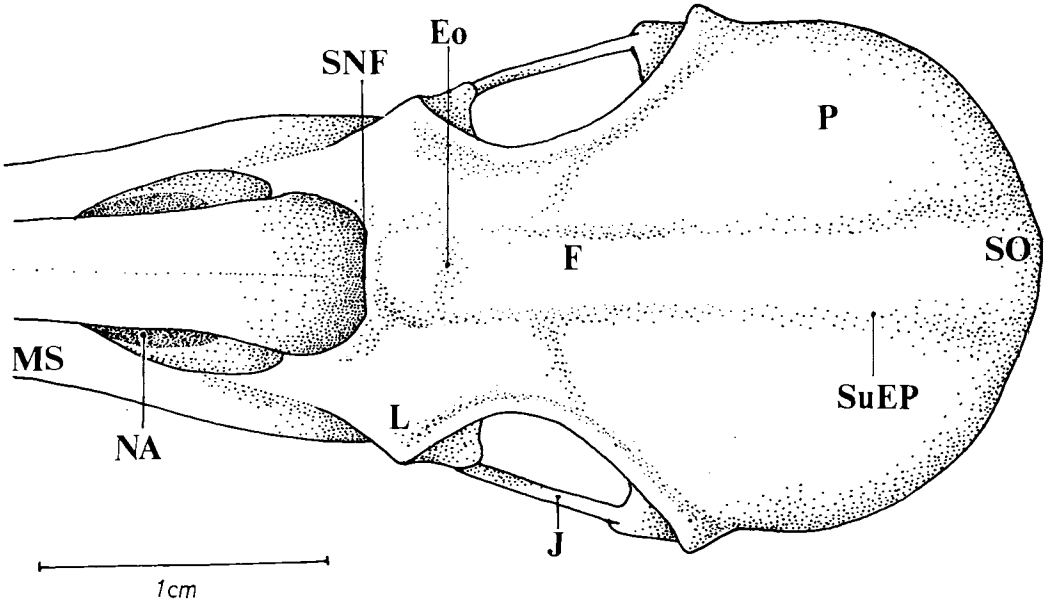
6



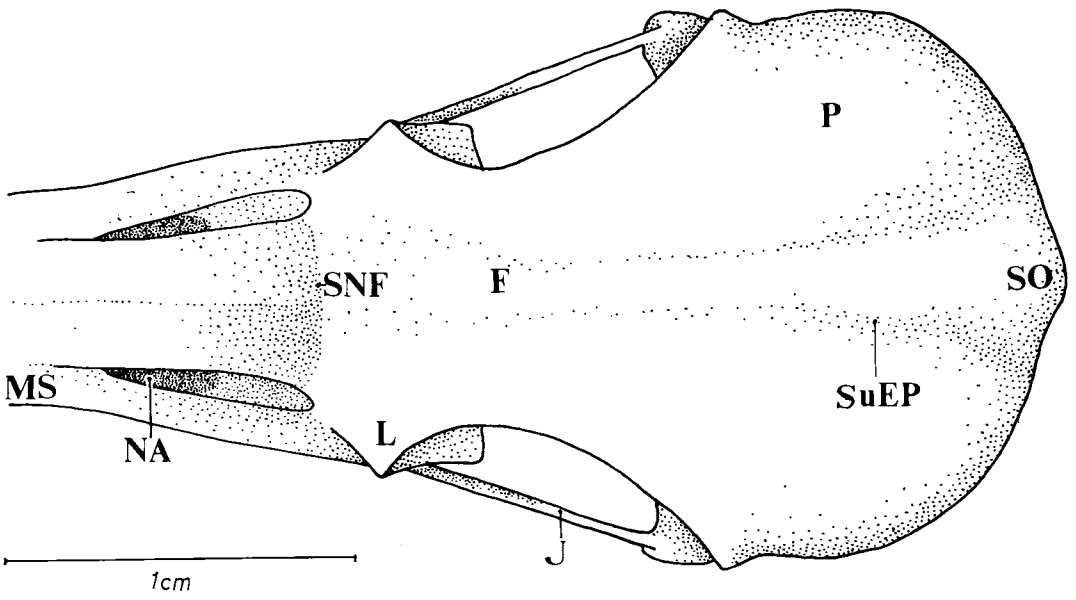
7



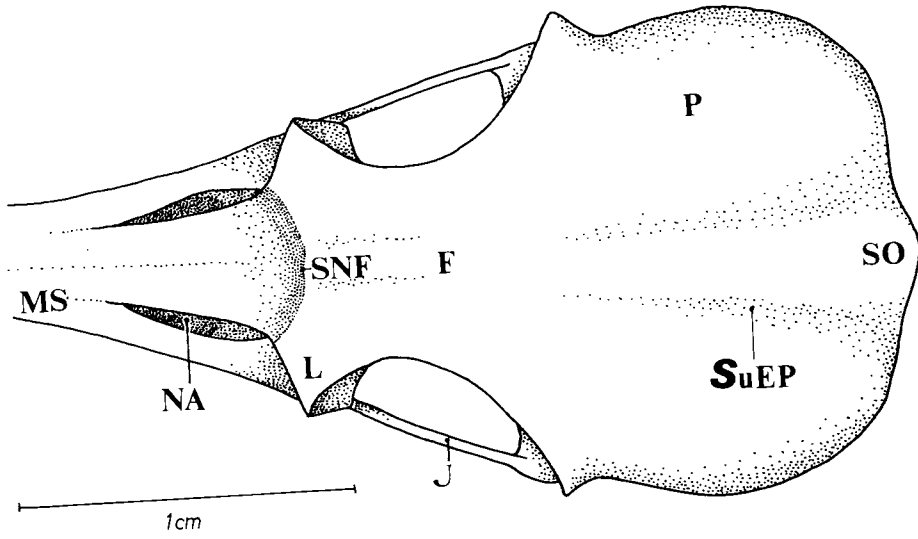
8



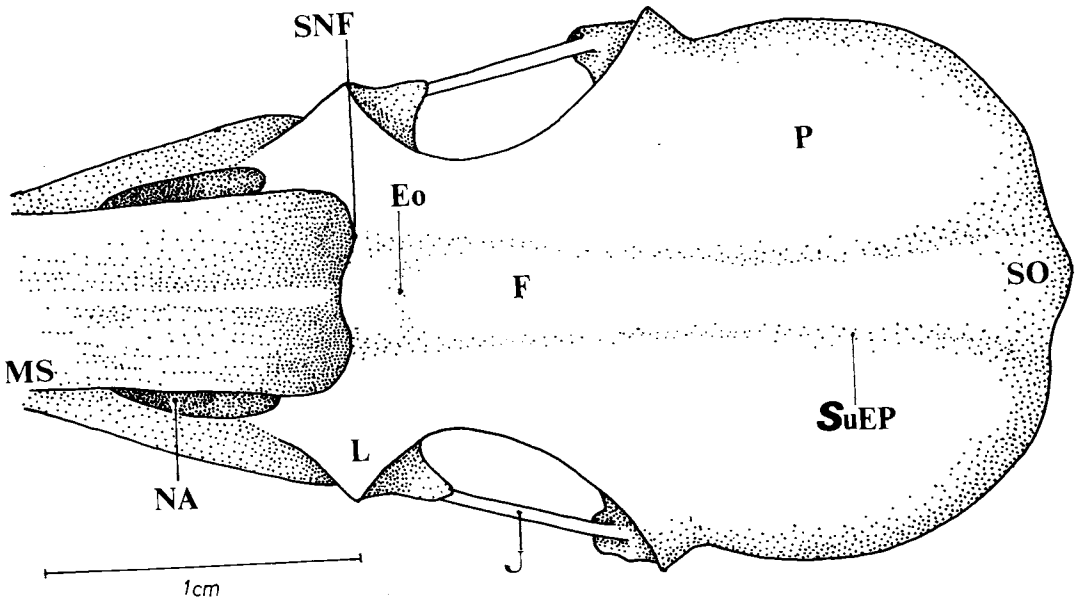
9



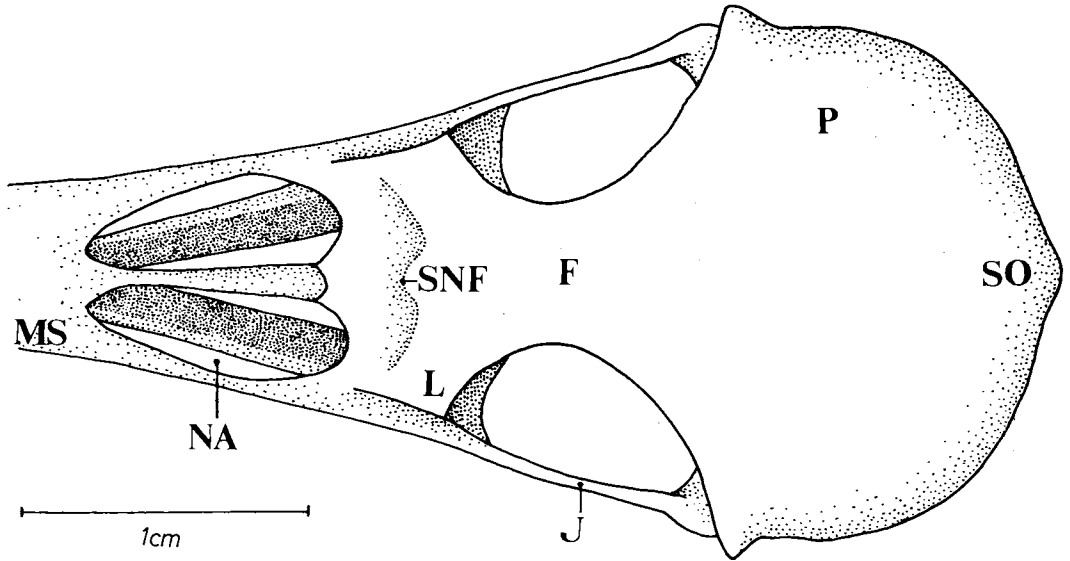
10



11



12



Figures 1-12: Dorsal view of the skull. (1) *Campephilus rubricollis*, (2) *Piculus flavigula*, (3) *Celeus flavescens*, (4) *Melanerpes cruentatus*, (5) *Colaptes melanochloros*, (6) *Picumnus cirratus*, (7) *Geocolaptes olivaceus*, (8) *Campethera abingoni*, (9) *Mesopicus griseocephalus*, (10) *Dendropicus fuscescens*, (11) *Thripas namaquus*, (12) *Jynx ruficollis*.

CrL - longitudinal crest; EL - lateral expansion; EO - bony ridge; F - frontal region; J - jugal bar; L - lacrimar region; MS - upper jaw; NA - nostril; P - parietal region; SNF - nasofrontal suture; SO - supraoccipital region; SuEP - epibranchial sulcus.

The palatal region is composed of the palatine (PA - Figs. 13-36) and the pterygoid bones (PT - Figs. 13-36); the latter has a well-developed rostral extension (ExP - Fig. 49) that articulates with the ventral part of the interorbital septum. On the dorsocaudal portion of the pterygoid bone a well-developed dorsal process (PrD - Fig. 49) is peculiar to all species. However, in *C. melanochloros* and *J. ruficollis* this structure is poorly developed.

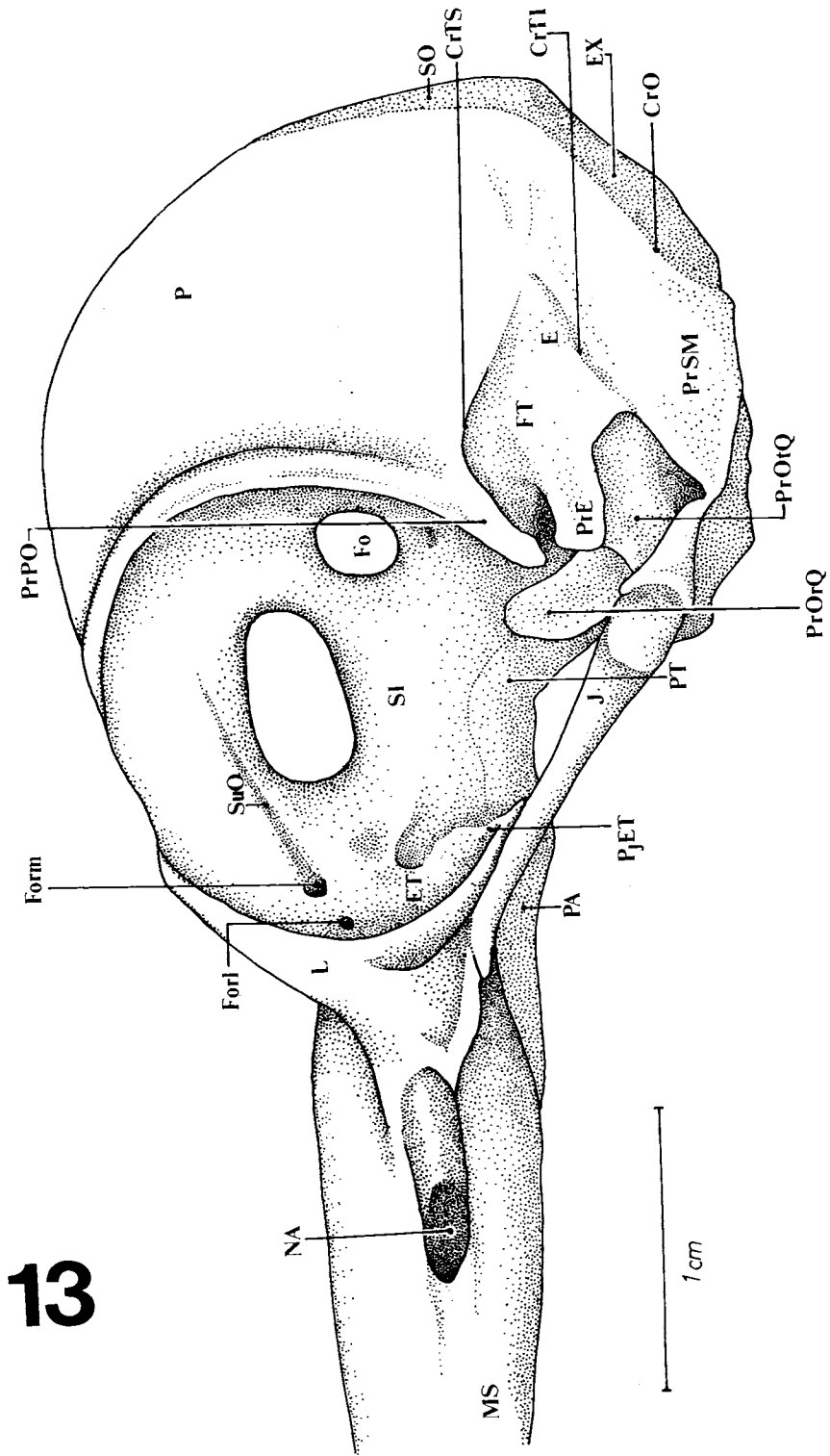
The *Fossa medialis* (FM - Figs. 25-36) is apparently larger in *C. rubricollis* (Fig. 25) and *M. cruentatus* (Fig. 28) and narrower in *P. cirratus* (Fig. 30) and *J. ruficollis* (Fig. 36). An intermediary condition was seen in the other species studied. However, in *C. melanochloros* (Fig. 29), the rostral portion of this fossa is more ample. In *P. cirratus* the ventral palatine crests (Fig. 30) meet midway between the pterygoid/paraesphenoid articulation. The lateral palatine crest (CrLP - Figs.

25-36) can be observed laterally; between the lateral and the ventral palatine crests a well-developed, *i.e.*, a deeper ventral palatine fossa (FV - Figs. 25-36) is seen in *C. rubricollis* (Fig. 25), *P. flavigula* (Fig. 26) and *C. flavescens* (Fig. 27).

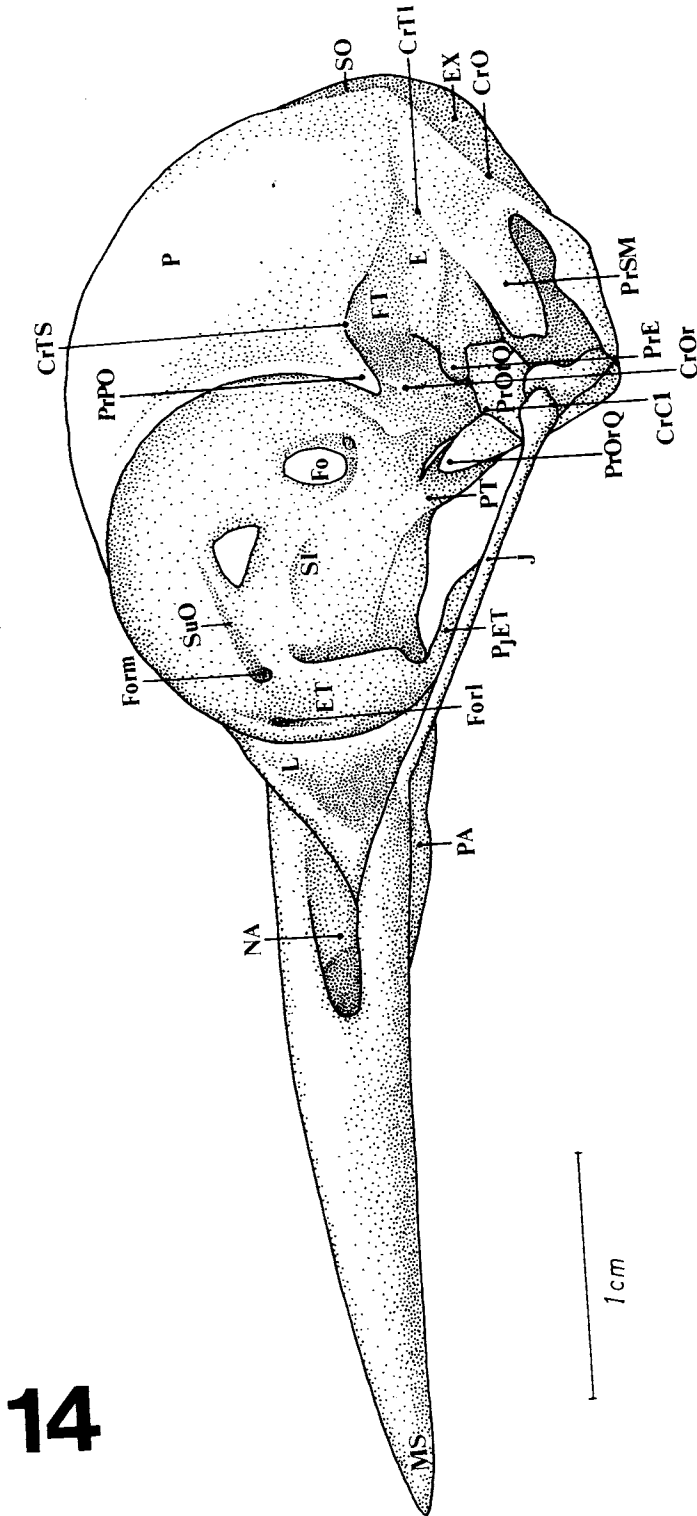
The orbitosphenoid crest (CrOr - Figs. 14-24 and 50) can be seen coming from the orbitosphenoid region; it gives origin to the aponeurosis of the *M. adductor mandibulae externus rostralis medialis*. All species have this structure except *J. ruficollis*. Lastly, in all species studied a well-developed *intumescencia* is found in their ventral portion.

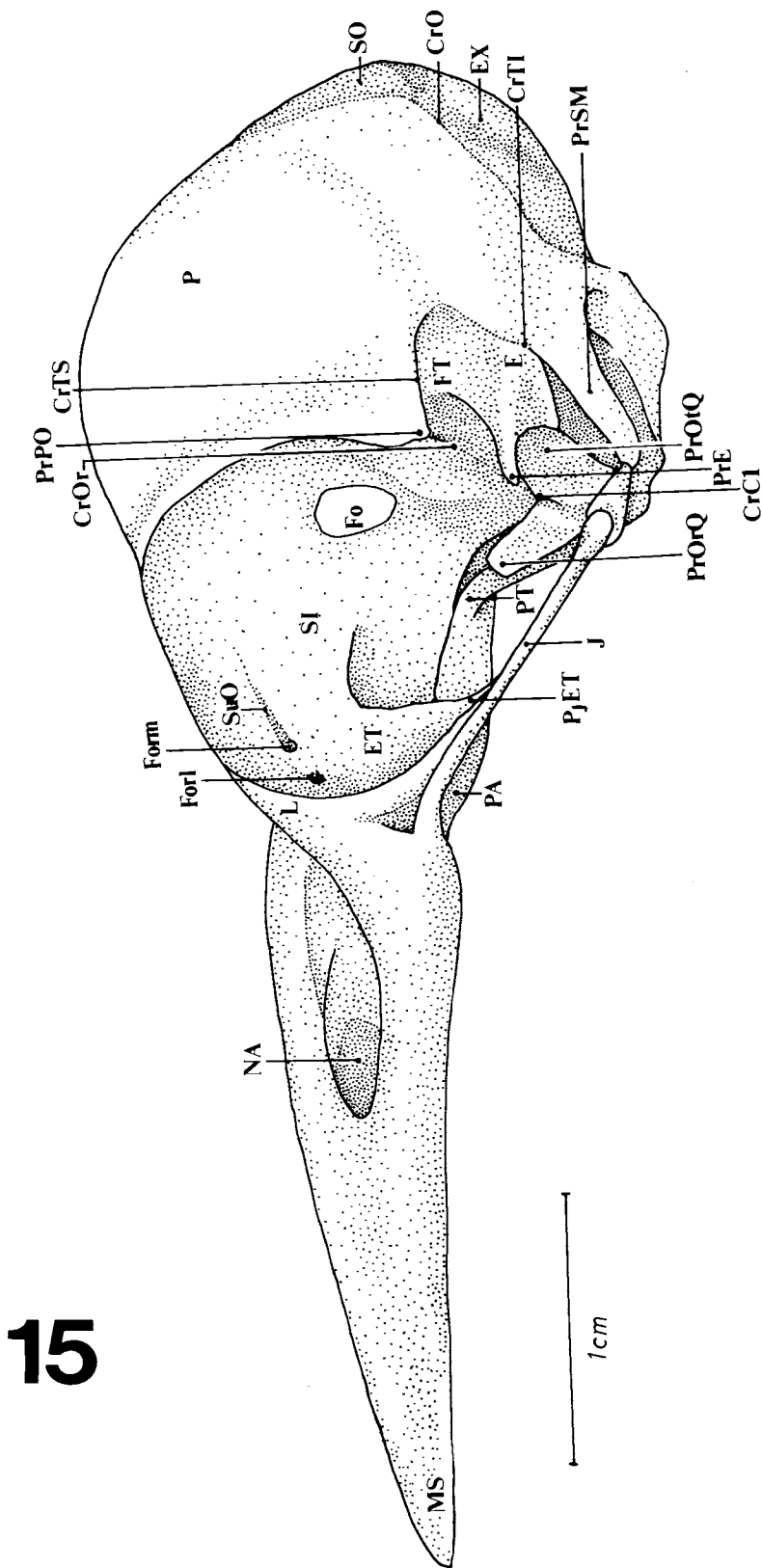
The interorbital septum (SI - Figs. 13-24) shows two foramina in most of the species, except in *C. flavescens* (Fig. 15), *G. olivaceus* (Fig. 19) and *C. abingoni* (Fig. 20).

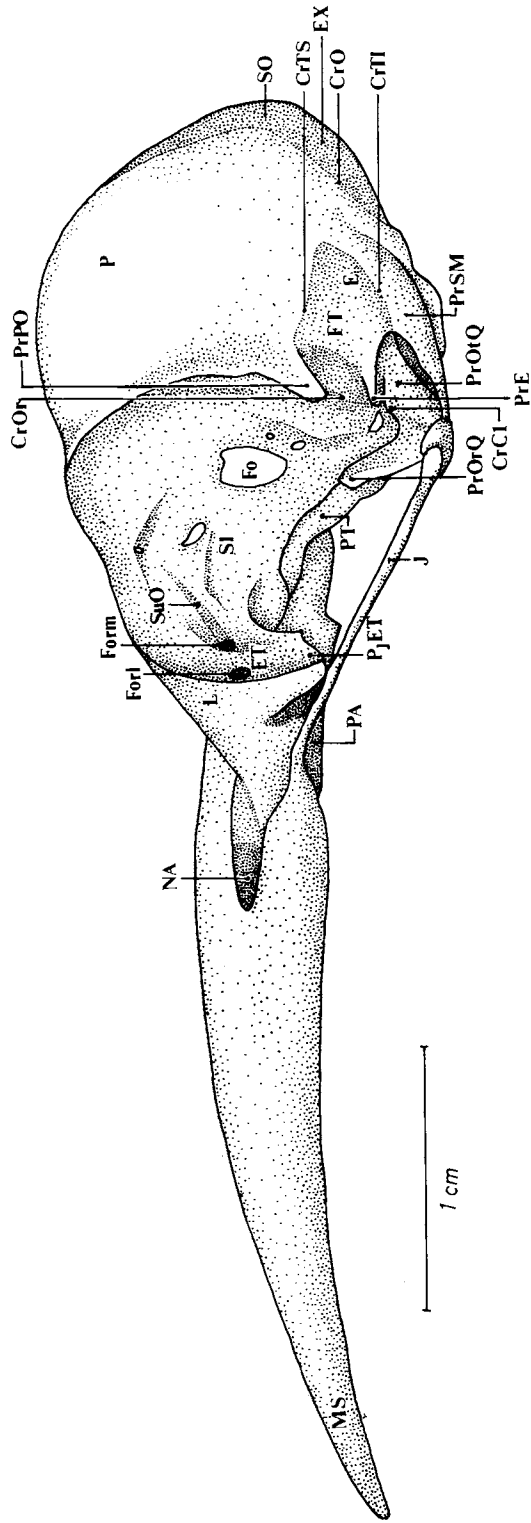
A ventrolateral bony projection (PjET - 13-17; 19-23) is seen coming from the ectethmoid



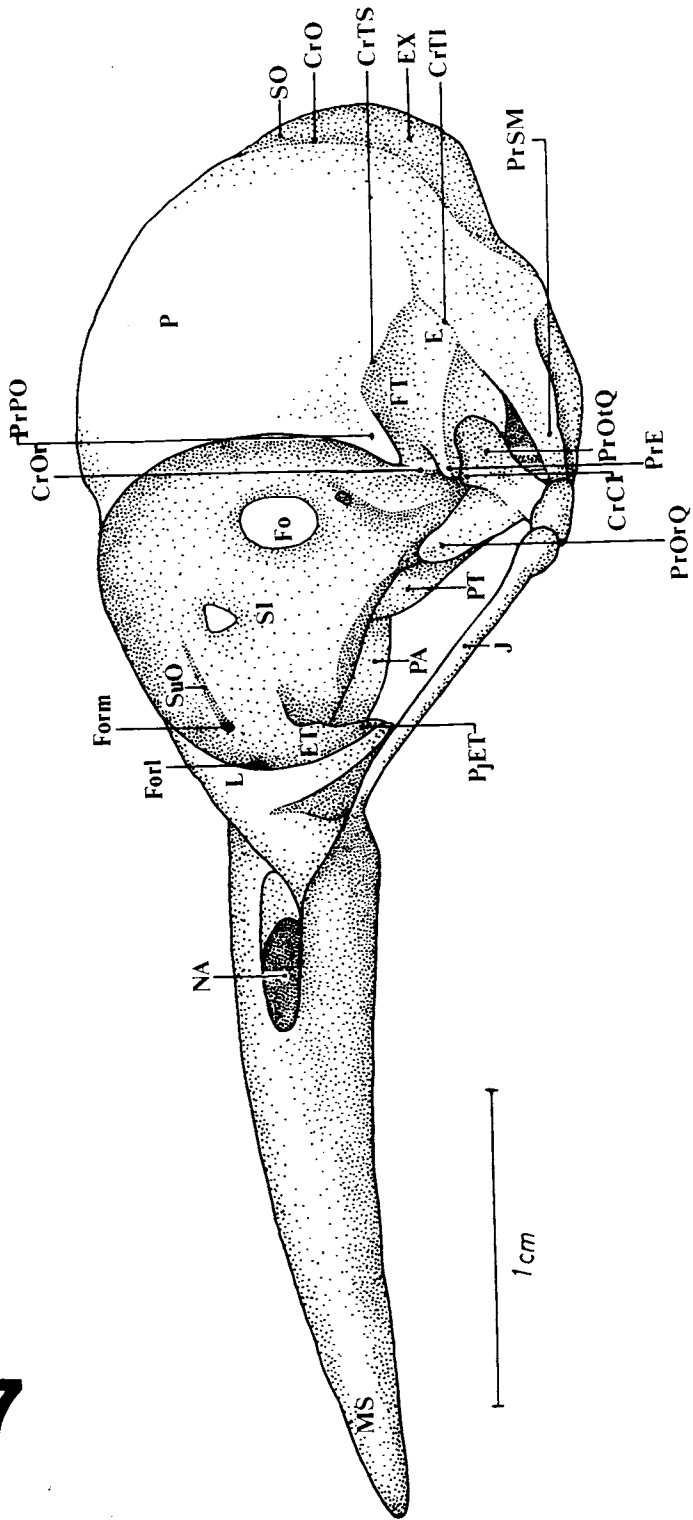
13



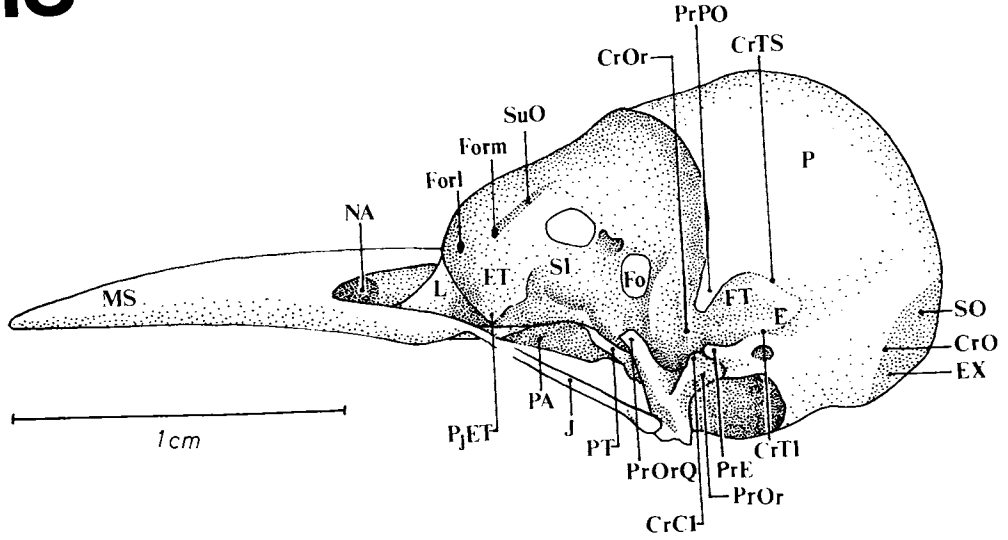




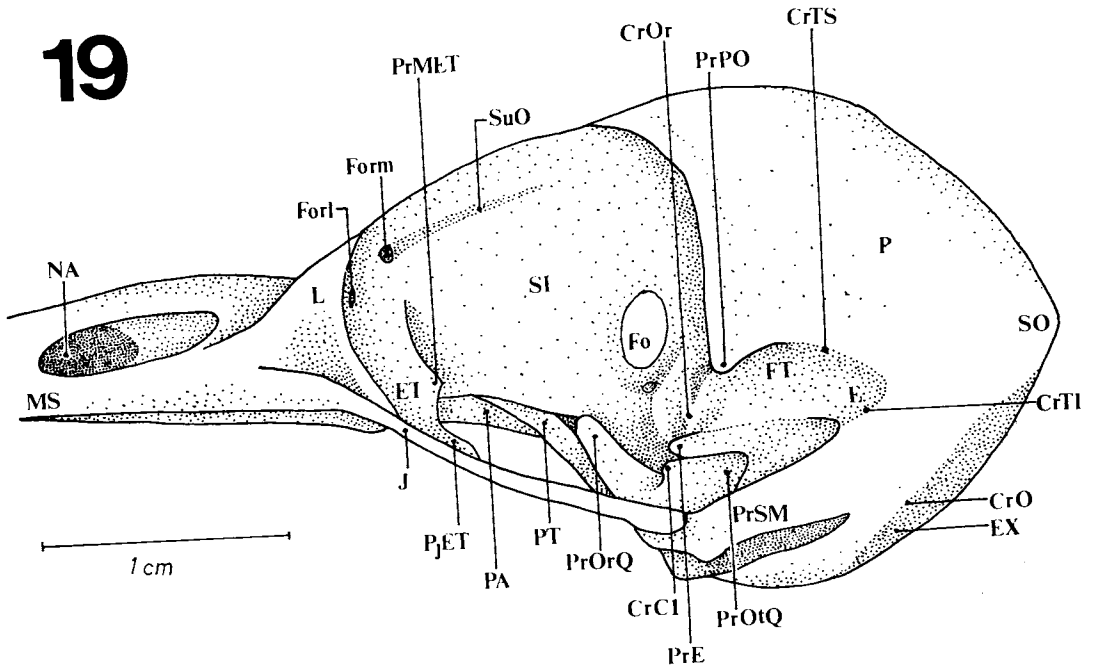
17



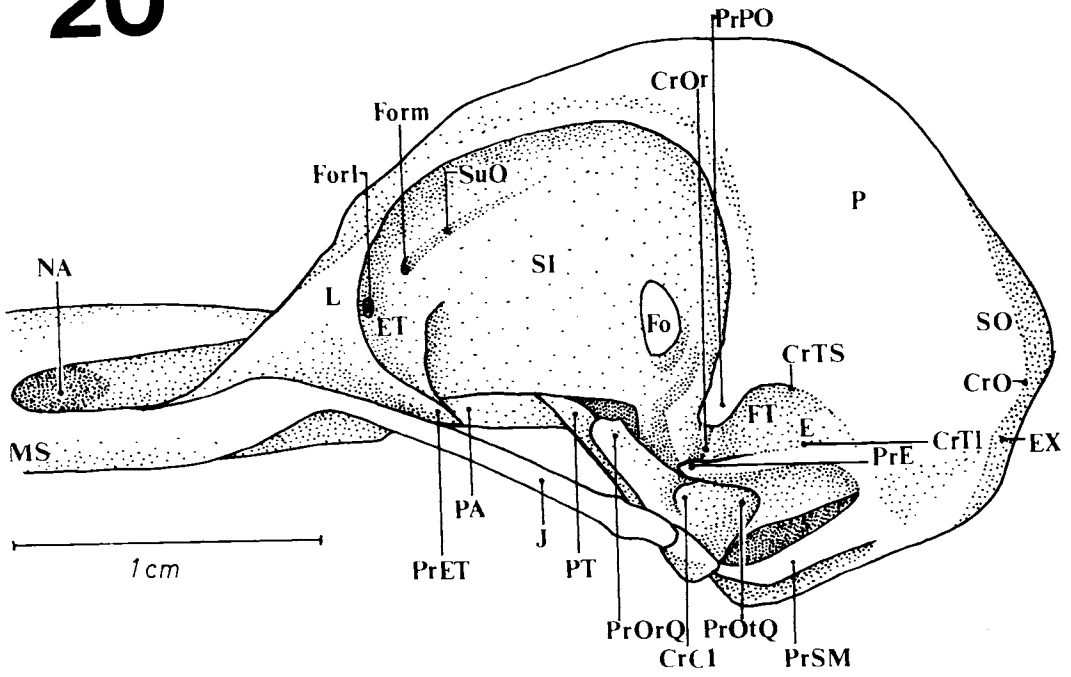
18



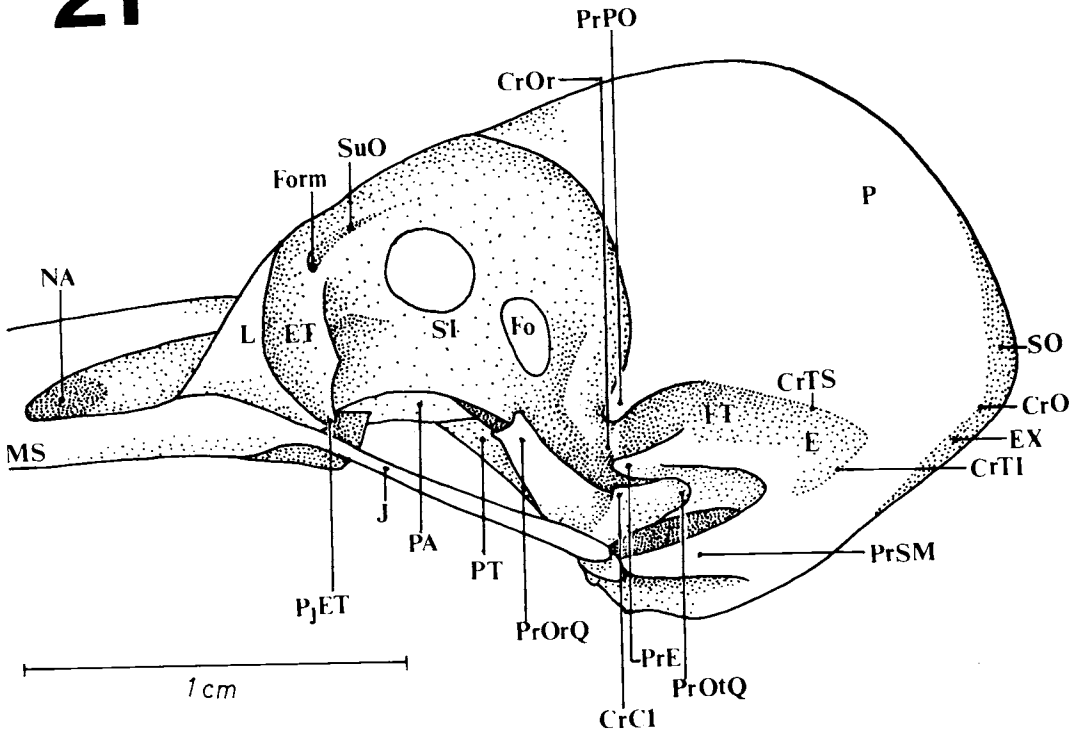
19



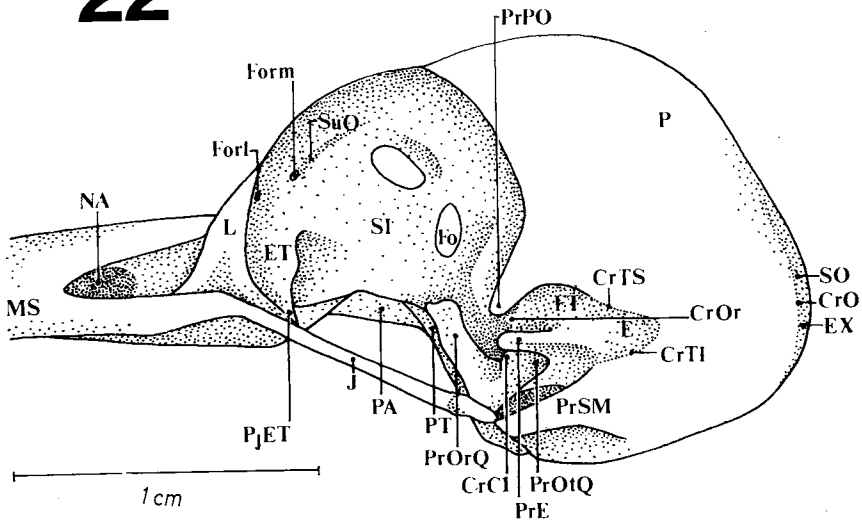
20



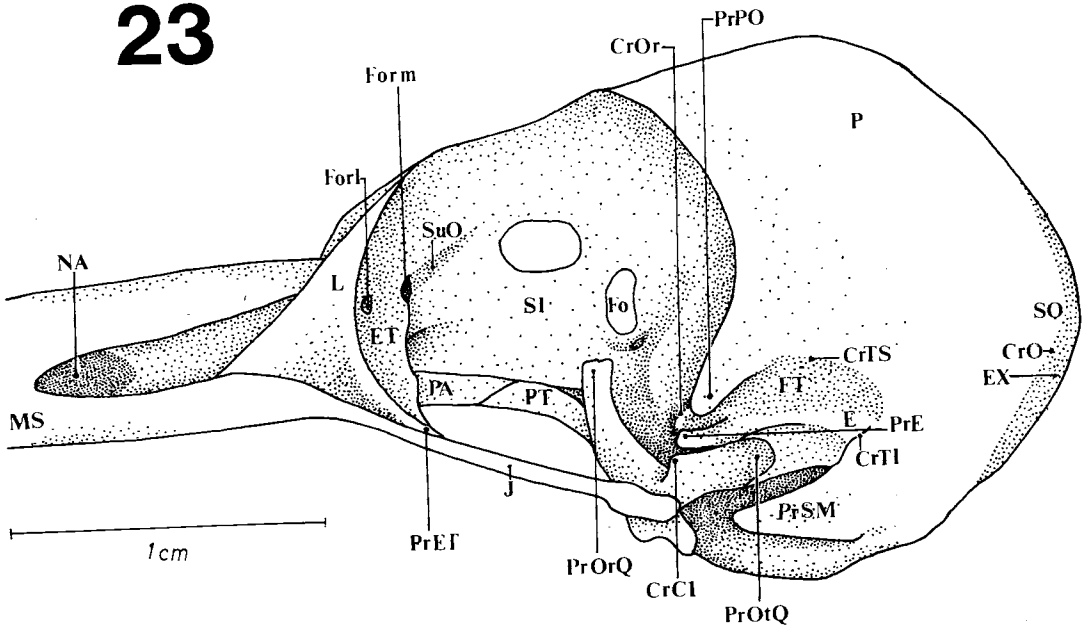
21



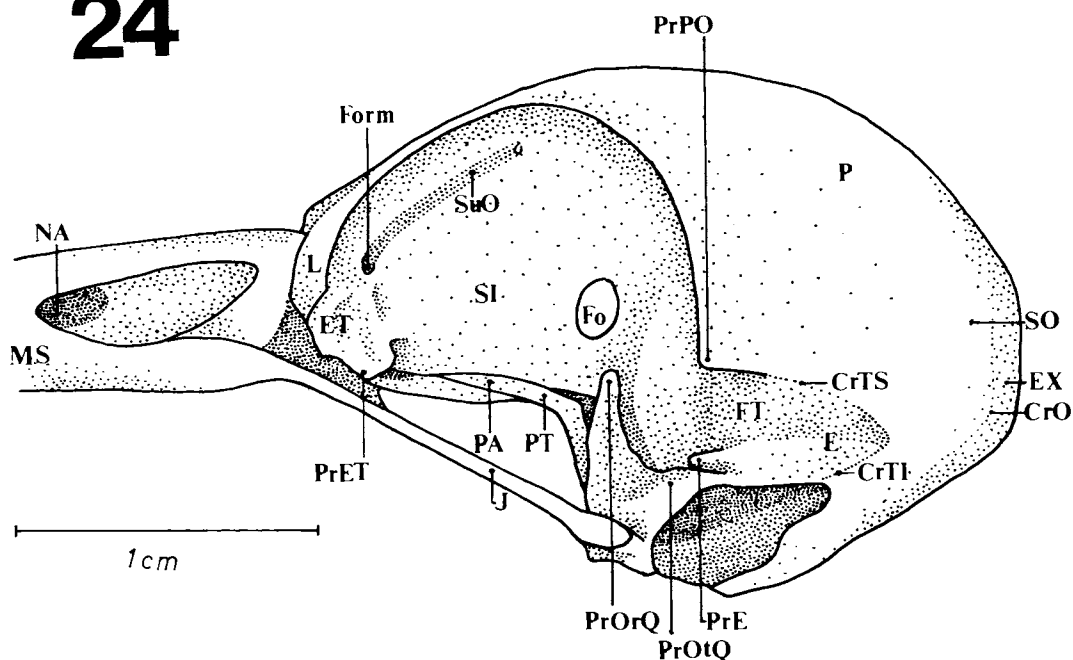
22



23



24



Figures 13-24: Lateral view of the skull. (13) *Campephilus rubricollis*, (14) *Piculus flavigula*, (15) *Celeus flavescens*, (16) *Melanerpes cruentatus*, (17) *Colaptes melanochloros*, (18) *Picumnus cirratus*, (19) *Geocolaptes olivaceus*, (20) *Campethera abingoni*, (21) *Mesopicus griseocephalus*, (22) *Dendropicus fuscescens*, (23) *Thripias namaquus*, (24) *Jynx ruficollis*.

CrC1 - C1 crest; CrO - occipital crest; CrOr - orbitosphenoid crest; CrTI - inferior temporal crest; CrTS - superior temporal crest; E - squamosal region; ET - ectethmoid bone; EX - exoccipital region; Fo - optical foramen; Forl - lateral orbitonasal foramen; Form - medial orbitonasal foramen; FT - temporal fossa; J - jugal bar; L - lacrimal foramen; MS - upper jaw; NA - nostril; P - parietal region; PA - palatine bone; PjET - ectethmoid projection; PrE - squamosal process; PjMET - medial projection of the ectethmoid bone; PrOrQ - orbital process of the quadrate; PrOtQ - optical process of the quadrate; PrPO - postorbital process; PrSM - supraorbital process; PT - pterygoid bone; SI - interorbital septum; SO - supraoccipital region; SuO - olfactory sulcus.

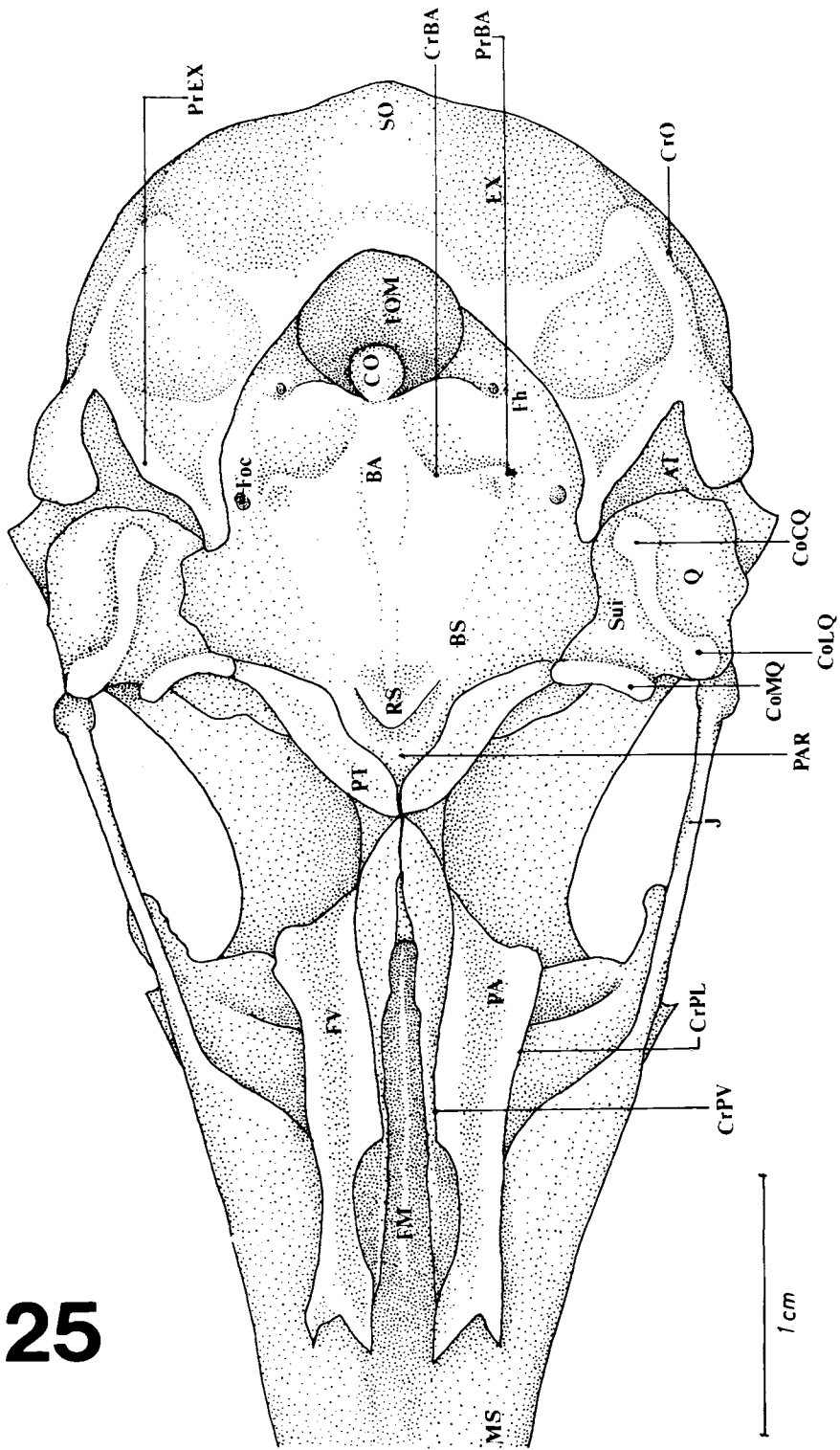
region (ET - Figs. 13-24); it extends to the dorsal surface of the jugal bar but there is no fusion. However, *P. cirratus* (Fig. 18) and *J. ruficollis* (Fig. 24) do not have this projection. On the other hand, in *P. flavigula* (Figs. 14 and 26) it is very well-developed and extends caudally to form "wings" over the dorsal surface of the jugal bar. In *G. olivaceus* (Fig. 19) a sharp, small medial projection (PjMET) is seen coming from the ectethmoid region.

The quadrate bone (Q - Figs. 25-36) has the *corpus quadrati* associated with three processes: optic, orbital and mandibular. The first (PrOtQ - Figs. 13-24) articulates dorsally with the squamosal region at the ventral surface of the squamosal process. In its rostralateral portion it is possible to notice the C1 crest (CrC1 - Figs. 14-23 and 50) where *M. adductor mandibulae externus caudalis lateralis* originates. This crest is con-

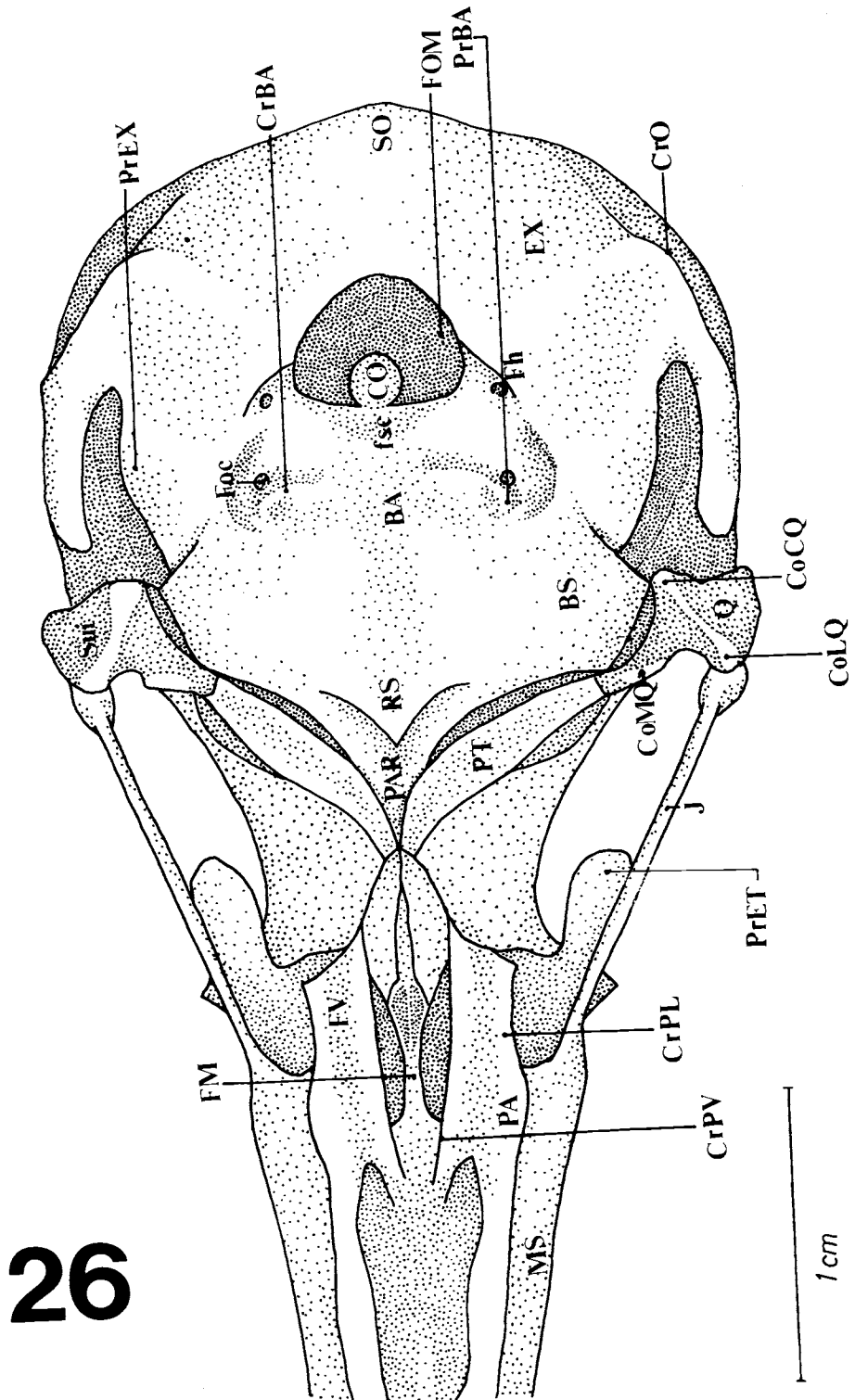
spicuous in a large part of the species of woodpeckers studied except *P. cirratus*, in which it is not well-developed and in *J. ruficollis*, in which the C1 crest was not observed.

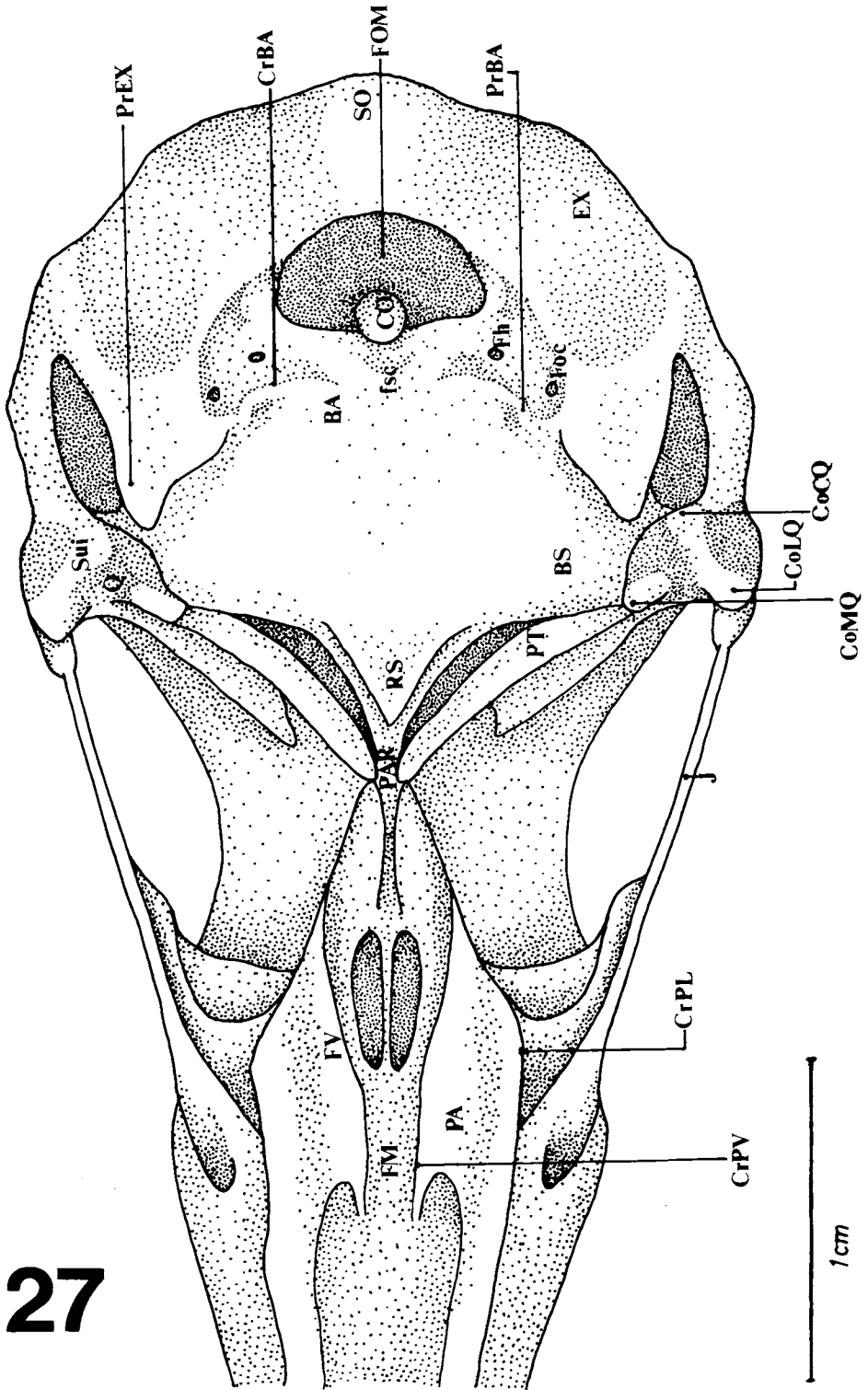
The orbital process (PrOrQ - Figs. 13-24) is disposed rostromedially from the *corpus quadrati*. Its form varies considerably among these woodpeckers but it is generally thin and extends about 2/3 the length of the pterygoid bone. In *J. ruficollis* (Fig. 24) it is turned upwards into the orbit.

The mandibular process articulates with the dorsocaudal region of the mandible and has three condyles: lateral (CoLQ - Figs. 25-36), caudal (CoCQ - Figs. 25-36) and medial (CoM - Figs. 25-36). The last is the most developed, except in *J. ruficollis* and *P. cirratus*; the caudal condyle is an extension of the lateral condyle. The intercotylar sulcus (Sui - Figs. 25-36) can be seen in these three



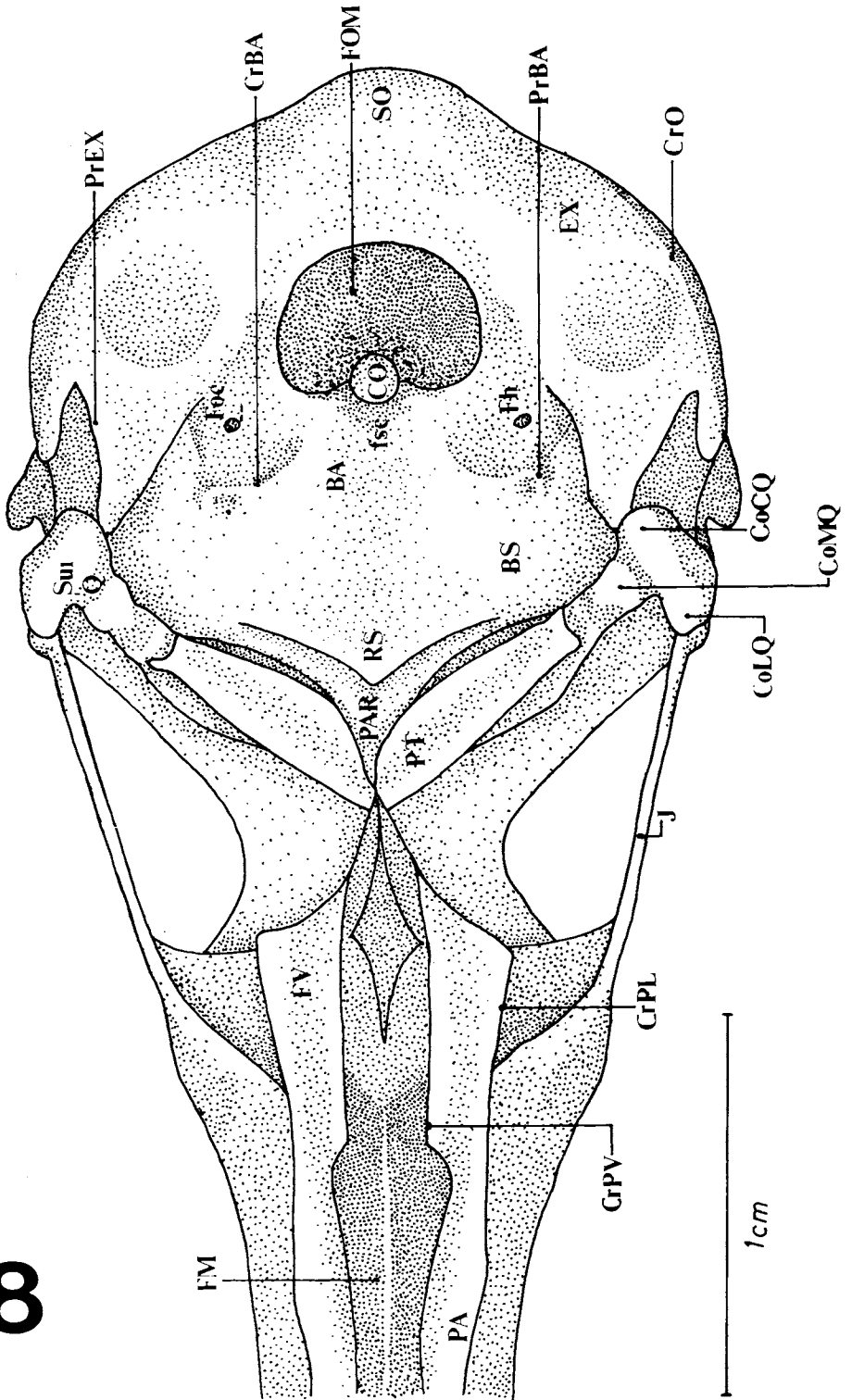
25



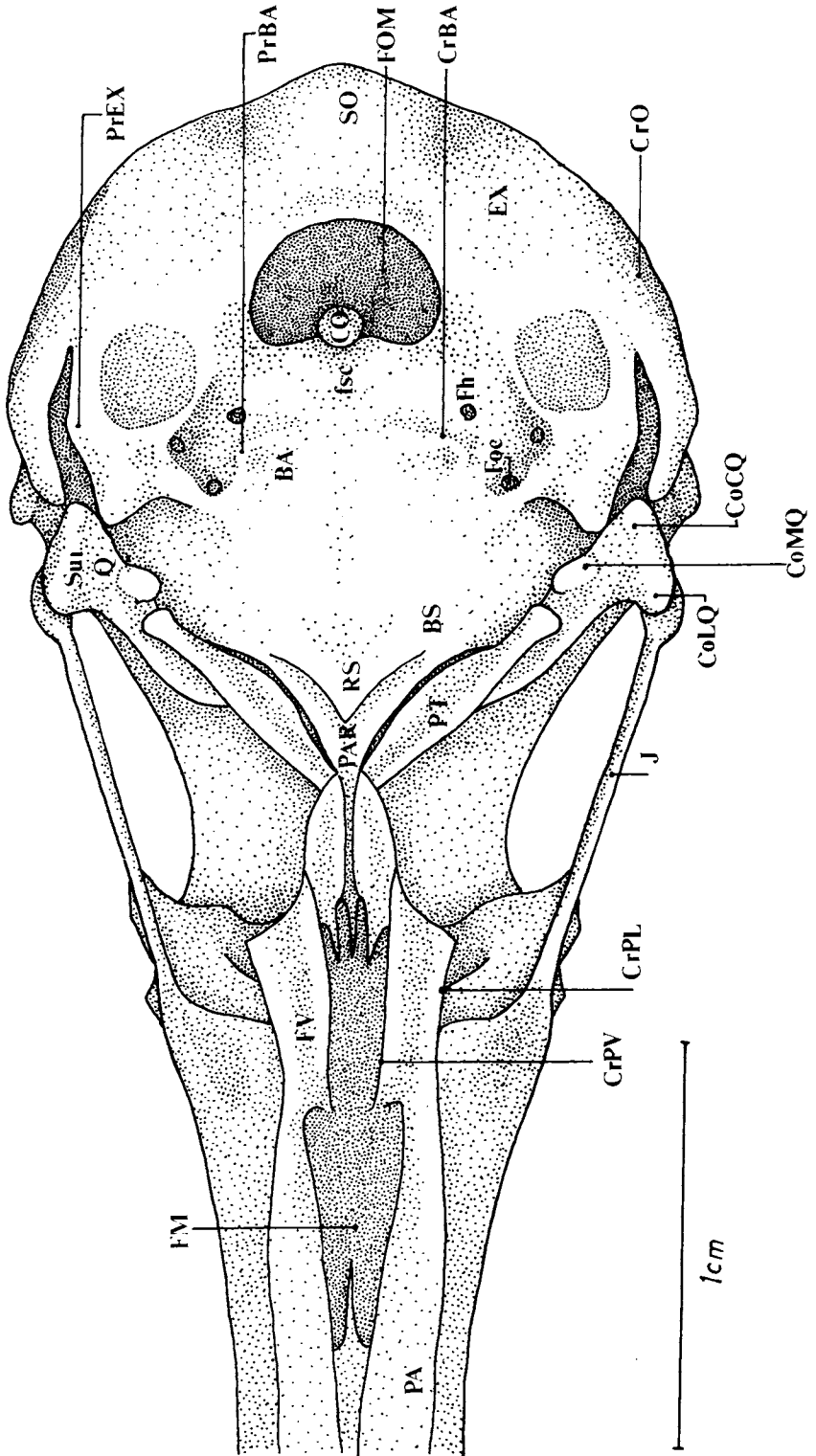


27

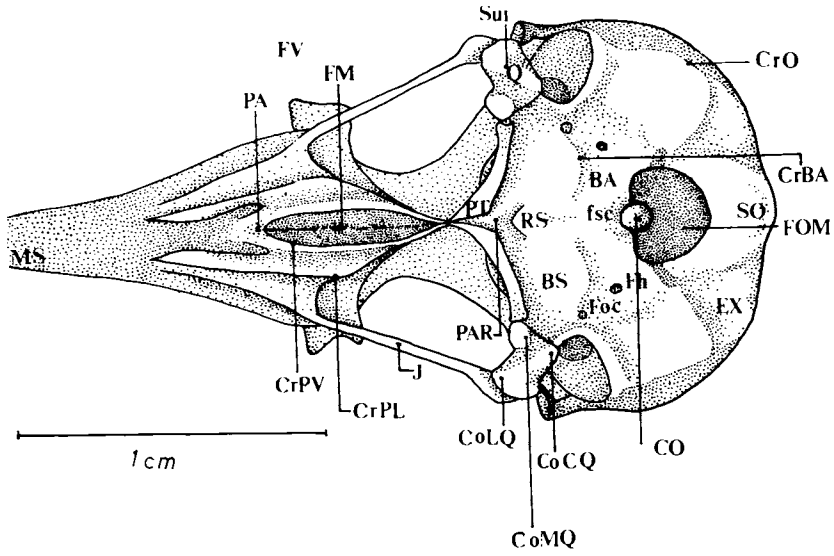
28



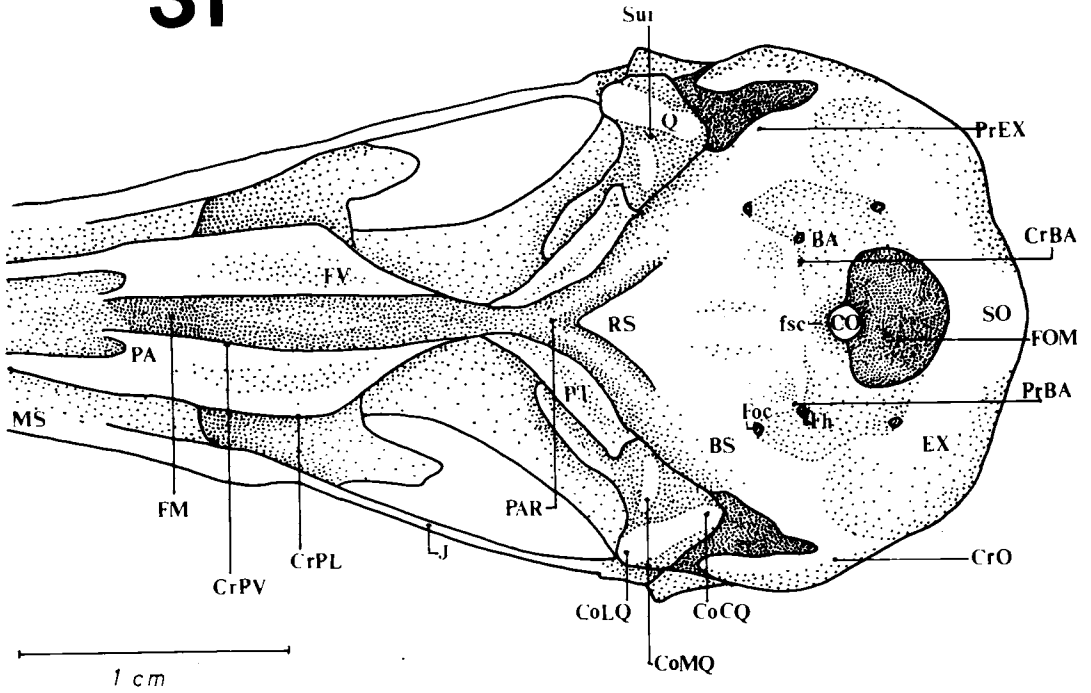
29



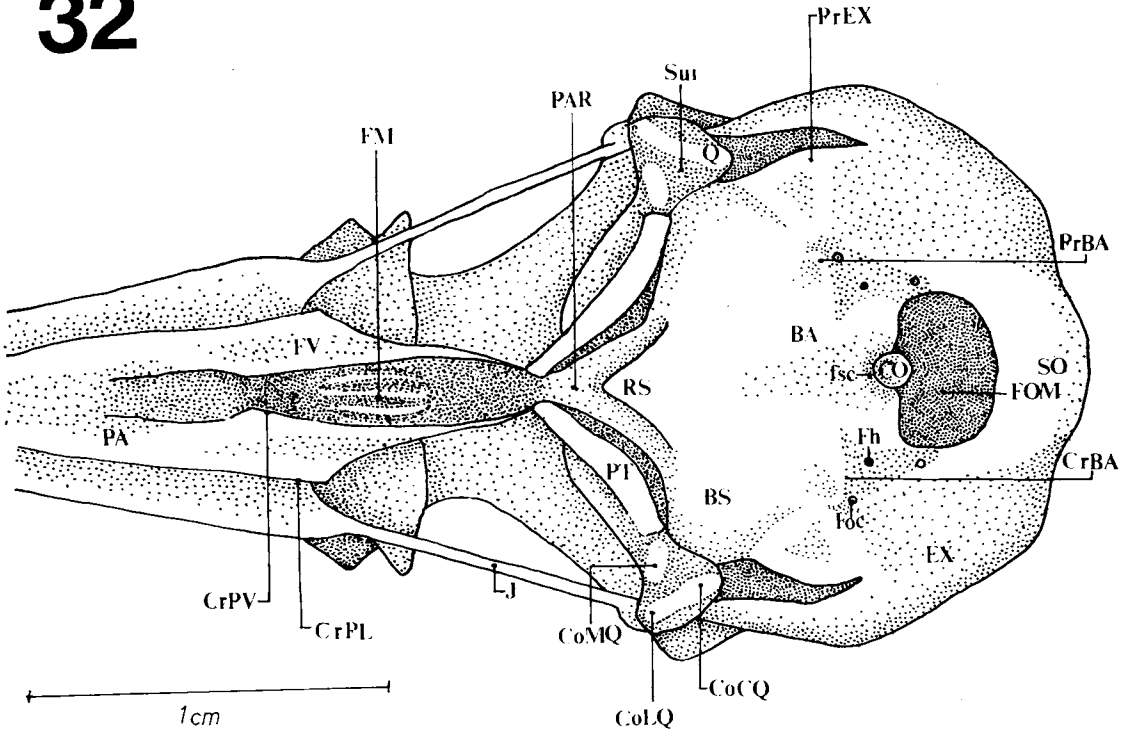
30



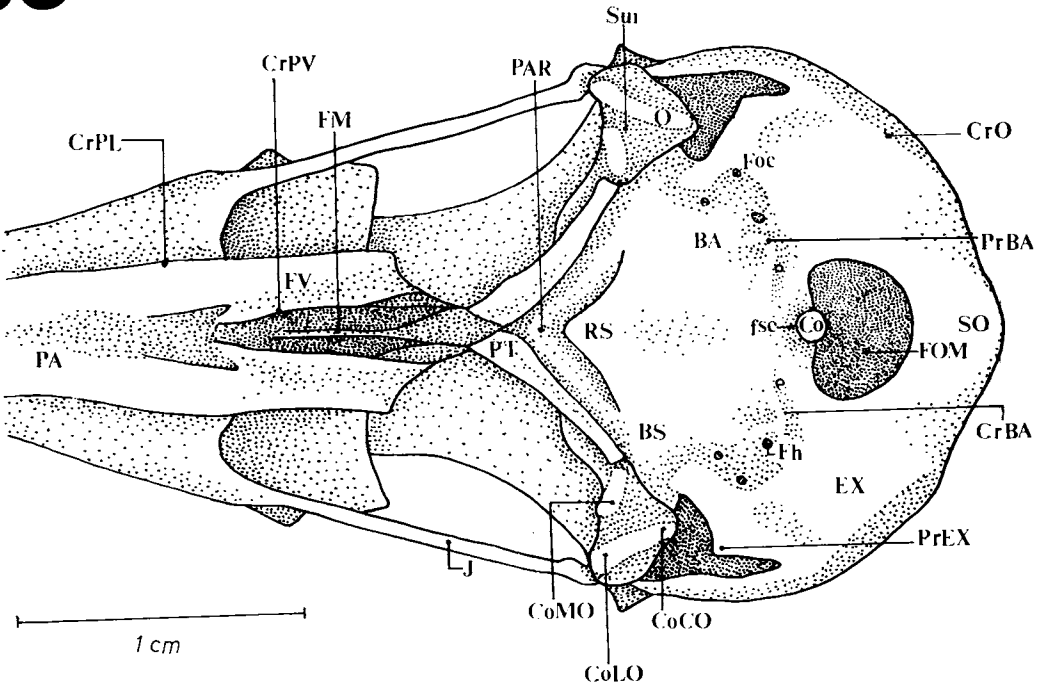
31



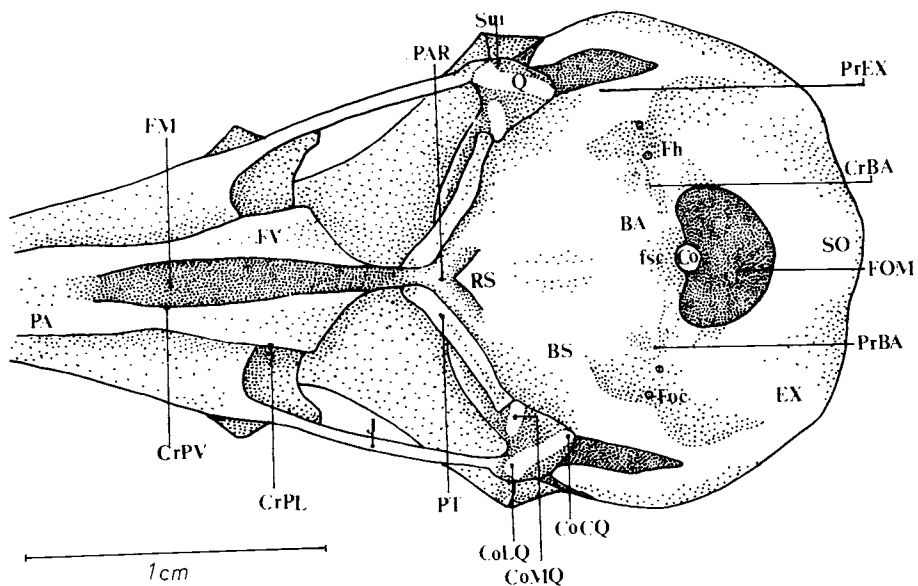
32



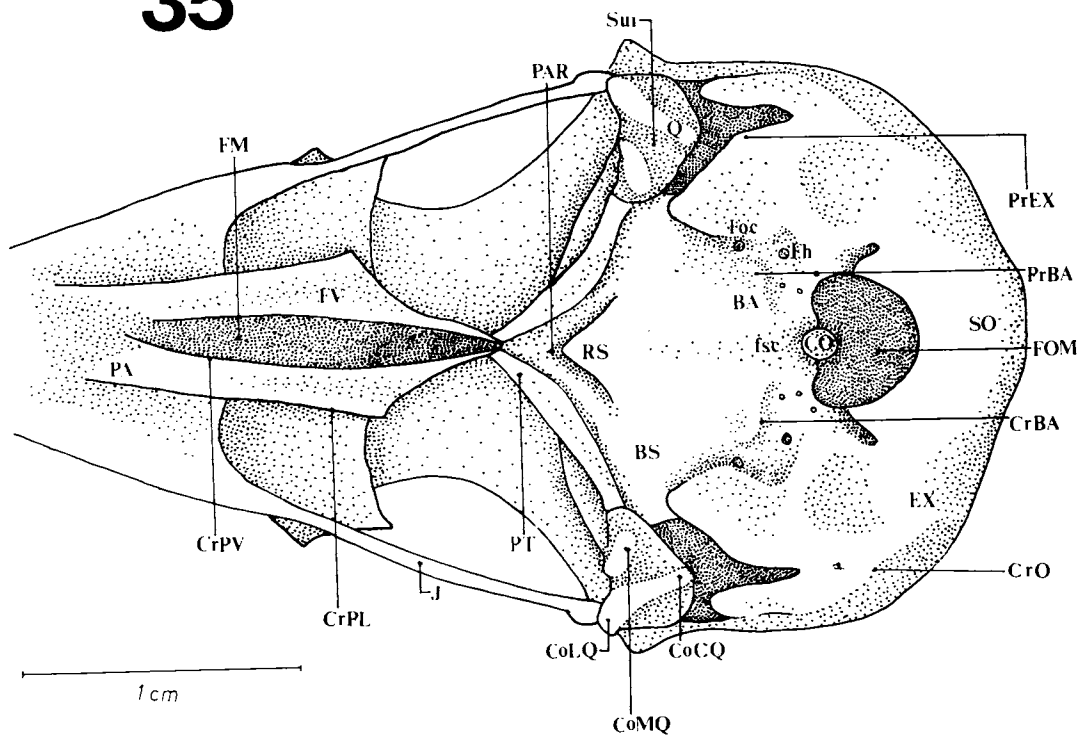
33



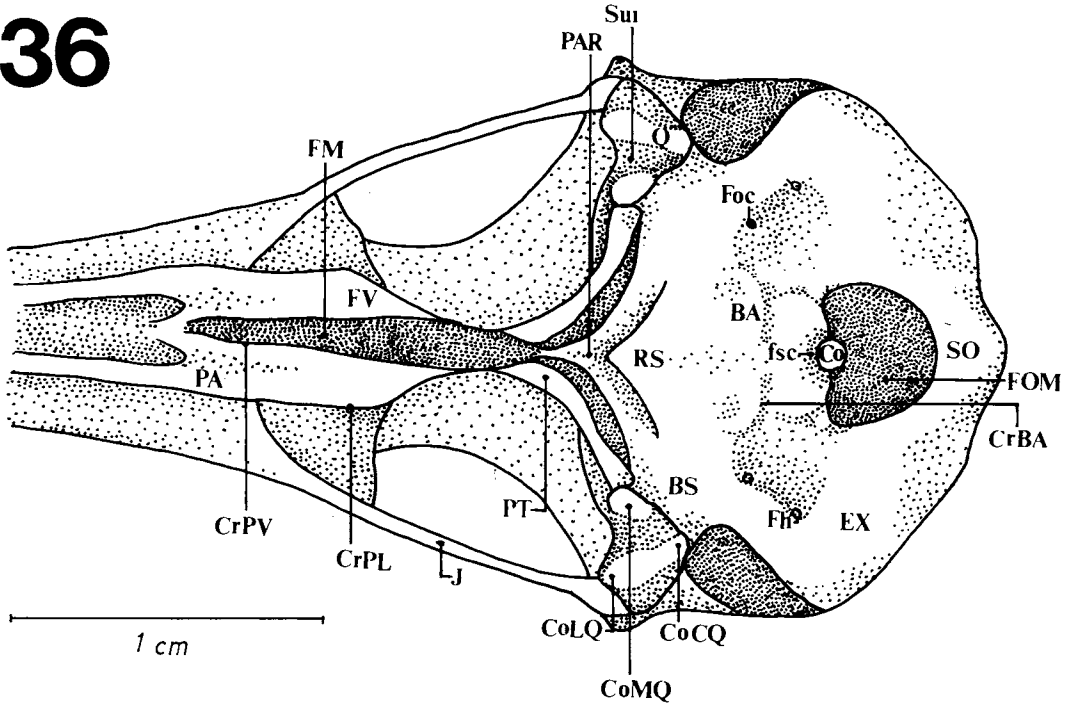
34



35



36



Figures 25-36: Ventral view of the skull. (25) *Campephilus rubricollis*, (26) *Piculus flavigula*, (27) *Celeus flavescens*, (28) *Melanerpes cruentatus*, (29) *Colaptes melanochloros*, (30) *Picumnus cirratus*, (31) *Geocolaptes olivaceus*, (32) *Campethera abingoni*, (33) *Mesopicus griseocephalus*, (34) *Dendropicus fuscescens*, (35) *Thripias namaquus*, (36) *Jynx ruficollis*.

BA - basioccipital region; BS - basisphenoid region; CO - occipital condyle; CoCQ - caudal condyle of the quadrate; CoLQ - lateral condyle of the quadrate; CoMQ - medial condyle of the quadrate; CrBA - basioccipital crest; CrO - occipital crest; CrPL - lateral palatine crest; CrPV - ventral palatine crest; EX - exoccipital region; FM - fossa medialis; Foc - internal carotid foramen; Fh - hypoglossum foramen; FOM - foramen magnum; fsc - subcondylar fossa; FV - ventral fossa; J - jugal bar; MS - upper jaw; PA - palatine bone; PAR - parasphenoid region; PjET - ectethmoid projection; PrBA - basioccipital process; PrEX - exoccipital process; PT - pterygoid bone; Q - quadrate; RS - sphenoid rostrum; SO - supraoccipital region; Sui - intercotylar sulcus.

condyles.

In general, the size of upper jaw (MS - Figs. 1-26; 30 and 31) about half the length of the size of skull, except in *C. rubricollis*, *G. olivaceus*, *M. griseocephalus* and *T. namaquus*, in which it extends about 60% of this length.

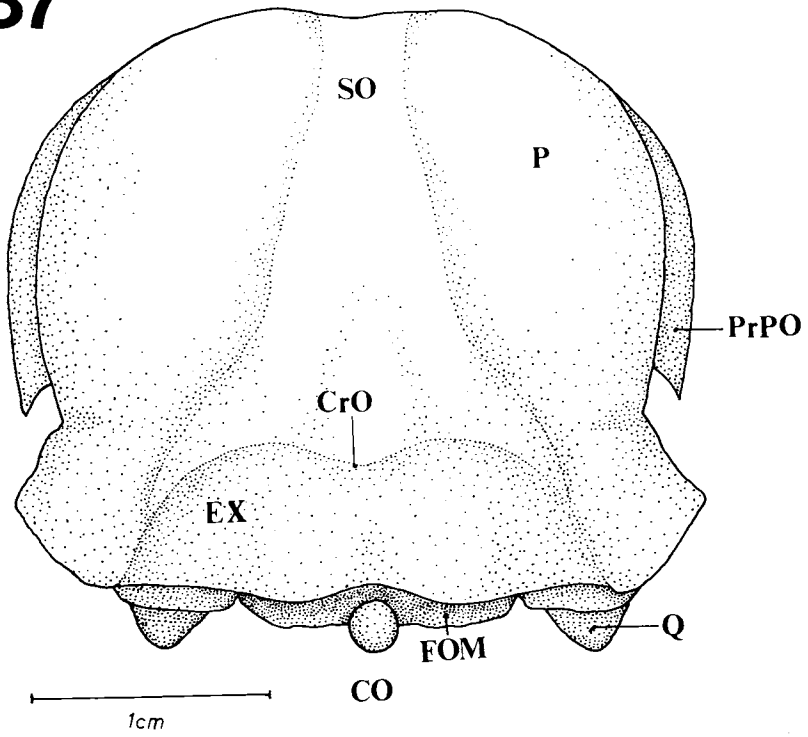
1.2. Mandible

The mandible may be divided into a symphyseal, an intermediate and a caudal part. The first has the mandibular symphysis. The intermediate part generally houses the *fenestra mandibulae rostralis*, while the caudal part is the main point of insertion of the jaw muscles which originate in the skull.

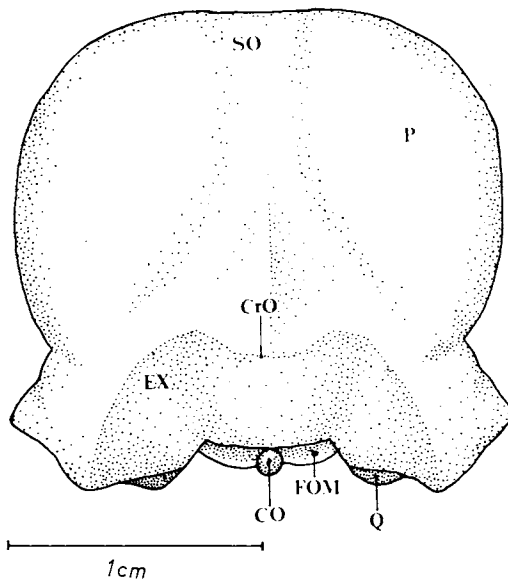
The symphyseal part (Psi - Figs. 51 and 57) is short - about 1/3 of the total length of the mandible - in most species. In *D. fuscescens*, *M. griseocephalus* and *P. cirratus* (Fig. 57) it is of about 40%, whereas in *C. rubricollis*, (Fig. 51) *M. cruentatus* and *T. namaquus* it is of about 50%.

In the dorsal region of the mandible, one may distinguish the pseudocoronoid 1 process (PrPC1 - Figs. 52 and 58) which is where the common tendon of the *muscles adductor mandibulae externus rostralis temporalis* and *adductor mandibulae externus rostralis medialis* inserts itself. It is conspicuous in all species except *P. cirratus*. The pseudocoronoid 2 process (PrPC2 - Fig. 52) lies laterocaudally in relation to the first.

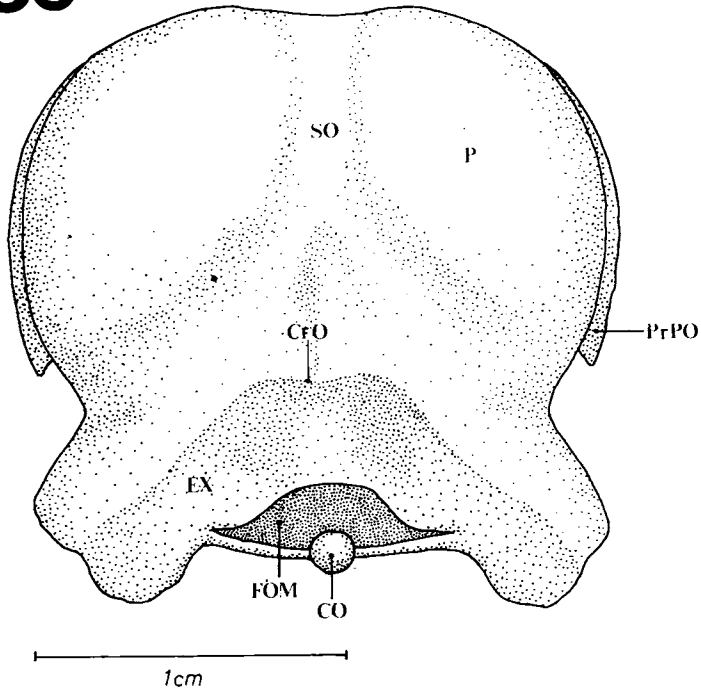
37



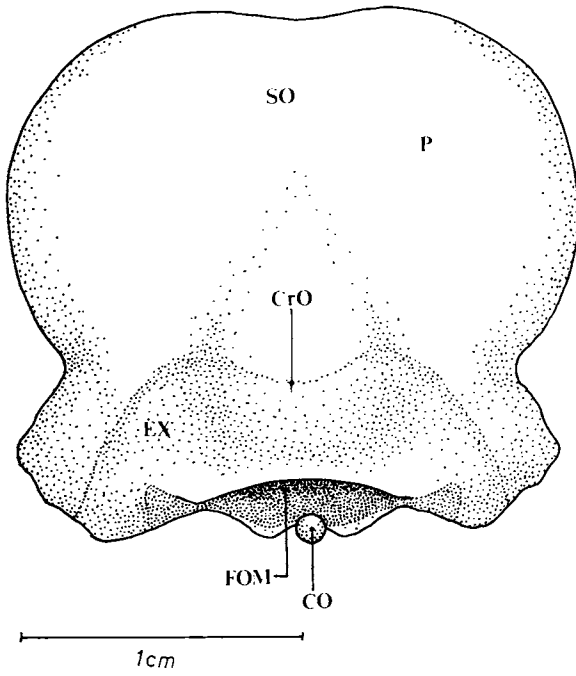
38



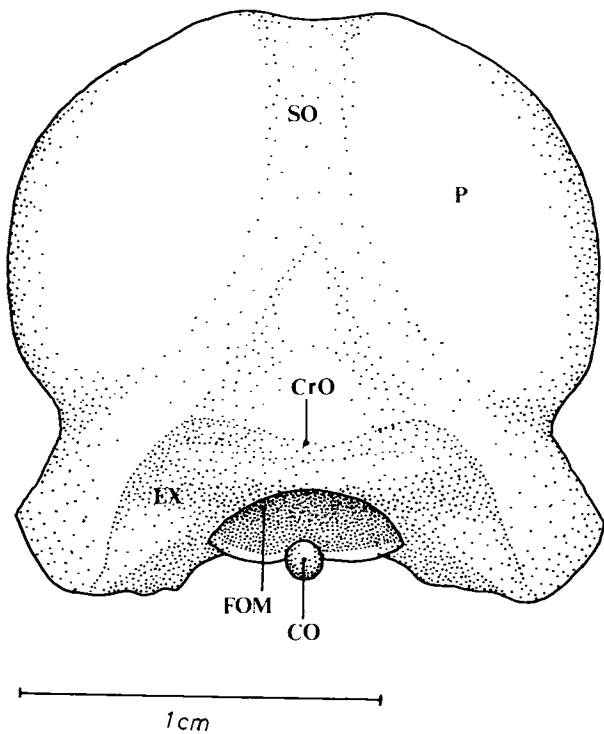
39



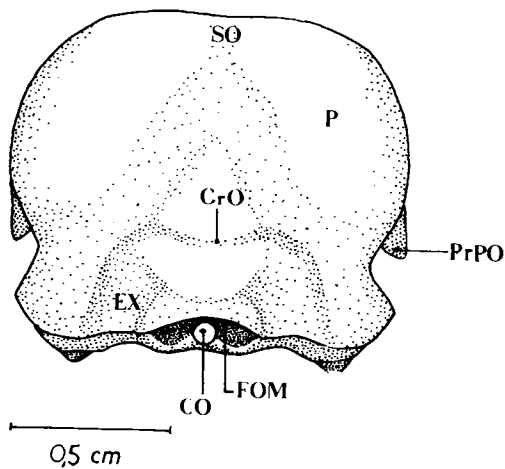
40



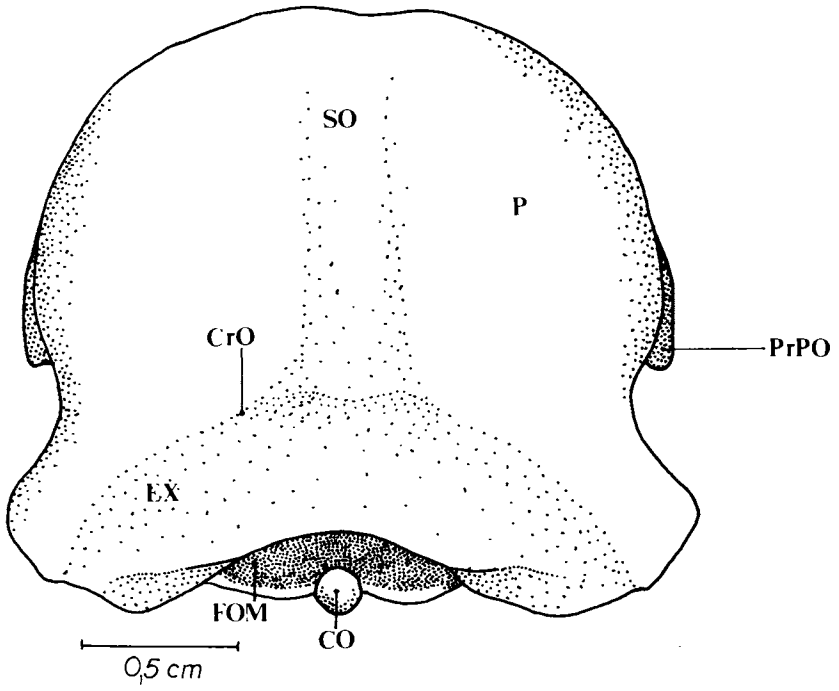
41



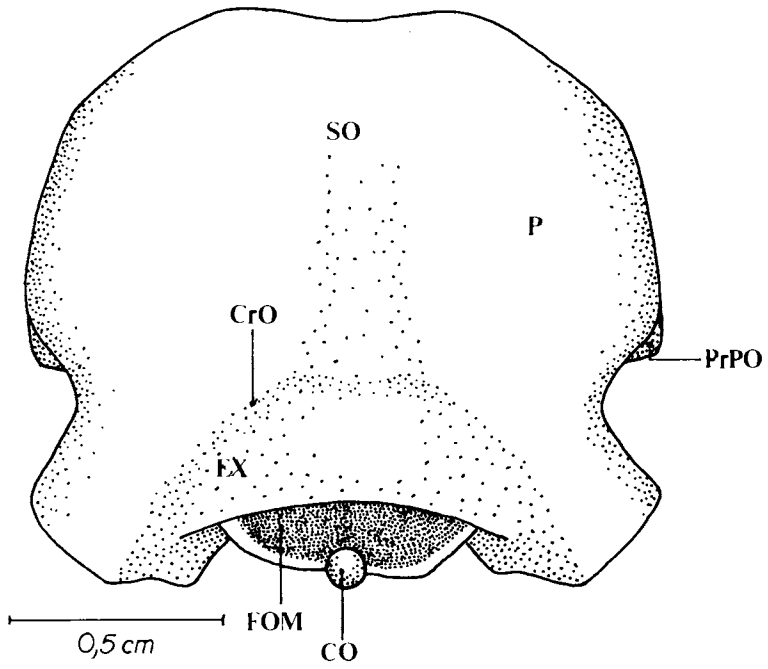
42



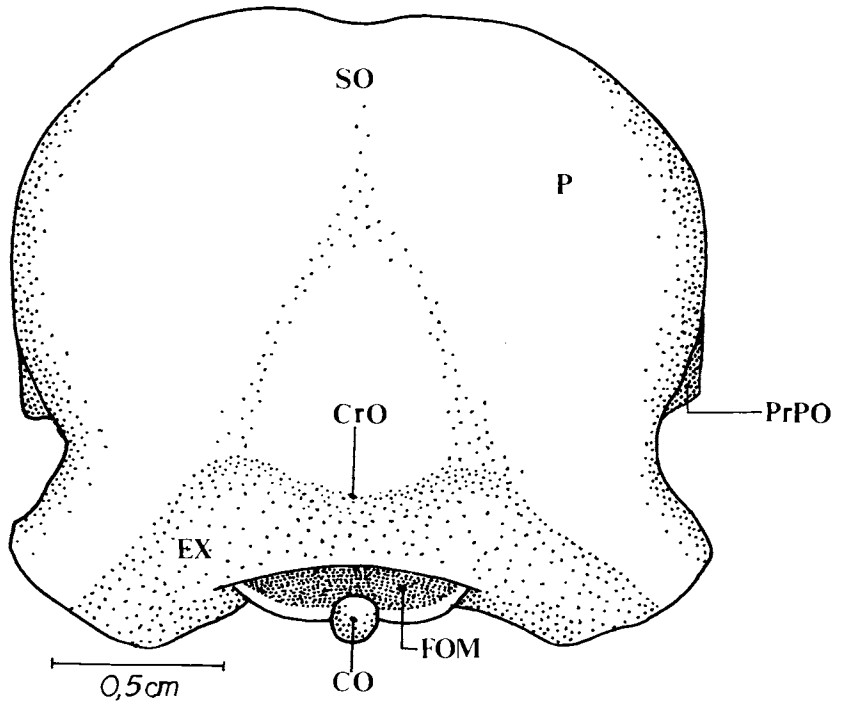
43



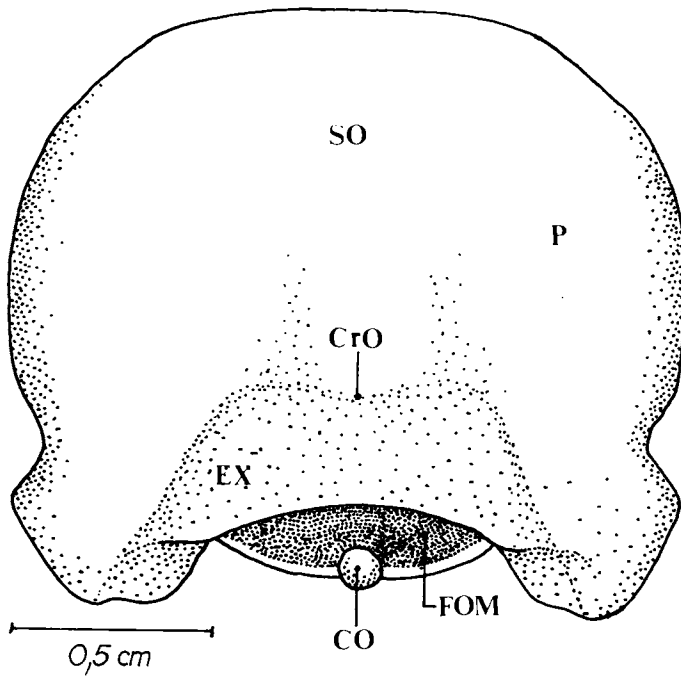
44



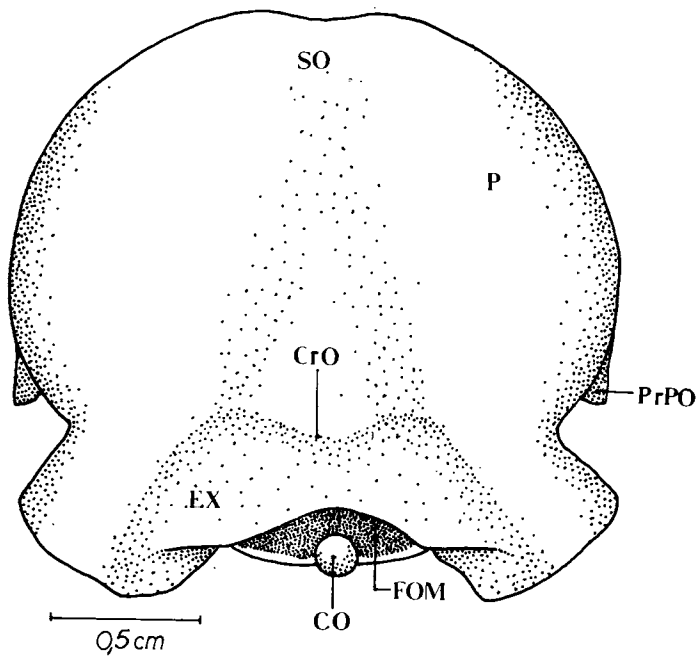
45



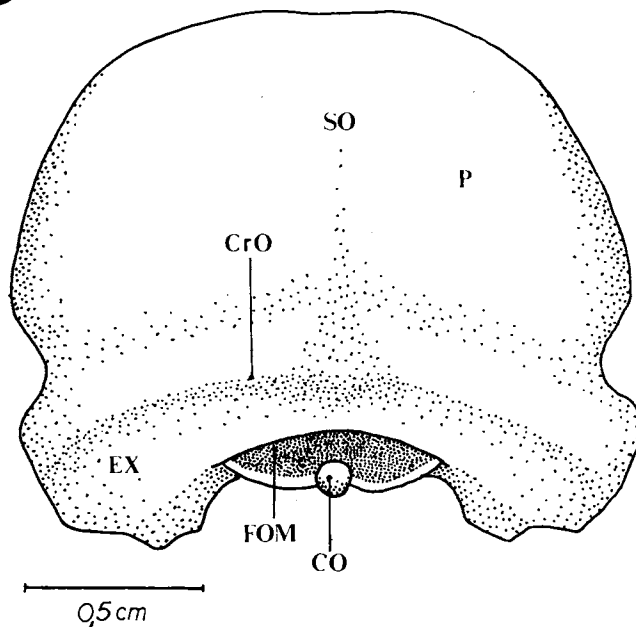
46



47



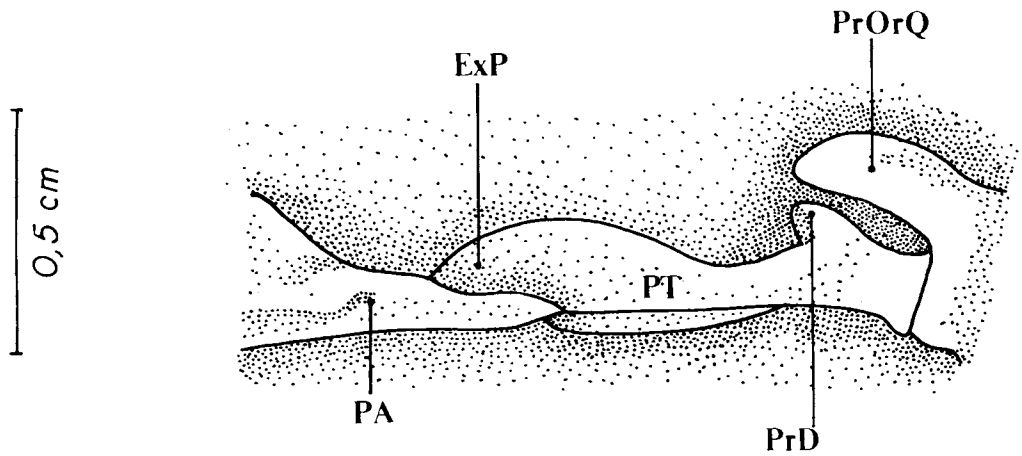
48



Figures 37-48: Posterior view of the skull. (37) *Campephilus rubricollis*, (38) *Piculus flavigula*, (39) *Celeus flavescens*, (40) *Melanerpes cruentatus*, (41) *Colaptes melanochloros*, (42) *Picumnus cirratus*, (43) *Geocolaptes olivaceus*, (44) *Campethera abingoni*, (45) *Mesopicus griseocephalus*, (46) *Dendropicus fuscescens*, (47) *Thripas namaquus*, (48) *Jynx ruficollis*.

CO - occipital condyle; CrO - occipital crest; EX - exoccipital region; FOM - Foramen magnum; P - parietal region; PrPO - postorbital process; Q - quadrate; SO - supraoccipital region.

49



50

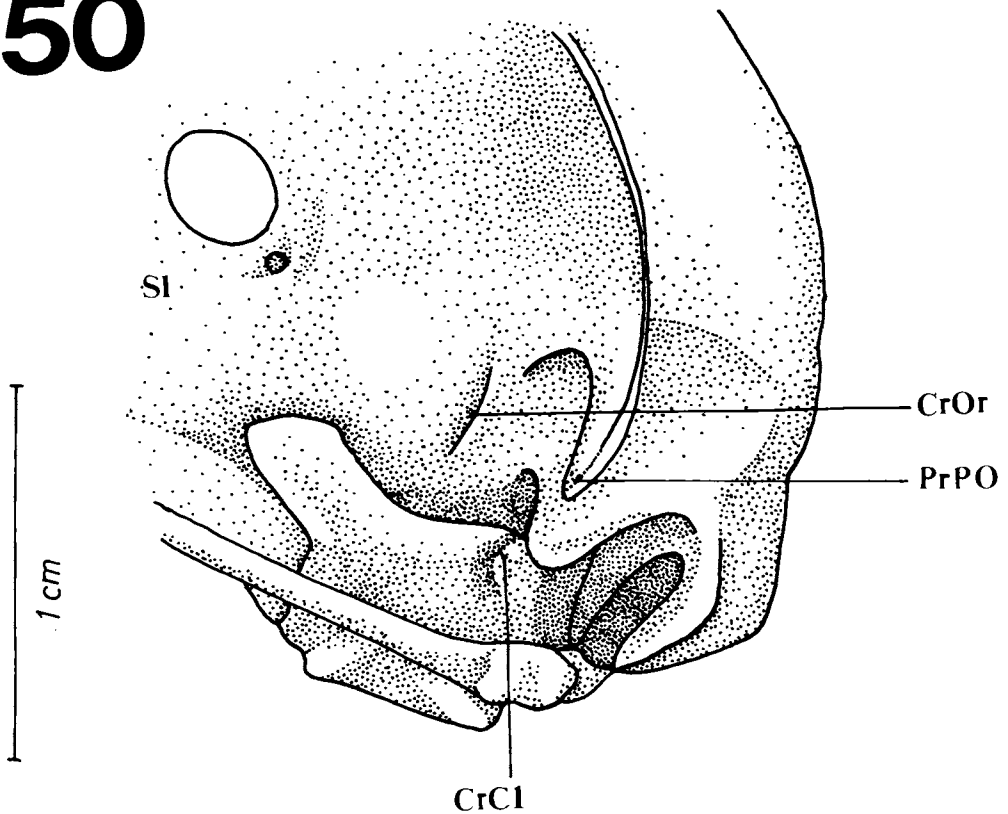


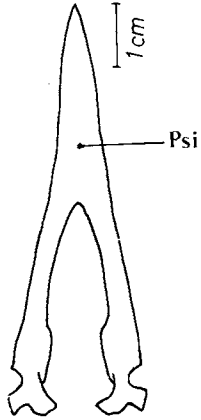
Figure 49. Ventrolateral view (detail) of the dorsal process and of the rostral expansion of the pterygoid represented in *Campephilus rubricollis*.

ExP - rostral expansion of the pterygoid; PA - palatine bone; PrD - dorsal process; PrOrQ - orbital process of the quadrate; PT - pterygoid.

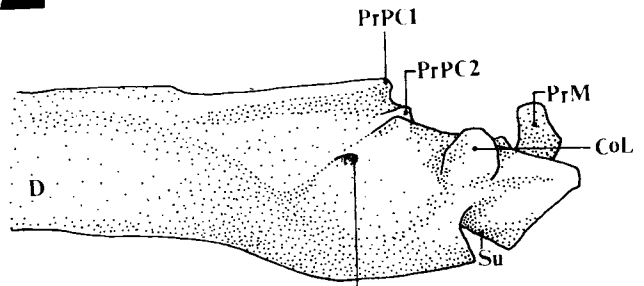
Figure 50. Rostrolateral view (detail) of the skull of *Campephilus rubricollis*.

CrCl - C1 crest; CrOr - orbitosphenoid crest; PrPO - postorbital process; SI - interorbital septum.

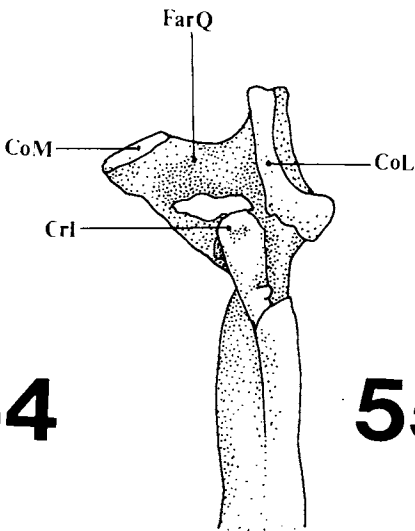
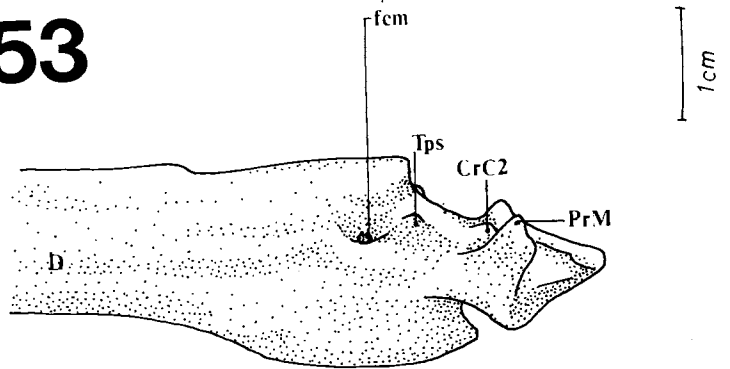
51



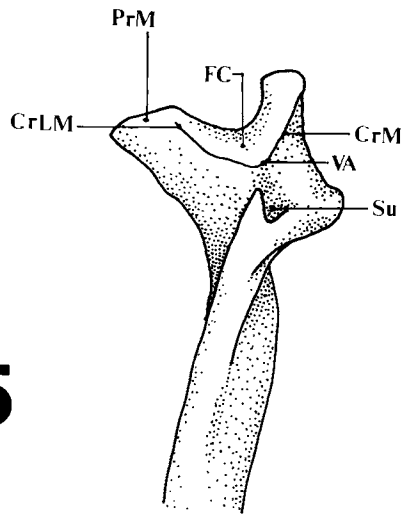
52



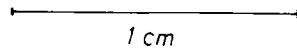
53

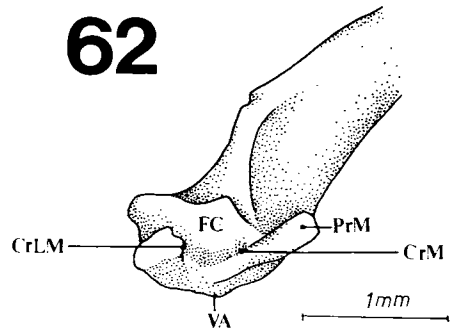
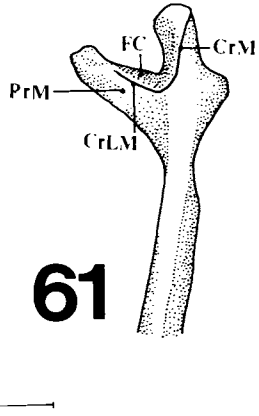
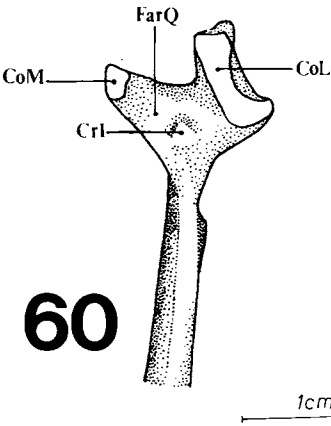
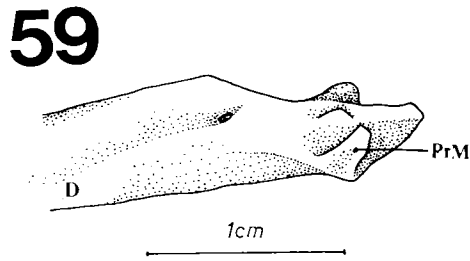
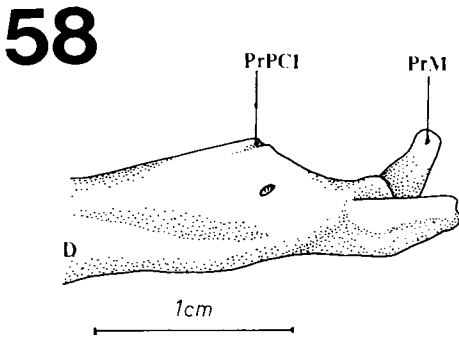
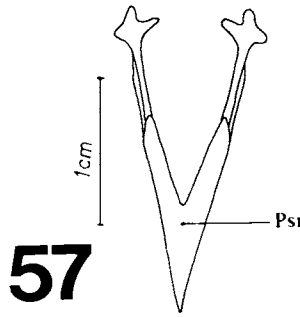
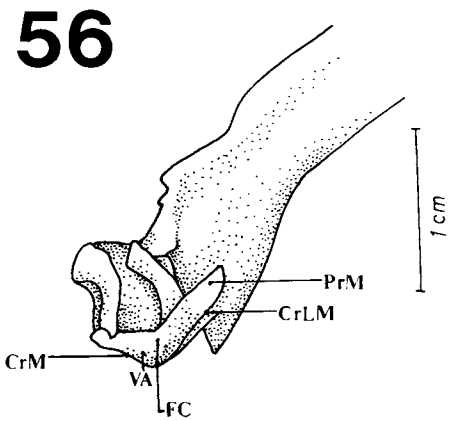


54



55





Figures 51-55: Mandible, *Campephilus rubricollis*. (51) General scheme in ventral view, (52) Lateral view, (53) Medial view, (54) Dorsal view, (55) Ventral view.

CrC2 - C2 crest; CoL - lateral condyle of the quadrate; CoM - medial cotyle; CrI - intercotylar crest; CrLM - lateral crest of the mandible; CrM - medial crest of the mandible; D - dental bone region; FarQ - fossa articularis quadratica; FC - caudal fossa; fcm - caudal fissure of the mandible; PrM - medial process of the mandible; PrPC1 - pseudocoronoid 1 process of the mandible; PrPC2 - pseudocoronoid 2 process of the mandible; Psi - symphyseal part of the mandible; Tps - pseudotemporal tubercle; Su - deep groove of the mandible; VA - angular vertex.

Figures 56-62: Mandible, *Picumnus cirratus*. (56) Posterior view, (57) General scheme in ventral view, (58) Lateral view, (59) Medial view, (60) Dorsal view, (61) Ventral view, (62) Posterior view.

CoL - lateral condyle of the quadrate; CoM - medial cotyle; CrI - intercotylar crest; CrLM - lateral crest of the mandible; CrM - medial crest of the mandible; D - dental bone region; FarQ - fossa articularis quadratica; FC - caudal fossa; PrM - medial process of the mandible; PrPC1 - pseudocoronoid 1 process of the mandible; Psi - symphyseal part of the mandible; Su - deep groove of the mandible; VA - angular vertex.

It is where the aponeurosis of *M. adductor mandibulae externus ventralis* inserts itself. This process is also well-developed in all species, except *P. cirratus*. *Fossa articularis quadratica* (FarQ - Figs. 54 and 60) lies dorsocaudally in relation to this process, between the lateral (CoL - Figs. 52, 54 and 60) and medial *cotylae* (CoM - Figs. 54 and 60).

In the intermediate part of the lateral surface of the mandible, a small depression is observed; this region is distinguished from the caudal part by a sulcus and a caudal *fenestra* of the mandible. This sulcus meets the pseudocoronoid 2 process dorsally. Neither the sulcus nor the pseudocoronoid 2 process are conspicuous in *P. cirratus*. Only in *C. rubricollis* is it a deep groove in the angular region (Su - Figs. 52 and 55).

The medial process of the mandible (PrM - Figs. 52, 53, 55, 56; 58, 59; 61 and 62) is projected dorsomedially from the medial surface of the mandible. The C2 crest lies rostromedially in relation to the medial process. The pseudotemporal tubercle (Tps - Fig. 53), where the aponeurosis of the *M. pseudotemporalis superficialis* inserts itself, may vary among these woodpeckers but it is usually conspicuous. The caudal fossa (FC - Figs. 56 and 62) is represented by a shallow ventrocaudal depression. The lateral (CrLM - Figs. 56 and 62) and the medial crests (CrM - Figs. 56 and 62) form the angular vertex (VA - Figs. 56 and 62) of the mandible.

2. Musculature (Figs. 63-85).

2.1. External adductor mandibular system. This muscle system can be divided into three distinct parts: *rostralis*, *ventralis* and *caudalis*.

2.1.1. *M. adductor mandibulae externus rostralis*
M. adductor mandibulae externus rostralis is well-developed in the species of Picidae studied and may be divided in three parts: *temporalis*, *medialis* and *lateralis*.

2.1.1.1. *M. adductor mandibulae externus rostralis temporalis* (amert)

This part of *M. adductor mandibulae externus rostralis* lies between the medial and lateral portions of the same muscle. It originates as

fleshy fibers on the laterocaudal surface of the skull, on the temporal fossa. Basically, there are three arrangements: The dorsal fleshy fibers are disposed rostrally and they partially join those of the *M. adductor mandibulae externus rostralis medialis* to insert at the medial surface of a well-developed aponeurosis I; the ventral fleshy fibers insert at the lateral surface of the same aponeurosis; and the rostral fibers, ventrolaterally disposed in relation to the postorbital process, insert rostrally at the medial surface of aponeurosis I. This aponeurosis is bound in a common tendon to aponeurosis II and III (Fig. 75), on the dorsal surface of the mandible, in the pseudocoronoid 1 process.

Comparison: In relation to *C. rubricollis*, however, both muscles and aponeurosis I are less developed in most of the species examined, except *G. olivaceus* (Fig. 69).

2.1.1.2. *M. adductor mandibulae externus rostralis medialis* (amerm)

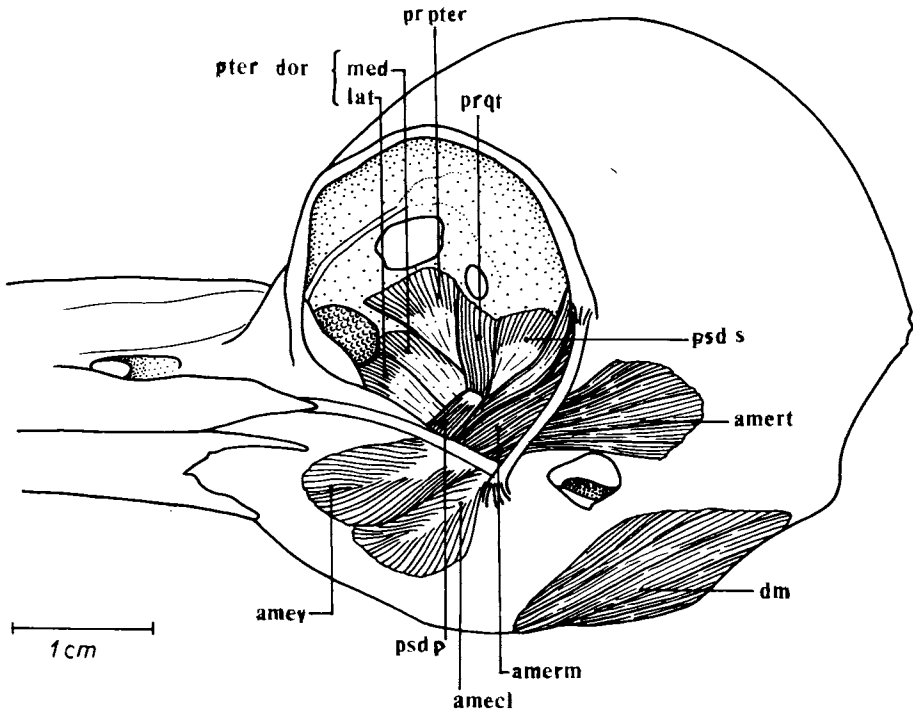
The *M. adductor mandibulae externus rostralis medialis* lies medially in relation to the other parts of the external adductor mandibular system and laterally in relation to the muscular fibers of the internal adductor mandibular system.

It originates partly as fleshy fibers on the dorsolateral portion of the orbitosphenoid and partly as aponeurosis 1, which originates at the medial surface of the postorbital process. The fleshy fibers which originate at the dorsolateral portion insert at the lateral surface of a thick aponeurosis II. The fleshy fibers associated with aponeurosis I originate at its medial surface and join the dorsal fleshy fibers of the *M. adductor mandibulae externus rostralis temporalis* to bind together on the medial surface of aponeurosis I.

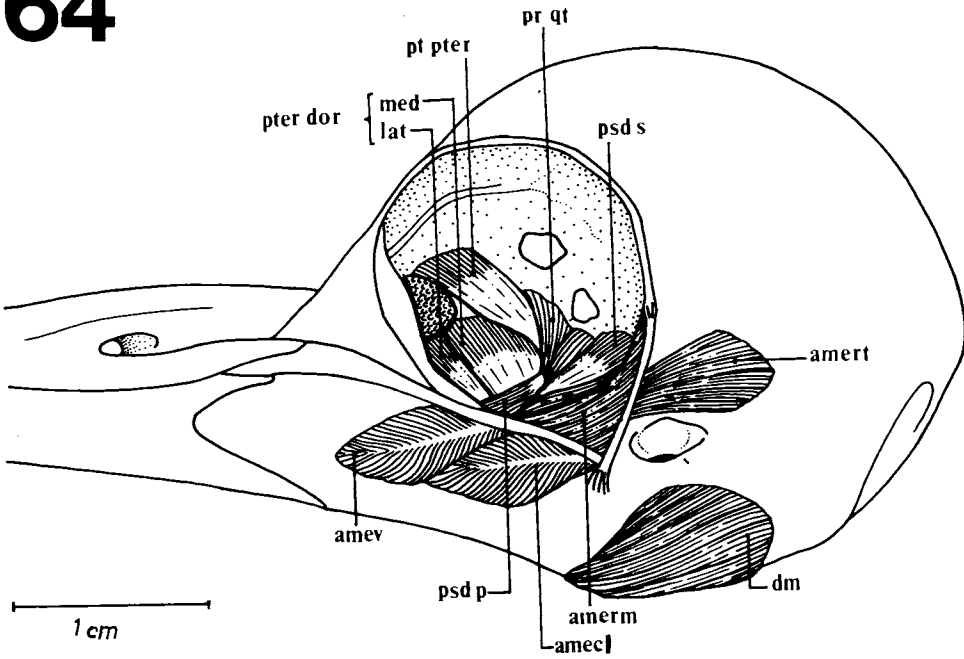
Ventrally to the fibers described above, other fleshy fibers originate at the lateral surface of aponeurosis 2 which originates on the orbitosphenoid crest. These fleshy fibers are oriented rostromedially and insert at the medial surface of aponeurosis III.

Comparison: In general, aponeurosis I is the most-widely spread and the strongest among woodpeckers. Except for *G. olivaceus* (Fig. 69), *D. fuscescens* (Fig. 72), *T. namaquus* (Fig. 73) and *J. ruficollis* (Fig. 74) which are similar to *C. rubricollis* (Fig. 63), the fleshy fibers and the as-

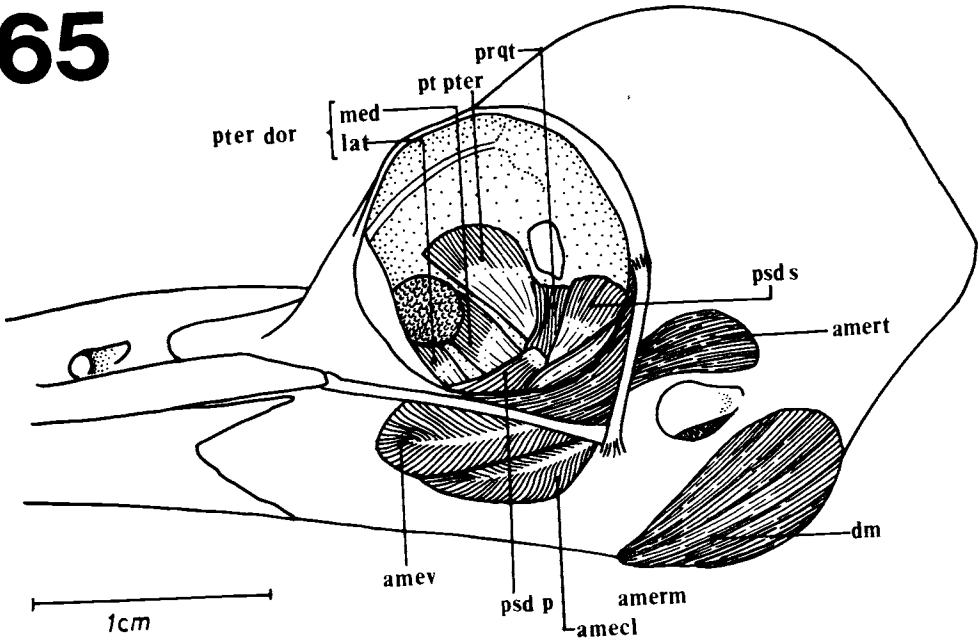
63



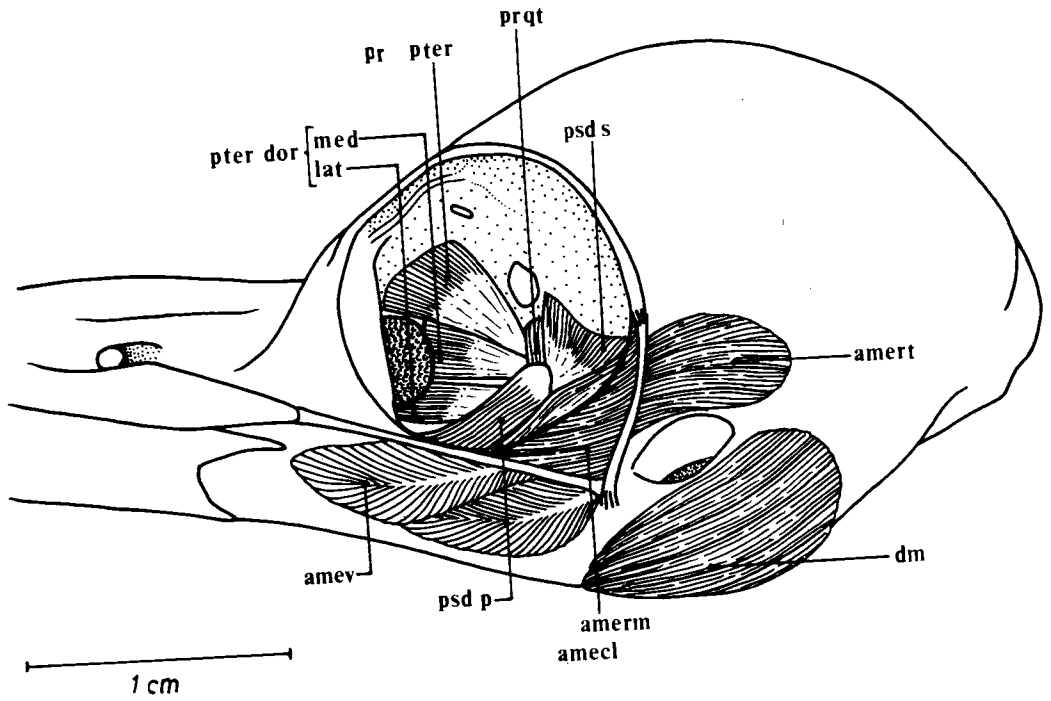
64



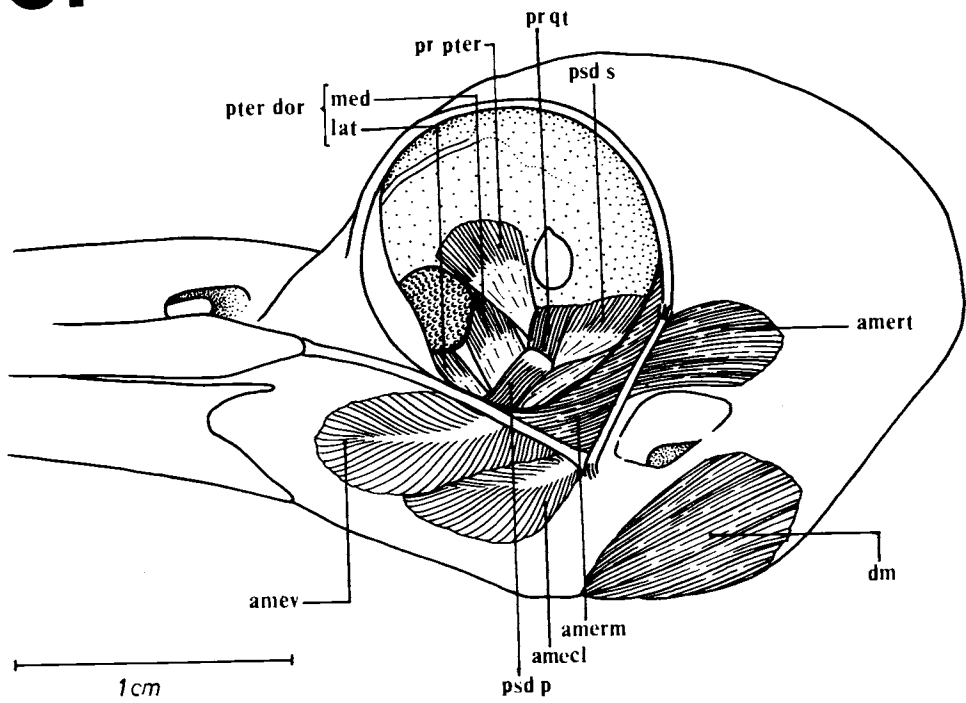
65



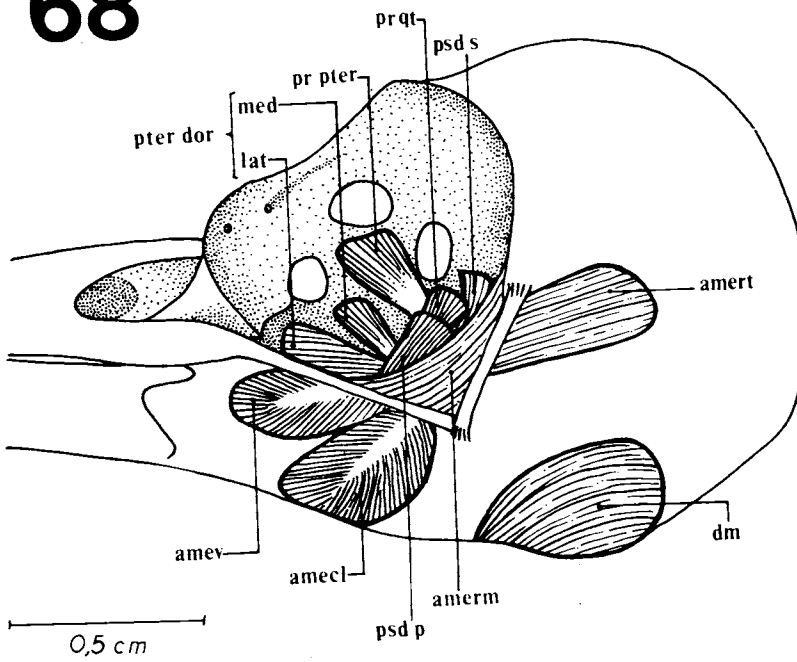
66



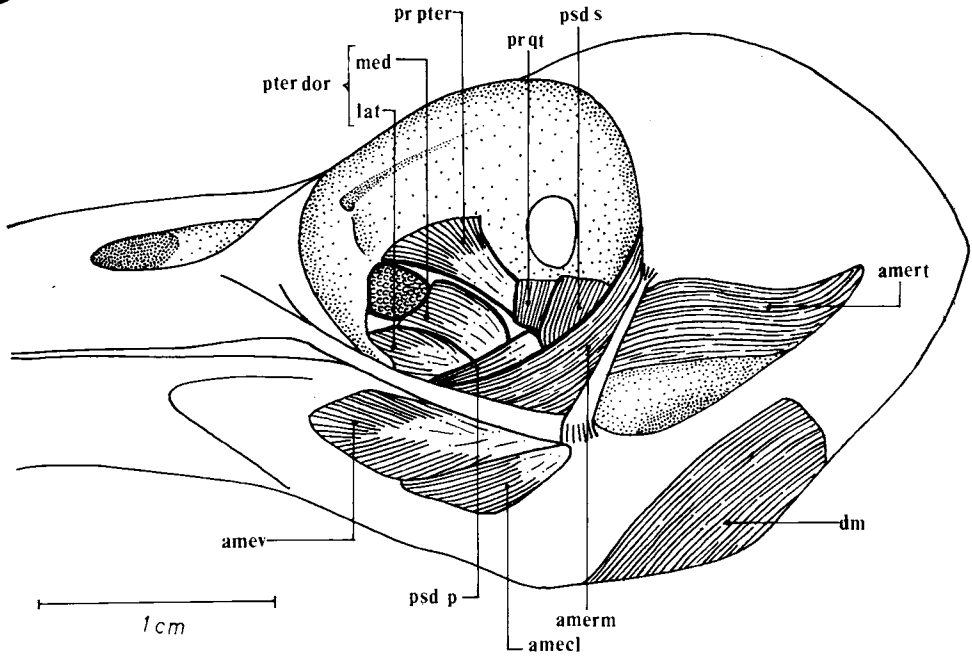
67



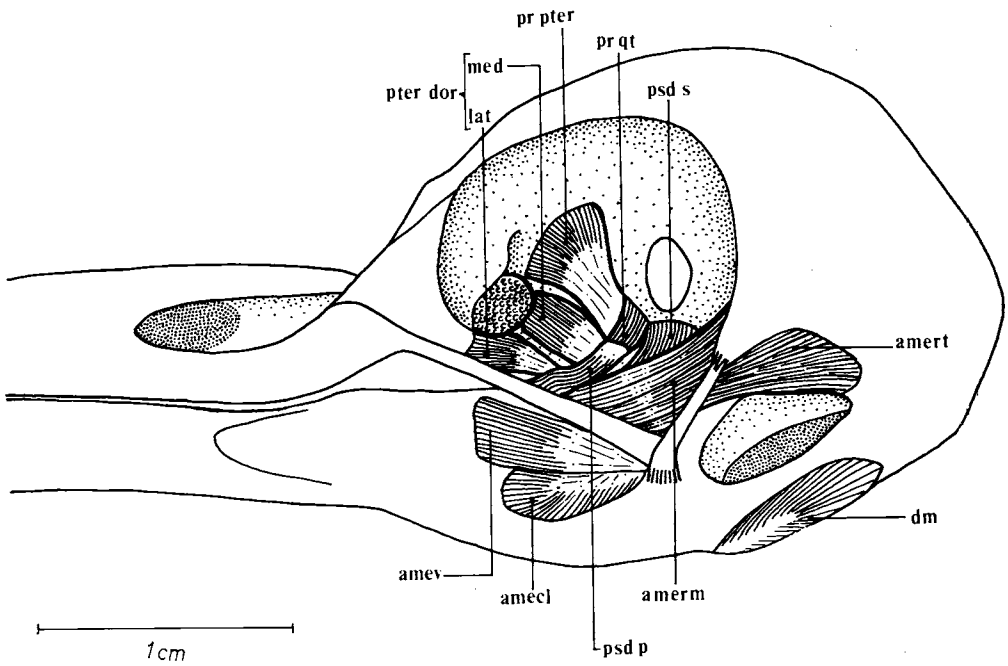
68



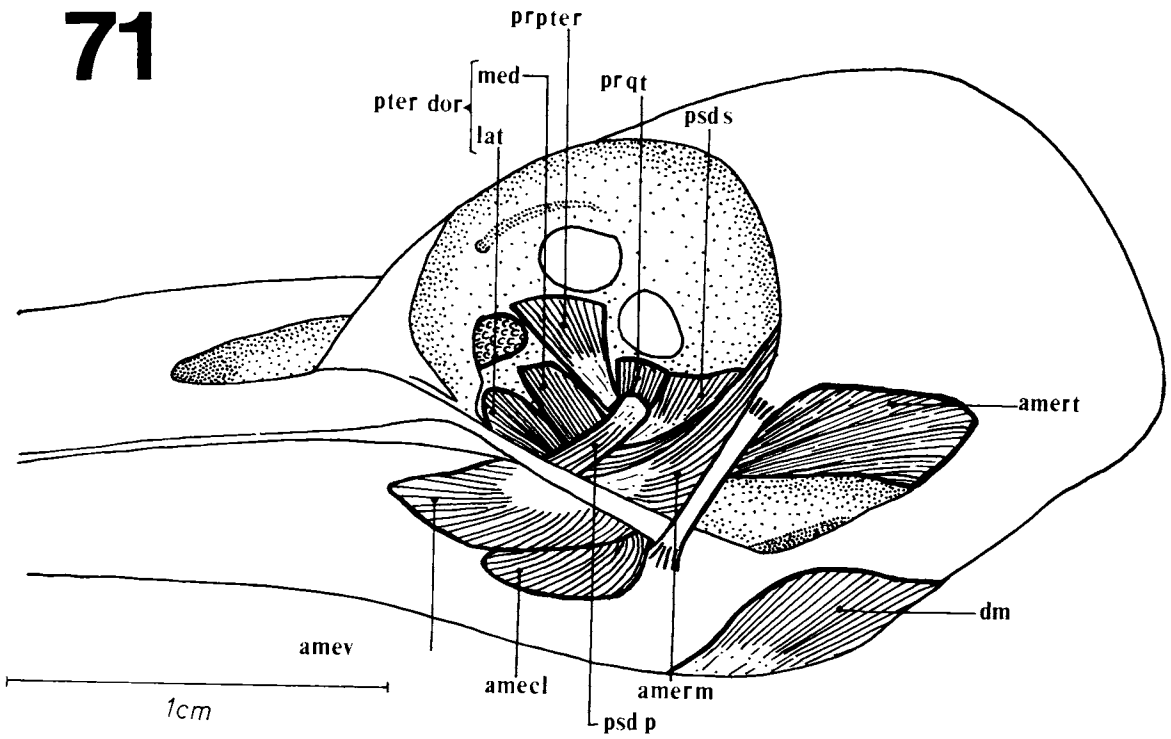
69



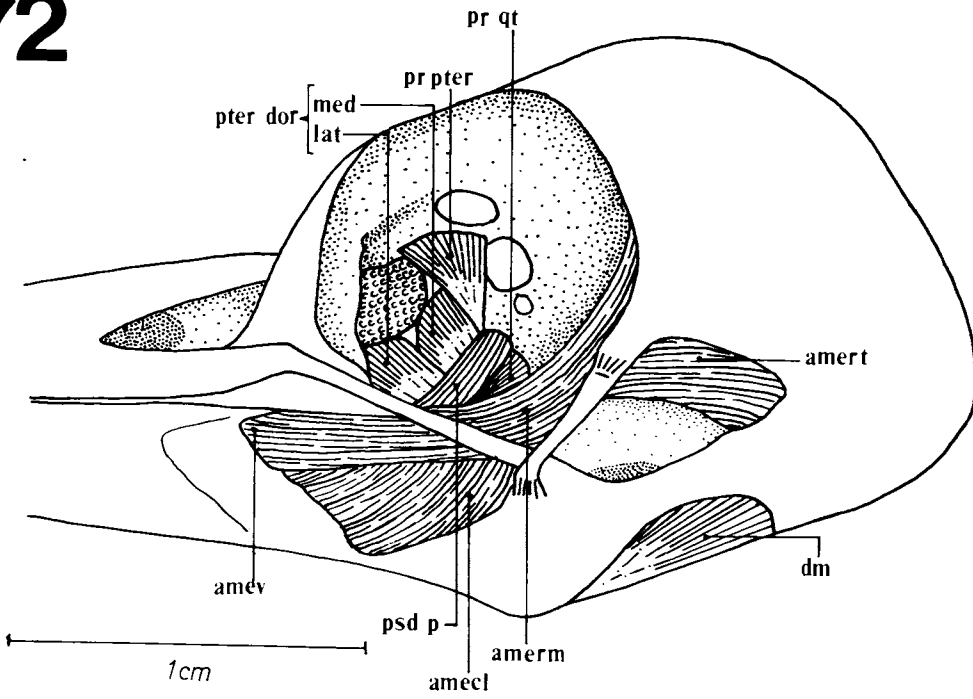
70



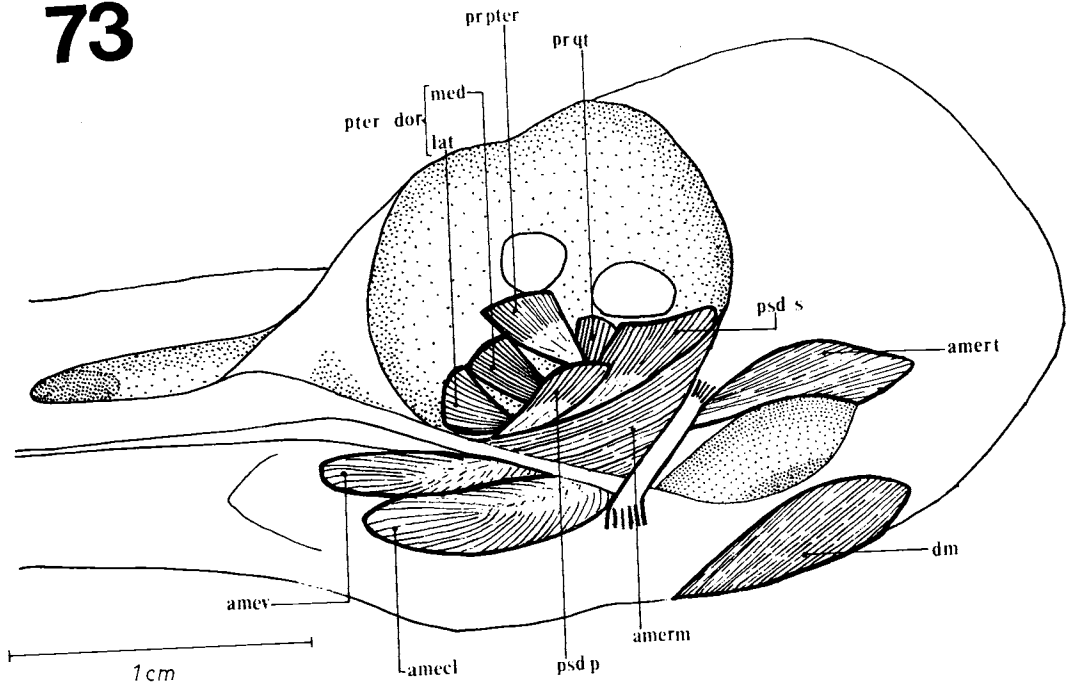
71



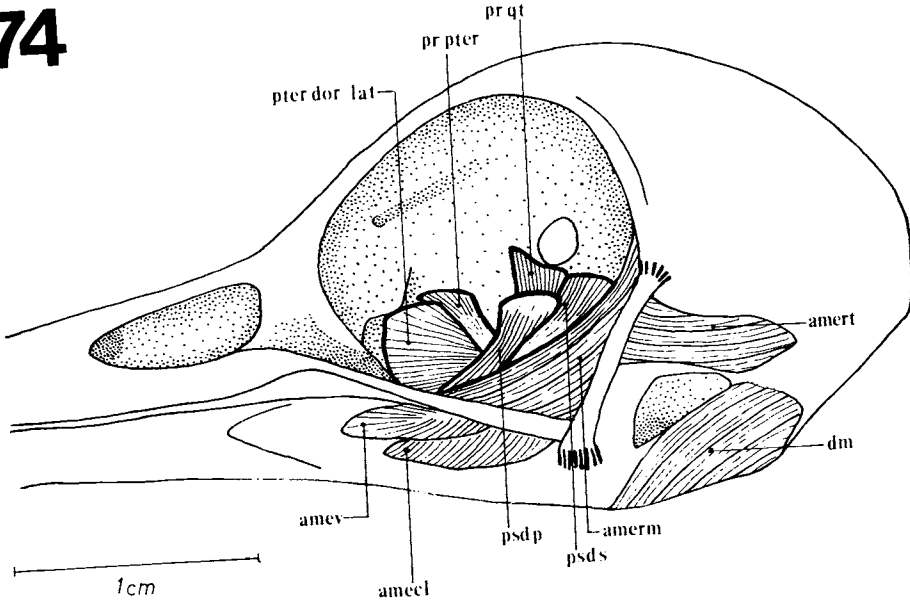
72



73



74



Figures 63-74: Musculature. Lateral view of the skull. *Campephilus rubricollis* (63), *Piculus flavigula* (64), *Ceelus flavescens* (65), *Melanerpes cruentatus* (66), *Colaptes melanochloros* (67), *Picumnus cirratus* (68), *Geocolaptes olivaceus* (69), *Campethera abingoni* (70), *Mesopicus griseocephalus* (71), *Dendropicus fuscescens* (72), *Thripia namaquus* (73) and *Jynx ruficollis* (74), showing the muscles of the jaw apparatus: amecl: *M. adductor mandibulae externus caudalis lateralis*; amert: *M. adductor mandibulae externus rostralis temporalis*; amerm: *M. adductor mandibulae externus rostralis medialis*; amev: *M. adductor mandibulae externus ventralis*; dm: *M. depressor mandibulae*; pr qt: *M. protractor quadrati*; pr pter: *M. protractor pterygoidei*; psd p: *M. pseudotemporalis profundus*; psd s: *M. pseudotemporalis superficialis*; pter dor lat: *M. pterygoideus dorsalis lateralis*; pter dor med: *M. pterygoideus dorsalis medialis*.

sociated aponeuroses are less developed in the other species studied.

2.1.1.3. *M. adductor mandibulae externus rostralis lateralis* (amerl)

The *M. adductor mandibulae externus rostralis lateralis* is the most lateral portion of the *M. adductor mandibulae externus rostralis*; it lies dorso-medially in relation to the *M. adductor mandibulae externus ventralis* and it can only be seen after removing the former.

This muscle originates aponeurotically at the dorsolateral surface of the squamosal process; the muscular fibers originate at the lateral surface of aponeurosis 3 (Fig. 76) and are oriented rostrolaterally to insert at the lateral surface of a poorly developed aponeurosis IV (Fig. 76); the latter attaches itself to the lateral surface of the mandible, rostrally to the common tendon formed by aponeuroses I, II and III and medially to the *M. adductor mandibulae externus ventralis* fibers.

Comparison: In the Neotropical species, this muscle is narrow and its aponeurosis IV is thin and poorly developed; on the other hand, among the Afrotropical species, *G. olivaceus* and *M. griseocephalus* have well-developed muscle fibers and aponeuroses. In *J. ruficollis* this muscle is vestigial, while in *D. fuscescens* and *T. namaquus* it could not be found.

2.1.1.2. *M. adductor mandibulae externus ventralis* (amev)

This muscle can be seen on the dorsolateral surface of the mandible where it shelters the *M. adductor mandibulae externus rostralis lateralis*; the *M. adductor mandibulae externus ventralis* lies dorso-rostrally in relation to the *lateralis* portion of the *M. adductor mandibulae externus caudalis*.

The superficial part originates at a well-developed aponeurosis 4 (Fig. 77) on the rostral portion of the squamosal process. The fleshy fibers originate at the lateral surface of this aponeurosis and are rostrolaterally oriented to insert on the dorsolateral surface of the mandible.

The deep part originates ventrally in relation to the superficial part. The fleshy fibers are rostrolaterally oriented and insert at the medial surface of a thin aponeurosis V (Fig. 77). The latter inserts itself at the pseudocoronoid 2

process, medially to the superficial portion.

Comparison: In *C. flavescens*, as seen in *C. rubricollis*, one observes the same origin of aponeurosis 4; in the other species, the origin of this aponeurosis is situated ventrolaterally.

2.1.3. *M. adductor mandibulae externus caudalis*

In woodpeckers this muscle is composed of two distinct parts.

2.1.3.1. *M. adductor mandibulae externus caudalis lateralis* (amecl)

Its origin is aponeurotic on the C1 crest of the optic process of the quadrate. The fleshy fibers originate at the lateral surface of aponeurosis 5 (Fig. 78) which inserts at the laterocaudal surface of the mandible, disposed ventrocaudally to the fibers of the superficial portion of the *M. adductor mandibulae externus ventralis*.

Comparison: In *M. cruentatus* (Fig. 66) and *D. fuscescens* (Fig. 72) the muscle fibers are well-developed if compared to the other species: they occupy a great area on the lateral surface of the mandible, extending almost to its dorsal surface.

2.1.3.2. *M. adductor mandibulae externus caudalis medialis* (amecm)

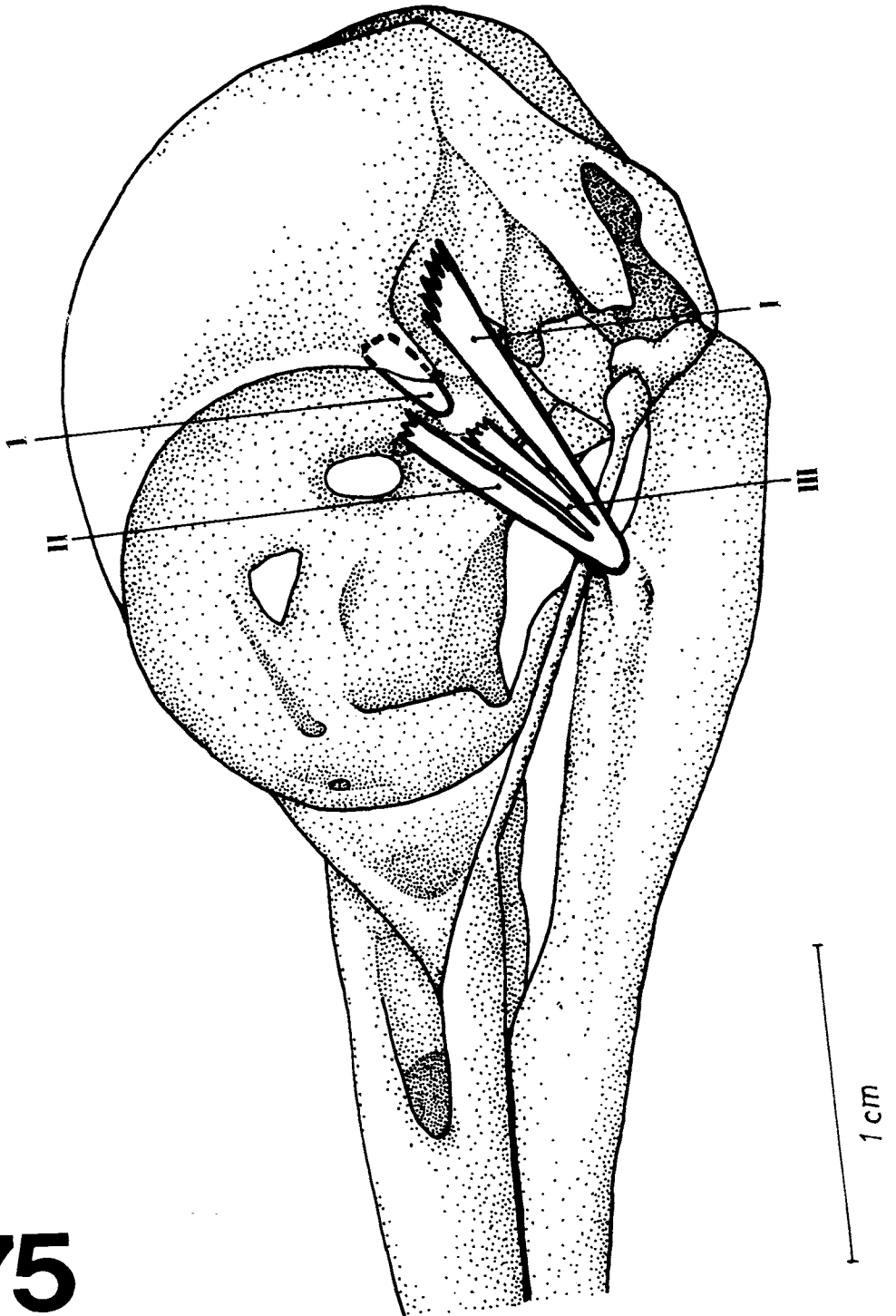
The fleshy fibers originate ventromedially from the C1 crest; they are obliquely oriented and insert at the medial surface of a short aponeurosis VI (Fig. 78). The latter inserts itself at the dorsal surface of the mandible, caudally to the *M. adductor mandibulae externus rostralis temporalis*' aponeuroses.

Comparison: In the Afrotropical species, one can observe the origin of the fibers at a well-developed aponeurosis 6 (Fig. 78). On the other hand, in *J. ruficollis* these fibers are poorly developed and there is no apparent aponeurosis.

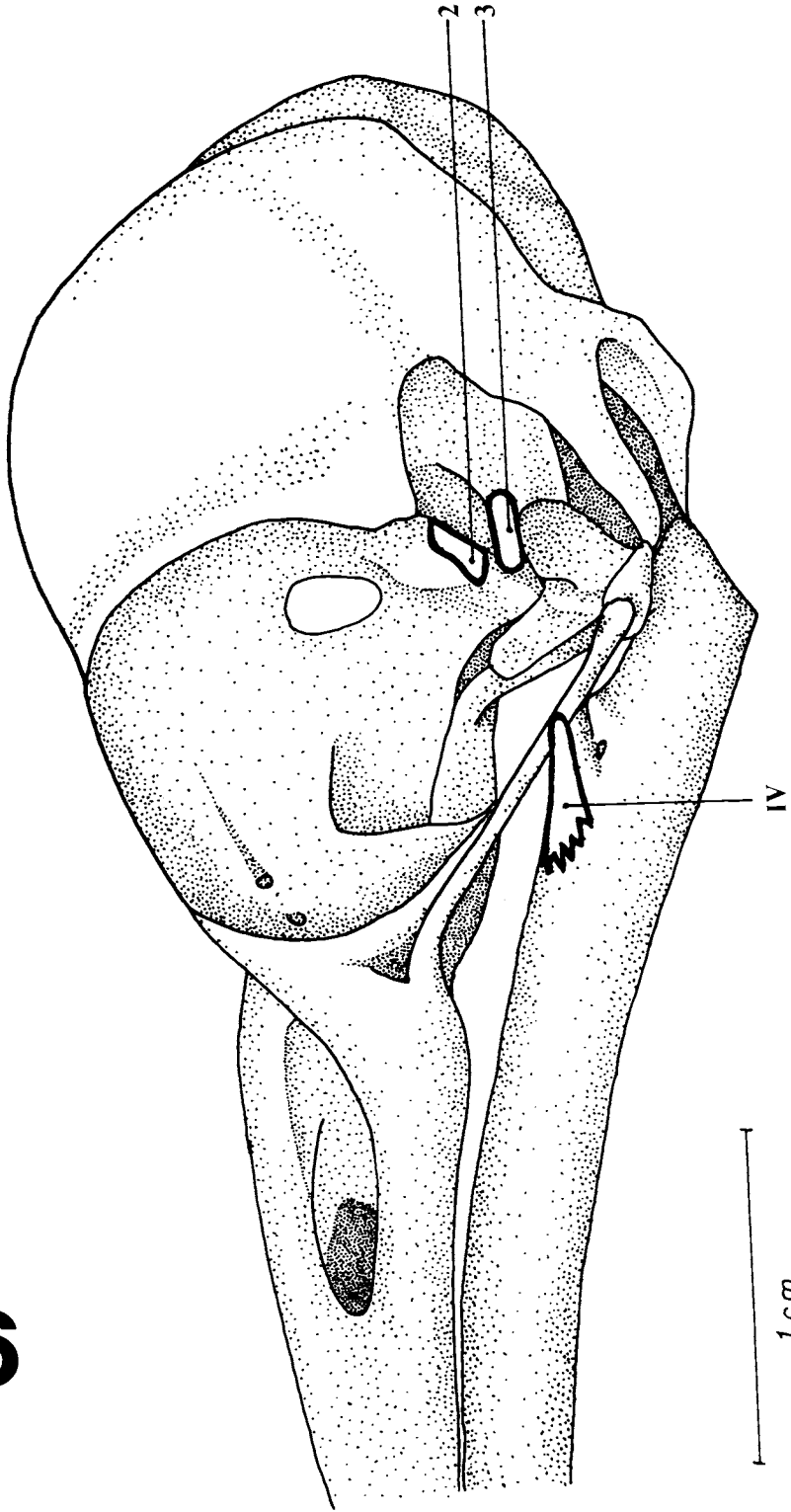
2.2. *M. adductor mandibulae posterior* (amp)

This muscle is situated at the proximal region of the orbital process of the quadrate, and runs rostromedially in relation to the adductor external mandibular system and laterally to the *M. pseudotemporalis superficialis*. It lies caudal to the *M. pseudotemporalis profundus* that originates at the distal portion of the same process.

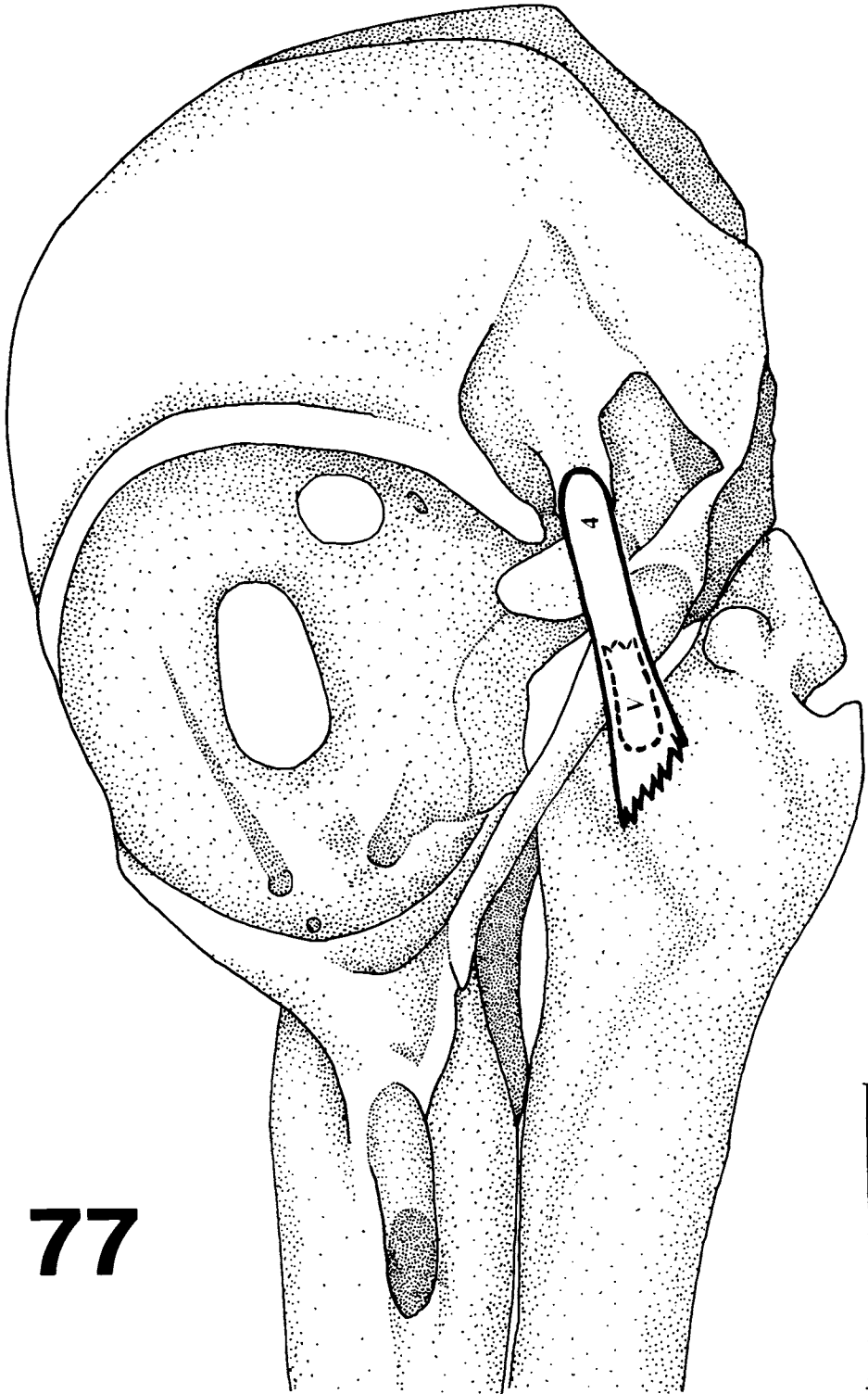
It originates from fleshy fibers which are ventromedially oriented; these fibers insert them-



75



76



77

1 cm

78

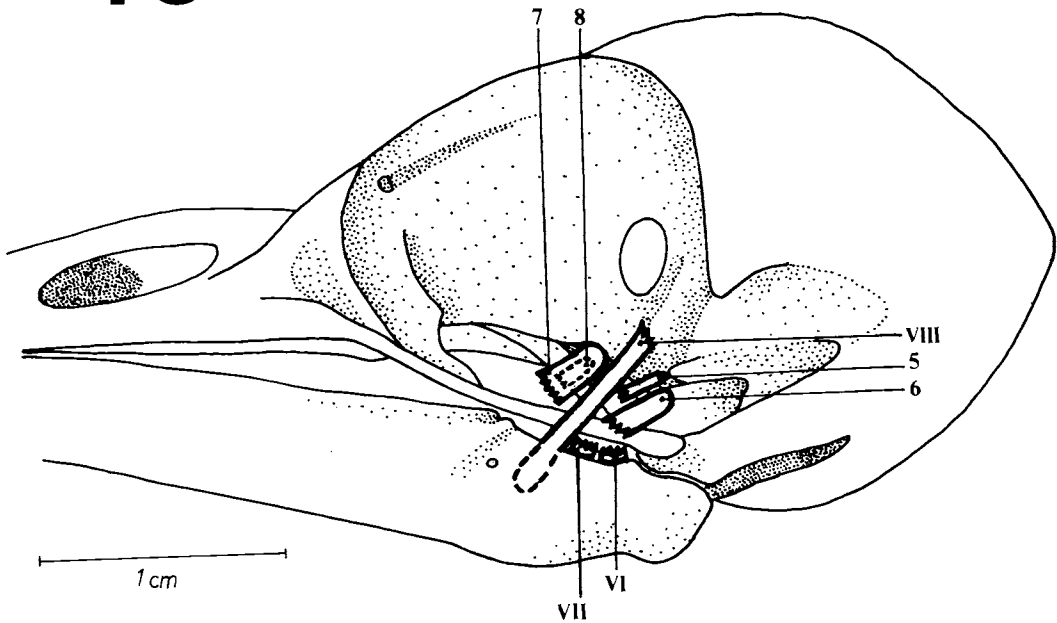


Figure 75. Aponeuroses of *M. adductor mandibulae externus rostralis temporalis* (1) and of *M. adductor mandibulae externus rostralis medialis* (1, II and III) represented in *Piculus flavigula*.

Figure 76. Aponeuroses of *M. adductor mandibulae externus rostralis medialis* (2) and of *M. adductor mandibulae externus rostralis lateralis* (3 and IV) represented in *Celeus flavescens*.

Figure 77. Aponeuroses of *M. adductor mandibulae externus ventralis* (4 and V) represented in *Campephilus rubricollis*.

Figure 78. Aponeuroses of *M. adductor mandibulae externus caudalis lateralis* (5), of *M. adductor mandibulae externus caudalis medialis* (6 and VI), of *M. adductor mandibulae posterior* (VII), of *M. pseudotemporalis superficialis* (VIII) and of *M. pseudotemporalis profundus* (7 and 8) represented in *Geocolaptes olivaceus*.

selves partly at the medial surface of aponeurosis VII (Fig. 78), and partly at the dorsocaudal region of the mandible, as well as at its medial surface near its dorsal surface. Aponeurosis VII inserts itself at the dorsocaudal surface of the mandible just in contact with the fleshy fibers.

M. adductor mandibulae posterior could only be seen after the components of the external mandibular adductor system were removed. Laterally oriented in relation to this muscle are the rami maxilar and mandibular of the trigeminal cranial nerve.

Comparison: *M. adductor mandibulae posterior* is poorly developed in all the species of woodpeckers studied: it is short, narrow and occupies a small area at origin and insertion if compared with other muscles of the woodpeckers jaw apparatus.

2.3. Internal adductor mandibular system

The orbitosphenoid crest situated on the

ventrocaudal part of the orbitosphenoid constitutes a well-marked boundary between the muscles of the internal and external systems.

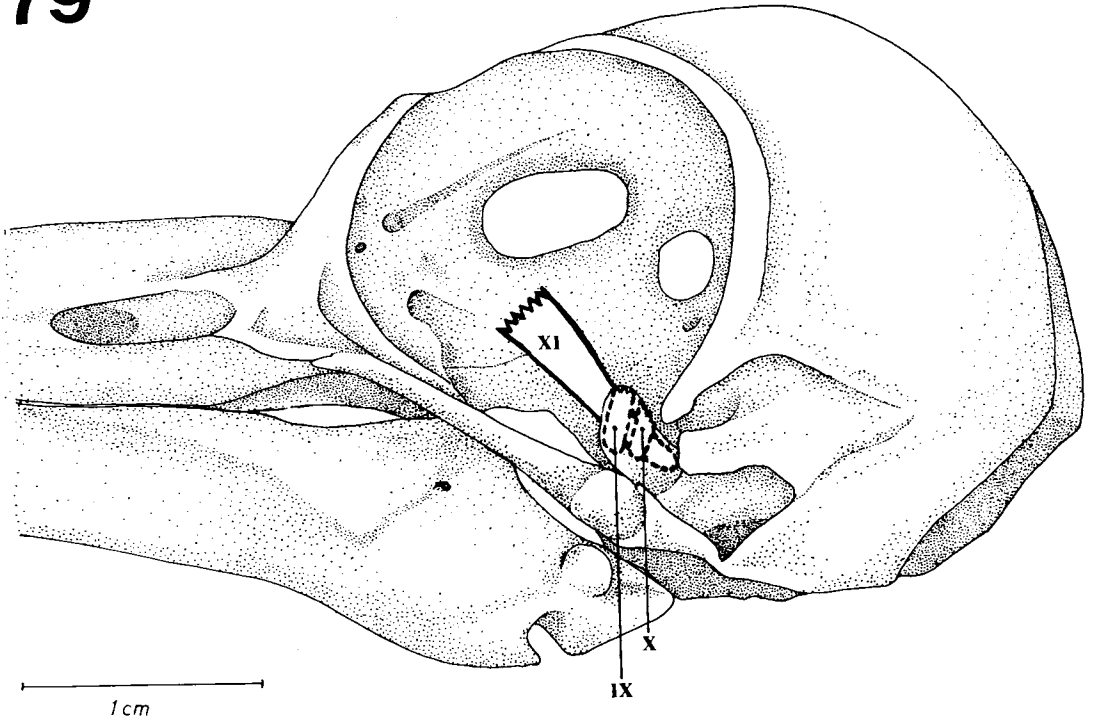
2.3.1. *M. pseudotemporalis superficialis* (psd s)

It is situated on the ventrocaudal region of the orbitosphenoid. It lies medially in relation to the *medialis* portion of the external adductor mandibular system and dorsocaudally to the *M. protractor quadrati*.

The *M. pseudotemporalis superficialis* originates from fleshy fibers on the *intumescencia* of the orbitosphenoid. Its fibers are ventromedially disposed to insert themselves at the medial surface of a well-developed aponeurosis VIII (Figs. 78 and 82). The latter inserts at the pseudotemporal tubercle of the mandible, caudally up to the fleshy portion of the *M. pseudotemporalis profundus*.

Comparison: In *D. fuscescens* (Fig. 72) this muscle is not seen at lateral view because it is covered by

79



80

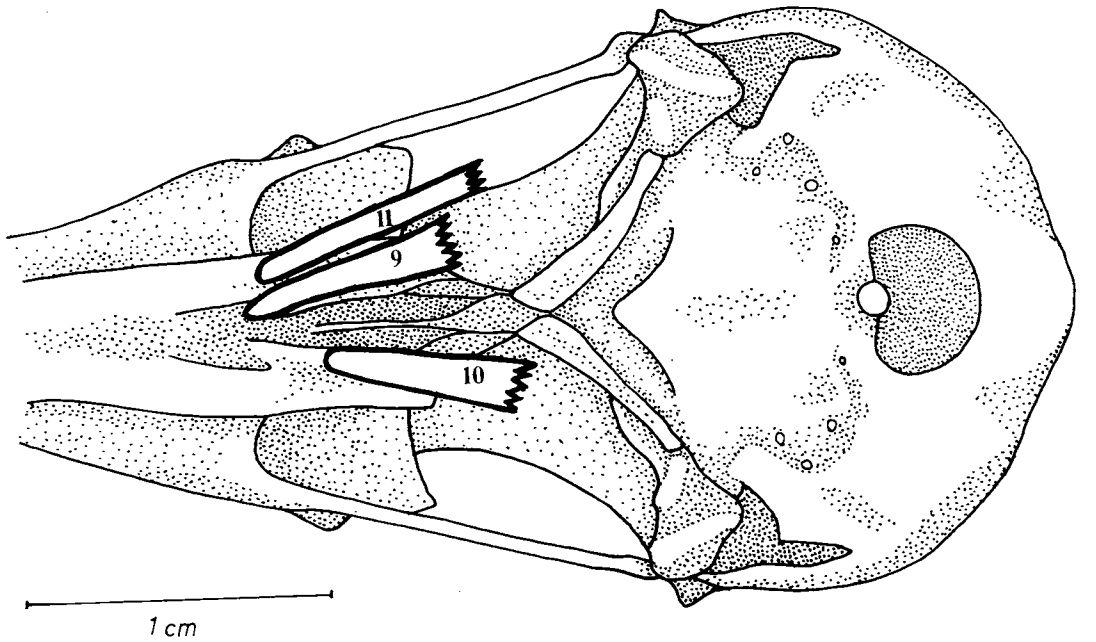


Figure 79. Aponeuroses of *M. protractor quadrati* (IX and X) and of *M. protractor pterygoidei* (XI) represented in *Campephilus rubricollis*.

Figure 80. Aponeuroses of the *pterygoideus* system: *ventralis medialis* (9 and 10) and *ventralis lateralis* (11) represented in *Mesopicus griseocephalus*.

81

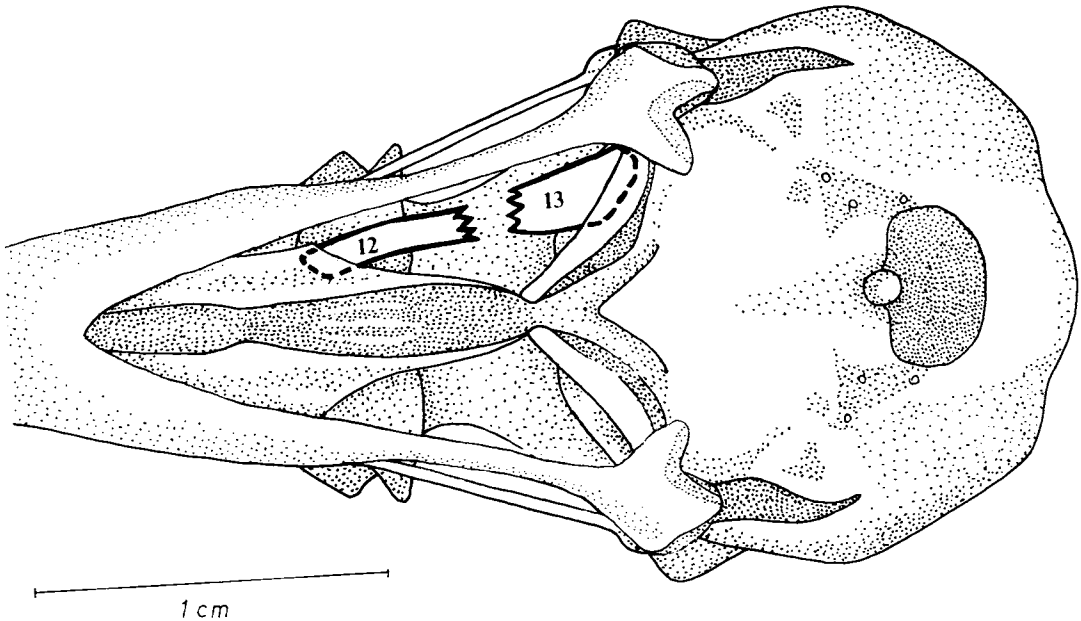


Figure 81. Aponeuroses of the pterygoideus system: *dorsalis lateralis* (12) and *dorsalis medialis* (13) represented in *Campethera abingoni*.

M. adductor mandibulae externus rostralis medialis. In *J. ruficollis* (Fig. 74) this muscle and its aponeurosis are thinner and weak. In *P. flavigula* (Fig. 64) and *M. griseocephalus* (Fig. 71) the fleshy origin is more laterally situated; also, in the latter, this muscle is less developed if compared with other Picinae. It is well-developed in other woodpeckers studied, mainly in *M. cruentatus* (Fig. 66) and *T. namaquus* (Fig. 73).

2.3.2. *M. pseudotemporalis profundus* (psd p)

This muscle is situated rostrally to the *M. adductor mandibulae posterior* muscle on the orbital process of the quadrate. It lies medially in relation to the muscles of the external adductor mandibular system and dorsolaterally to the pterygoideus dorsalis system.

The superficial part originates through a thin aponeurosis 7 (Fig. 78) at the laterorostral surface of the orbital process of the quadrate. The muscle fibers originate at the medial surface of this aponeurosis; they run rostroventrally to insert in a wide

area on the medial surface of the mandible.

The deep part originates at the lateral surface of aponeurosis 8 (Fig. 78) which originates at the rostroventral surface of the orbital process of the quadrate. This aponeurosis is broad and short at its point of origin. The fleshy fibers join those of the superficial part to insert at the medial surface of the mandible.

Comparison: In the Neotropical species, aponeurosis 8 was not observed (the description above refers to *G. olivaceus*). In *D. fuscescens* the insertion of the superficial part occupies a smaller area. Aponeurosis 8 in *T. namaquus* occupies the entire ventrolateral surface of the orbital process of the quadrate.

2.4. The protractor system of the quadrate and of the pterygoid

Although many authors consider that this muscular system is composed of just one muscle with two distinct parts (Table 1), it was observed that in woodpeckers there are two distinct and

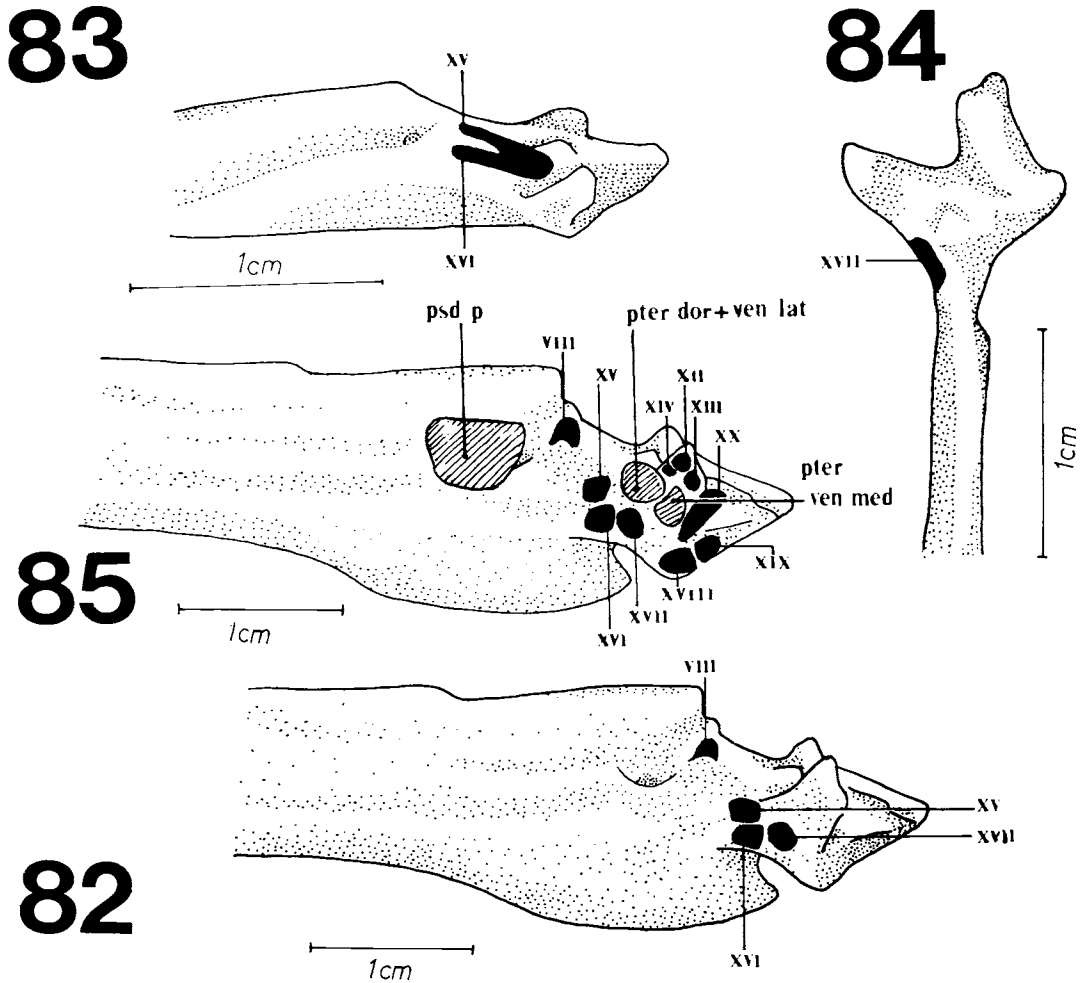


Figure 82. Aponeuroses insertions of the *pterygoideus* system in medial view of the mandible: *dorsalis lateralis* (XV and XVI) and *dorsalis medialis* (XVII); and aponeurosis of *M. pseudotemporalis profundus* (VIII) represented in *Campephilus rubricollis*.

Figure 83. Aponeuroses insertions of *M. pterygoideus dorsalis lateralis* (XV and XVI) in medial view of the mandible represented in *Jynx ruficollis*.

Figure 84. Aponeurosis insertion of *M. pterygoideus dorsalis medialis* (XVII) in dorsal view of the mandible represented in *Mesopicus griseocephalus*.

Figure 85. Areas of muscular (dotted) and aponeurotic insertions (black) on the medial surface of the mandible represented in *Campephilus rubricollis*. Roman numerals represent aponeurotic insertions.

psd p: *M. pseudotemporalis profundus*; pter dor lat + ven lat: *M. pterygoideus dorsalis lateralis* + *M. pterygoideus ventralis lateralis*; pter ven med: *M. pterygoideus ventralis medialis*.

86

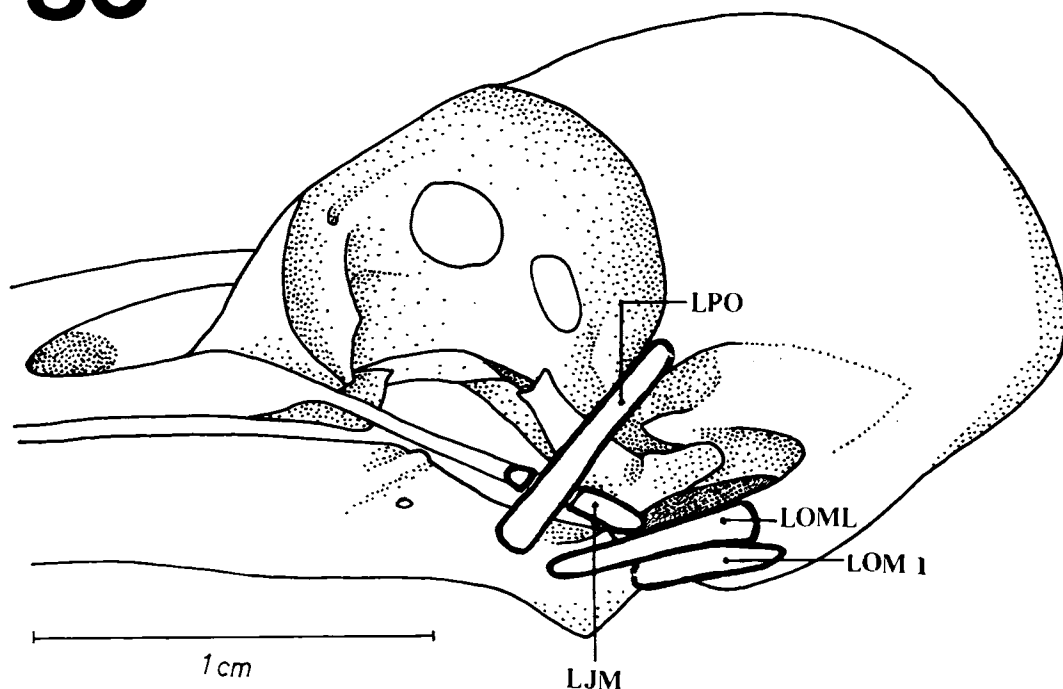


Figure 86. Lateral view of the skull of *Mesopicus griseocephalus* showing cranial Ligaments. LJM - Medial jugomandibular Ligament; LOM,1 - Medial occipitomandibular Ligament, part 1; LOML - lateral occipitomandibular Ligament; LPO - posterorbital Ligament.

independent muscles at the point of origin and insertion. The *M. protractor quadrati* is situated on the ventral edge of the orbitosphenoid; parts of its fibers are seen rostroventrally with regard to the *M. pseudotemporalis superficialis*. The *M. protractor pterygoidei* is much more developed than the *M. protractor quadrati* and originates at the interorbital septum.

2.4.1. *M. protractor quadrati* (pr qt)

There are two independent parts at origin: the first originates from fleshy fibers on the caudal region of the interorbital septum; the second, from fleshy fibers on the ventral region of the orbitosphenoid where it occupies a broad area of rostroventral origin with regard to the *M. pseudotemporalis superficialis*.

The first part inserts through aponeurosis IX (Fig. 79) on the rostromedial surface of the orbital process of the quadrate. The second, through the medial surface of a short aponeurosis X (Fig. 79), which inserts caudally to the first part.

Comparison: Only *C. rubricollis* (Fig. 79) has two points of origin associated with two aponeuroses of insertion (IX and X). *C. flavescens*, *G. olivaceus* and *M. griseocephalus* also have two points of fleshy origin but only *G. olivaceus* has one aponeurotic insertion (aponeurosis IX). In all other species only one point of origin can be observed and the insertion is always fleshy.

2.4.2. *M. protractor pterygoidei* (pr pter)

The *M. protractor pterygoidei* originates through fleshy fibers at the interorbital septum rostrally to the optical foramen. The fleshy fibers are ventrocaudally oriented and insert at the medial surface of a well developed aponeurosis XI (Fig. 79). This aponeurosis is medially oriented in relation to both the fibers of the *M. protractor quadrati* and the orbital process of the quadrate; it inserts at the dorsocaudal surface of the pterygoid, in its dorsal process (PrD - Fig. 49).

Comparison: In *D. fuscescens* (Fig. 72) and *J. ruficollis* (Fig. 74) the *M. protractor pterygoidei*

is little developed if compared with other species in which it is more developed. In these, the *M. protractor pterygoidei* is a stout muscle.

2.5. *Pterygoideus* system

This system is composed of the adductor mandibular muscles which are primary retractors of the upper jaw. All its components are connected to the palatine and/or to the pterygoid bones. Most authors (Table 1) divide this system into four distinct muscles.

2.5.1. *M. pterygoideus ventralis medialis*

It is situated at the ventral region of the palatine, medially to the *M. pterygoideus ventralis lateralis*. There is a complex system of aponeuroses, in which those of insertion are associated to the medial process of the mandible.

The fleshy fibers originate at the dorsal surface of a well-developed aponeurosis 9 (Fig. 80), which originates at the rostroventral surface of the palatine. The fleshy fibers are caudally oriented to insert partly at the ventral surface of aponeurosis XII (Fig. 85), and directly at the rostradorsal portion of the medial process of the mandible. Aponeurosis XII inserts at the same place, but medially.

A set of fleshy fibers which originate at the ventral palatine crest near the pterygoid/palatine articulation are disposed caudally to insert at the ventral surface of aponeurosis XIII (Fig. 85); the latter runs caudally to insert medially at aponeurosis XII, at the medial process of the mandible.

Comparison: An aponeurosis 10 (Fig. 80) is observed in *P. flavigula*, *C. flavescens*, *G. olivaceus* and *M. griseocephalus* on the ventral palatine crest. The fibers that originate dorsally, insert at the ventral surface of aponeurosis XIII. As observed in *C. rubricollis*, aponeurosis 10 is not manifest in the other species studied. However in *C. abingoni*, *T. namaquus* and *D. fuscescens* just one set of bundles associated to aponeurosis 9 can be observed. In *J. ruficollis* the origin is always fleshy although the insertions are aponeurotic (XII and XIII).

2.5.2. *M. pterygoideus ventralis lateralis*

This muscle is situated at the ventrolateral part of the palatine bone laterally to the *M. pterygoideus ventralis medialis*; part of its fibers

and those of *M. pterygoideus dorsalis lateralis* converge caudally before they insert at the mandible.

The muscular fibers originate at the dorsal surface of aponeurosis 11 (Fig. 80), which originates at the lateroventral edge of the palatine. These fibers are caudally oriented to the mandible and are divided into two sets of fibers: one set inserts as fleshy fibers at the medial process of the mandible, laterally to the insertion of the *M. pterygoideus ventralis medialis*; the other set enters, together with the fibers of the deep portion of the *M. pterygoideus dorsalis lateralis*, at the caudomedial surface of the mandible.

Comparison: In *M. cruentatus* and *M. griseocephalus* insertion at the caudomedial surface of the mandible includes a small portion of its laterocaudal surface. In the Afrotropical species, insertion in the medial process of the mandible is by aponeurosis XIV (Fig. 85). In *D. fuscescens*, this muscle is poorly developed. Only in *J. ruficollis* is the point of origin fleshy.

2.5.3. *M. pterygoideus dorsalis lateralis* (*pter dor lat*)

It is situated at the dorsolateral region of the palatine; it is not connected with the pterygoid bone.

The superficial portion originates through fleshy fibers on the dorsorostral surface of the palatine. These fibers insert at the medial surface of aponeurosis XV (Figs. 82 and 85) which inserts itself at the caudomedial surface of the mandible.

The deep portion originates from aponeurosis 12 (Fig. 81) which originates ventrally giving rise to the superficial fibers. The fleshy fibers originate at the dorsal surface of aponeurosis 12 and are disposed caudally to the mandible where they insert at two distinct surfaces: one at aponeurosis XVI (Figs. 82 and 85), which inserts at the caudomedial surface of the mandible, ventrally to aponeurosis XV of the superficial portion; and the other partially joins the fibers of the *M. pterygoideus ventralis lateralis* to insert at the caudomedial surface and at the medial process of the mandible. Aponeuroses XV and XVI (Figs. 82 and 85) are near each other in their points of insertion which is caudal to aponeurosis VIII (Figs. 78 and 82) of the *M. pseudotemporalis superficialis* and rostral to aponeurosis XVII (Fig. 85) of the *M. pterygoideus dorsalis medialis*.

Comparison: In *J. ruficollis* (Fig. 83), aponeurosis XV and XVI, respectively, from both the superficial and the deep part of this muscle, meet before insertion thus forming a single aponeurosis XV.

2.5.4. *M. pterygoideus dorsalis medialis* (pter dor med)

M. pterygoideus dorsalis medialis is situated at the dorsal region of the palatine bone and at the dorsolateral region of the pterygoid bone. It is ventrolaterally situated in relation to the *M. protractor pterygoidei*.

The superficial portion originates as fleshy fibers at the rostralateral surface of the pterygoid, including its rostral expansion (ExP - Fig. 49). The fleshy fibers are oriented ventrocaudally and insert at the medial surface of aponeurosis XVII (Fig. 85), which inserts at the caudomedial surface of the mandible, caudally to the aponeuroses of the *M. pterygoideus dorsalis lateralis*.

The deep part originates ventrally through aponeurosis 13 (Fig. 81). The fleshy fibers originate at its dorsal surface and join with those of the superficial portion to insert at aponeurosis XVII.

Comparison: In *G. olivaceus* the insertion of aponeurosis XVII is near the dorsocaudal surface of the mandible. In *M. griseocephalus* (Fig. 84) it is dorsocaudal, rostral to the quadrate/mandible articulation.

There is a distinct space between the *pterygoideus dorsalis medialis* and *pterygoideus dorsalis lateralis* muscles in *C. flavescens* (Fig. 65), *M. cruentatus* (Fig. 66), *C. melanochloros* (Fig. 67), *C. abingoni* (Fig. 70) and *T. namaquus* (Fig. 73); in the other species this characteristic was not observed. However at dorsolateral view, the muscular fibers of *P. flavigula* (Fig. 64) were observed to be better developed in relation to other species. The general disposition of the fibers of the *pterygoideus dorsalis medialis* and *pterygoideus dorsalis lateralis* muscles is oblique in most of the species except *M. cruentatus* (Fig. 66), *G. olivaceus* (Fig. 69) and *T. namaquus* (Fig. 73). In *J. ruficollis* (Fig. 74), the *M. pterygoideus dorsalis lateralis* covers the *M. pterygoideus dorsalis medialis* at lateral view, and is more developed in this species.

2.6. *M. depressor mandible* (dm)

M. depressor mandible is situated at the laterocaudal surface of the skull.

In woodpeckers it can be separated into three parts: superficial, intermediary and deep. The first originates from fleshy fibers on the exoccipital region. The fibers are oriented lateroventrally, to insert at the aponeurosis XVIII (Fig. 85) which inserts at the angular vertex. The intermediary fibers originate ventrally in relation to the superficial fibers and enter at the medial surface of aponeurosis XIX (Fig. 85), which inserts at the caudal surface of the mandible near the angular vertex; parallel to these fibers, fleshy fibers can be observed originating at the suprategmatic region; these fibers are associated with the occipitomandibular lateral ligament. These fibers enter at the medial surface of aponeurosis XX (Fig. 85), which inserts at the lateral crest of the mandible. Nevertheless the deep fibers are associated with the occipitomandibular medial ligament, part 1, where they originate; the insertion is fleshy on the caudal surface of the mandible. These three main aponeuroses are not well-developed if compared with those of other muscular systems.

Comparison: Besides *C. rubricollis*, the *M. depressor mandible* is also developed in *M. cruentatus* (Fig. 66), *C. melanochloros* (Fig. 67) and *G. olivaceus* (Fig. 69); it is poorly developed in *C. abingoni* (Fig. 70) and *D. fuscescens* (Fig. 72). In the other species an intermediary condition is observed.

3. Ligaments

3.1. Postorbital Ligament (LPO) - Fig. 86

The postorbital ligament originates at the lateral surface of the postorbital process; it runs lateroventrally to the mandible and covers the jugal bar/quadrate articulation. It inserts at the lateral surface of the mandible rostrally to the quadrate/mandible articulation.

3.2. Medial Jugomandibular Ligament (LJM) - Fig. 86

The medial jugomandibular ligament is a narrow ligament which originates at the laterocaudal surface of the jugal bar. It is oriented according to the caudal surface of the mandible and runs medially along the postorbital ligament. It inserts ventrally at the dorsocaudal region of the mandible's medial process, up to the insertion of parts 1 and 2 of the the medial

occipitomandibular ligaments.

The lateral jugomandibular ligament was not observed in the woodpeckers studied.

3.3. Medial Occipitomandibular Ligament, part 1 (LOM, 1) - Fig. 86

The medial occipitomandibular ligament, part 1, is closely associated with the *M. depressor mandible*; it originates partly at the ala timpanica region where it covers a large portion and partly at the exoccipital process. It is oriented rostroventrally in relation to these regions to insert at the dorsocaudal surface of the medial process of the mandible, laterally in relation to part 2.

3.4. Medial Occipitomandibular Ligament, part 2 (LOM, 2)

The medial occipitomandibular ligament, part 2, originates at the exoccipital process and inserts itself at the dorsocaudal surface of the medial process of the mandible. It is a short and stout ligament existing in all the species studied.

3.5. Lateral Occipitomandibular Ligament (LOML) - Fig. 86

The lateral occipitomandibular ligament originates at the lateral surface of the suprameatic region and inserts at the laterocaudal surface of the mandible, caudally to the postorbital ligament. *Comparison:* Among the species studied only *J. ruficollis* does not have a well-developed postorbital ligament. This could be related to the inconspicuous postorbital process in this species (PrPO - Fig. 24). In *J. ruficollis* and in *P. cirratus*, the medial occipitomandibular ligament originates at the exoccipital region, insofar as no exoccipital process was observed.

The lateral occipitomandibular ligament was observed in the Picinae and in the Picumninae, although it is less developed in *P. cirratus*. Burton (1984), on the other hand, observed this ligament only in the Picinae.

4. Tongue (Figs. 87-90)

The hyoid apparatus (Fig. 87) is formed by the following bones: entoglossum, basihyal, ceratobranchial, epibranchial and urohyal. The horny entoglossum (ENT - Fig. 88) generally has many sets of spines; it is connected caudally to the basihyal (BAS - Figs. 87 and 88) which is the central unit of the tongue; it also articulates

with the ceratobranchials and with the urohyals (URO - Figs. 87 and 88). The ceratobranchials (CER - Figs. 87 and 88) articulate with the epibranchials (EPI - Fig. 87); these are the only two elements noticed in pairs in birds. The epibranchials (EPI - Fig. 89 A-H) or horny hyoids extend dorsally on the skull. All species of woodpeckers here analysed had spines at the entoglossum except *P. cirratus* and *J. ruficollis*: in these species the spines of the entoglossum were not observed, *i.e.*, their tongues were smooth (Fig. 90 I).

DISCUSSION

A. Aspects of the cranial osteology

After having analysed the osteological structures of the skull in the woodpeckers studied, seven characteristics became apparent, common to all woodpeckers, - though some structures in particular may not be well-developed in one determined species: the dorsal process of the pterygoid, the ventral palatine fossa, the rostral expansion of the pterygoid, the pseudocoronoid 1 and pseudocoronoid 2 processes, the short medial process of the mandible and the caudal fossa of the mandible.

The first of the aforementioned characteristics was described as peculiar to woodpeckers (Hofer, 1945); it is also associated with the well-developed *M. protractor pterygoidei* in these birds in relation to other Piciformes (Beecher, 1953). The ventral palatine fossa lodges the stout retractor of the lower jaw, *M. pterygoideus ventralis medialis*. Although Gennip (1986) related this muscle and its origin at the ventral palatine fossa to the muscle's partial development, others, studying the same group of birds (Columbidae - Rooth, 1953; Merz, 1963) did not mention this kind of relationship but described the extent of development of this muscle.

The rostral expansion of the pterygoid can also occur in the Indicatoridae as observed by Burton (1984), where "the pterygoid foot overlaps the palatine extensively at its posterior end." Besides the pterygoid itself, this structure is also the point of origin of the *M. pterygoideus dorsalis medialis*, another important retractor muscle of the upper jaw. Burton (*op. cit.*) confirms its occurrence in

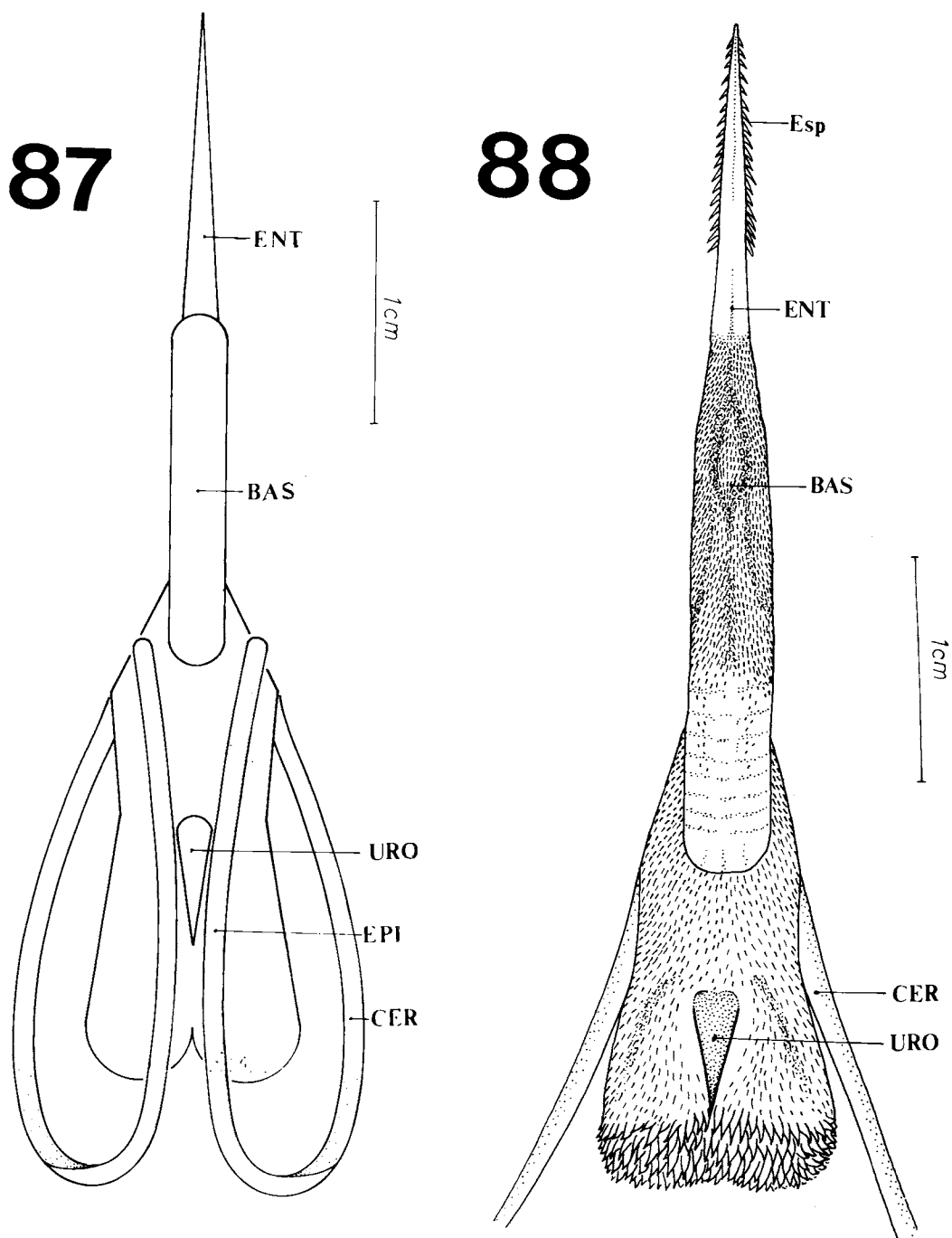


Figure 87. General scheme of the tongue of a woodpecker showing its bony regions and the extension of the ceratobranchials and of the epibranchials. BAS - basyhyal; CER - ceratobranchial; ENT - entoglossum; EPI - epibranchial; URO - urohyal.

Figure 88. General aspect in dorsal view of the tongue of *Campephilus rubricollis* showing its bony regions and spines. BAS - basyhyal; CER - ceratobranchial; ENT - entoglossum; Esp - spines; URO - urohyal.

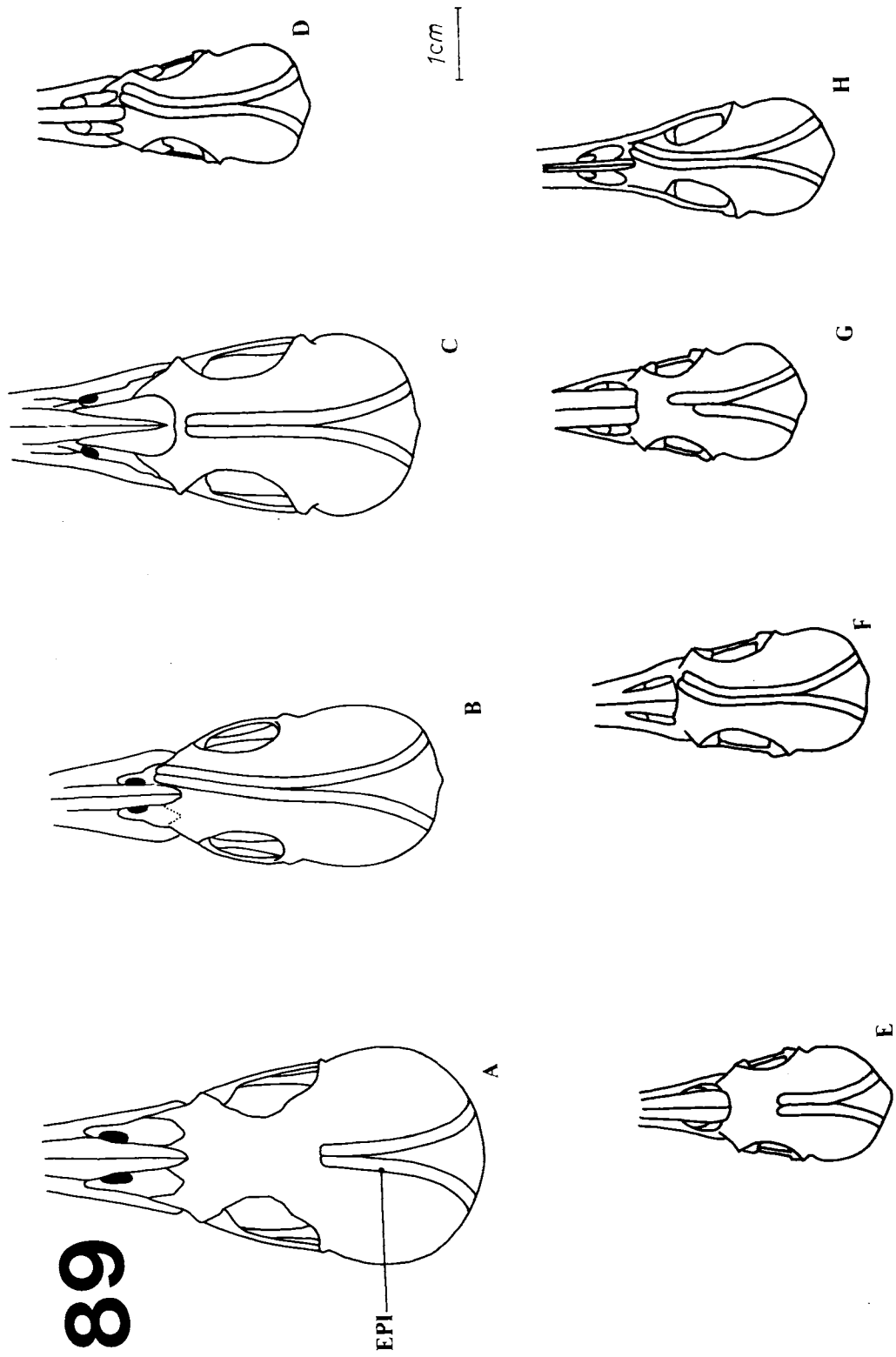


Figure 89. Dorsal aspect of the skull of *Campephipilus rubricollis* (A), *Cateus flavescens* (B), *Piculus flavigula* (C), *Geocolaptes olivaceus* (D), *Campethera abingoni* (E), *Mesopicus griseocephalus* (F), *Thripias namaquus* (G) and *Jynx ruficollis* (H), showing the development of the epibranchials.

90

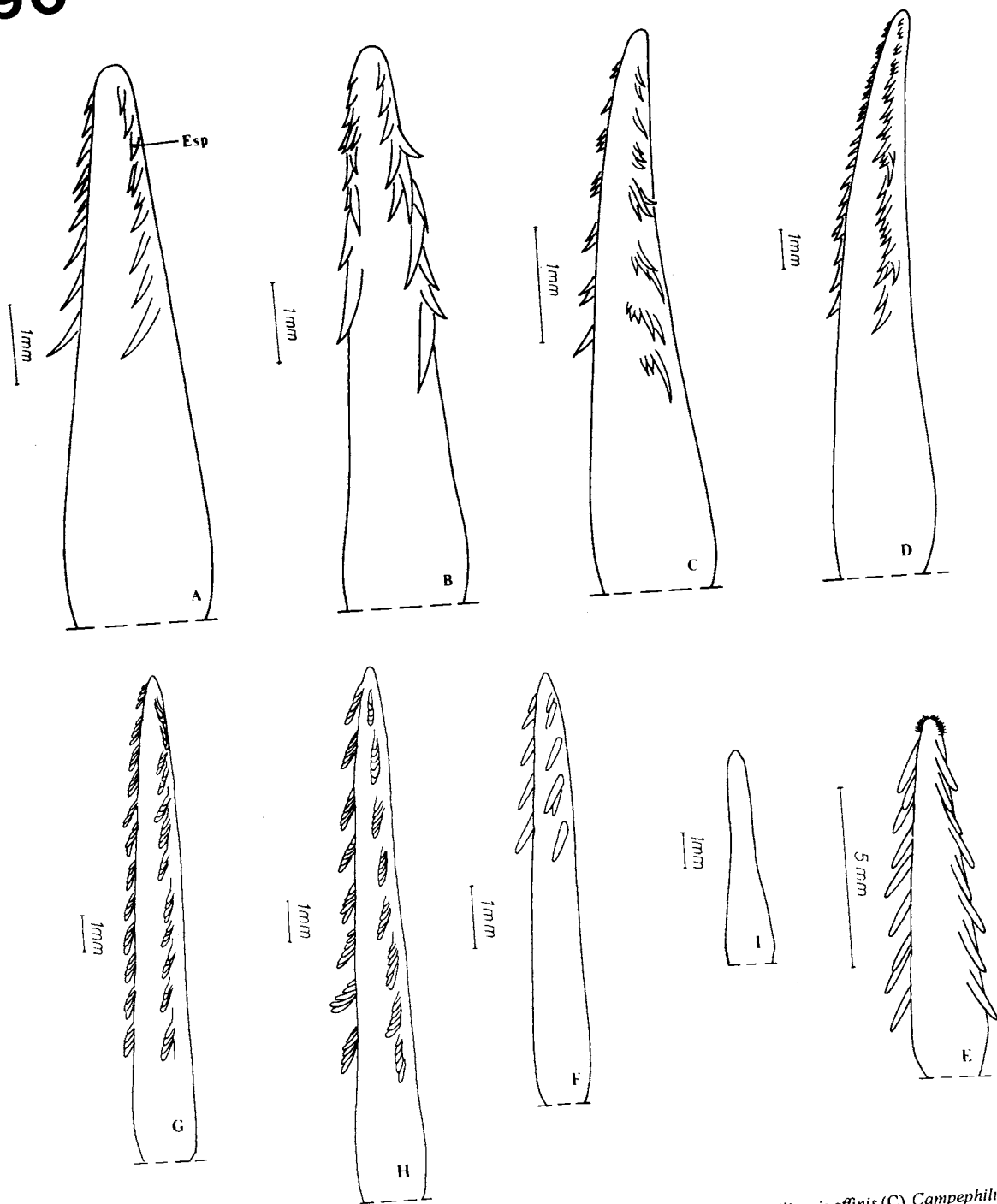


Figure 90. Dorsolateral view of the entoglossum in *Piculus flavigula* (A), *Celeus flavescens* (B), *Veniliornis affinis* (C), *Campephilus rubricollis* (D), *Geocolaptes olivaceus* (E), *Campethera abingoni* (F), *Mesopicus griseocephalus* (G), *Thripias namaquus* (H) and *Jynx ruficollis* (I), showing the form, disposition and the number of spines of this region.

the Picinae and Picumninae but it was also described here for *J. ruficollis* (Jynginae). Since this structure is not formally described in literature, the term *Expantione Rostralis* - rostral expansion of the pterygoid - might be proposed in this case.

The caudal fossa is not as deep as its name indicates, compared with the structure of other Piciformes (Höfling & Gasc, 1984; Donatelli, 1992). On the contrary, it is a shallow fossa; it is an important point of attachment of the muscular fibers of the *M. depressor mandible*. According to Burger (1978), the deeper this fossa, the greater the muscular mass within it; consequently, the greater the force of the depression, the greater the speed of the depression. Thus, one could infer that in Picidae, the *M. depressor mandible* is associated with a relative slower protraction of the upper jaw if compared to those groups of birds which have a deep caudal fossa.

It was noticed that in the woodpeckers studied there is no frontolacrimal suture as seen in Galbulidae by Donatelli (1992). The *proeminentia cereberalis*, characteristic of the Galbulidae species (Donatelli, *op. cit.*), is poorly developed in these woodpeckers. In relation to the medial process of the mandible, it can be said that in woodpeckers it is less developed than in the Ramphastidae (Höfling & Gasc, 1984) and in the Galbulidae (Donatelli, *op. cit.*).

C. rubricollis is the only species that has a long postorbital process, a lateral expansion of the lacrimal bone and a deep groove in the angular region of the mandible not seen in other Piciformes (Burton, 1984); it is also unique in not having a subcondylar process. The long postorbital process was described for the Bucconidae and Capitonidae (Burton, 1984); in the Galbulidae only *Jacamerops aurea* showed a short postorbital process (Donatelli, 1992).

The temporal fossa is vertically longer than horizontally in all species except *T. namaquus*. Among the Piciformes a well-developed temporal fossa can be observed in the Ramphastidae (Höfling & Gasc, 1984), in the Galbulidae (Donatelli, 1992) and in the Bucconidae (Donatelli, *manusc.*). However in many other groups of birds, this fossa is little developed (Rooth, 1953; Merz, 1963; Richards & Bock, 1973; Gennip, 1986).

The squamosal process provides a greater

surface area for the aponeuroses and fibers of the external adductor muscles. It is very distinctive in woodpeckers, particularly in *C. rubricollis*, *C. flavescens* and *T. namaquus*; in other Piciformes the squamosal process is rather distinct from that described for the Picidae, mainly for the Galbulidae (Donatelli, *op. cit.*) and for the Ramphastidae (Höfling & Gasc, 1984). In these cases the squamosal process is short and poorly developed.

The exoccipital process is relatively well-developed in woodpeckers. Bock (1960) pointed out that in woodpeckers the exoccipital process is well-developed and runs parallel to the basitemporal lateral process. In most of the woodpeckers analysed, the exoccipital process does not run parallel to the basitemporal lateral process; moreover, the latter is absent or poorly-developed in woodpeckers.

There are significant differences between the cranial osteological characteristics of *J. ruficollis* and other woodpeckers. The orbital process of the quadrate is turned upwards into the orbitosphenoid region; there is no orbitosphenoid crest, no C1 crest of the optic process of the quadrate and no occipitomandibular lateral ligament; there are also poorly developed postorbital and dorsal pterygoid processes. Moreover, there are several differences related to the development of many osteological structures. *J. ruficollis* and *P. cirratus* share a poorly developed squamosal process, short projection of the ectethmoid bone and absence of the basioccipital process. However, *P. cirratus* share many more osteological characteristics with the Picinae than with the Jynginae represented here by *J. ruficollis*.

B. Aspects of the jaw musculature

The structural complexity of the jaw musculature is shown in the literature where many synonyms for a single muscle are found (Table 1). Therefore, Baumel *et al.* (1979) presented a history of the synonyms and suggested one name for each muscular component. However, in spite of great structural variation in the jaw musculature in several groups of birds, many authors usually follow one determined author according to the group he/she is working with. As a matter of fact, this process occurred before and even after the publication of *NAA*. For instance, Burton (1974a) uses

the nomenclature proposed by Starck & Barnikol (1954) to describe the jaw musculature of the *adductor mandibulae externus* system in the Charadriiformes and followed Lakjer's proposal (1926) to describe the same system in the Coraciiformes and Piciformes (Burton, 1984). The same could be said in relation to the *pterygoideus* system where many nomenclatural modifications are observed (Table 1). For example, some authors (Zusi, 1962; Merz, 1963 and Burton, 1974a), following Starck & Barnikol (1954), divided this muscular complex according to three main aponeuroses, while others followed Lakjer's proposal (1926). One author could even use two different terminologies for the same muscular system in different groups of birds (Burton, 1974a and 1984).

These examples show how complex it is to unify the terminology of the jaw musculature. Accordingly, the excellent work of Baumel *et al.* (1979) is very important as a reference guide for general terminologies, although it is not a proposal for standardizing these terminologies.

As a consequence, there are many authors who use their own terminologies or follow one determined author to describe the jaw musculature: Shufeldt (1890, *apud* Merz, 1963); Gadow (1891, *apud* Merz, 1963); Lakjer (1926); Edgeworth (1935, *apud* Merz, 1963); Hofer (1945; 1950); Beecher (1951); Davids (1952); Starck & Barnikol (1954); Bams (1956); Zusi (1962); Merz (1963); Bock (1960; 1966); Berger (1966); Bühler (1970; 1981); Bock & Morioka (1971); Richards & Bock (1973); Zweers (1974); Burton (1974a; 1974b; 1974c; 1977; 1984); and Höfling & Gasc (1984), among others.

If on one hand, the terminology of the jaw musculature offers a wide synonymy, its function is well-defined and well-accepted by many authors. It can be found in Zusi (1962), Burton (1974a) and Bühler (1981).

The complexity of the jaw musculature in the Picidae is notable when compared with that of other groups of birds (Table 1). There are two easily distinguished components of the adductor mandibular system which were not described in many groups of the Aves class: *M. adductor mandibulae externus rostralis medialis* and *M. adductor mandibulae externus rostralis lateralis*. This is not only a matter of differences or divergences in synonymy of the jaw musculature but

also a matter of standpoint on the development of *M. adductor mandibulae externus rostralis*: it shows independent points of origin and insertion in the Picidae as well as in the Drepanididae (Richards & Bock, 1973); it also joins others adductors to elevate the upper jaw when it is partly elevated; and it also completes the action of other adductors. The insertion far from the articulation quadrate/mandible indicates that its main function is to squeeze any object caught in the bill. However, these components are not peculiar to woodpeckers as the *M. etmomandibularis* is to Psittacidae (Burton, 1974c).

In general, it was observed that the mandibular adductors are relatively less developed in the Picidae if compared with the description of this system in other groups of birds (Zusi, 1962; Zusi & Storer, 1969; Höfling & Gasc, 1984; Burton, 1984 and Donatelli, 1992). However, they are relatively more developed if compared with the description of the same system in the Columbidae (Rooth, 1953; Merz, 1963 and Gennip, 1986) and Psittacidae (Burton, 1974c).

Considerably strong mandibular adductors were found in *C. rubricollis* and in *G. olivaceus*. *M. cruentatus*, and *D. fuscescens* show greater development in the *M. adductor mandibulae externus caudalis lateralis*; *G. olivaceus* and in the *M. griseocephalus*, in the *M. adductor mandibulae externus rostralis lateralis*. Thus if in this system is investigated in terms of subfamilies of the Picidae, according to Peters (1948), the Picinae can be seen to be more developed if compared to the Picuminae and to the Jynginae. On the other hand if one compares the Neotropical and the Afrotropical Picinae, the difference in aponeurosis 6 of the *M. adductor mandibulae externus caudalis medialis*, apparent only in the Afrotropical woodpeckers, will be evident.

Richards & Bock (1973: Table 3, p. 75) compared the relative size of the jaw muscles of four species of *Loxops*. They established ranks for relative size, the largest muscle given the rank of "1" - the larger muscles were considered stronger, *i.e.*, they develop a greater maximum force. They attributed larger or smaller development to different ways of feeding: birds with the weakest set of jaw muscles fed on smaller, soft-bodied insects and nectar; those with the strongest set of jaw closers were mainly insectivores and ate food

from the surface of crevices in the bark of large branches and tree trunks. This kind of analysis could not be made in relation to the woodpeckers studied because they eat mostly insects and/or insect larvae, caught in the crevices of tree trunks or even found on the ground. Interestingly, there may not exist any distinction between the feeding behavior and the way the external mandibular system is developed in woodpeckers: two species that forage in different ways could have the same muscle development of these muscular systems, as seen in *C. rubricollis* and in *G. olivaceus*.

Among the woodpeckers studied, the *M. pseudotemporalis superficialis* showed many structural differences. In addition to its developed muscular and aponeurotic structure, its general form and origin are also outstanding. In general, the *M. pseudotemporalis superficialis* originates at the ventrocaudal part of the orbitosphenoid region confirming Burton's observations (1984) "...it never extends very high up into the orbit wall." If it is compared with the Bucconidae (Burton, *op. cit.*) and with the Galbulidae (Donatelli, 1992), it is much more developed in woodpeckers, mainly in *M. cruenta* and *T. namaquus*. Zusi & Storer (1969) noticed that in *Podilymbus* this muscle is composed of two parts with distinct origins: the first part originates laterally on the skull whereas the second resembles that of other groups of birds.

In general, the *M. pseudotemporalis superficialis* has a simple unipennate arrangement which elevates the mandible. In *Rhynchops nigra*, Zusi (1962) observed that the *M. pseudotemporalis superficialis* also plays an integrated function with the *M. depressor mandibulae*, whereas it maintains the mandible stable when the bird slips into the water with its mandible. The author also emphasizes that it is the main mandibular adductor that stabilizes the mandible, whereas the other adductors of the external mandibular system have the function of catching the prey and keeping it between the bird's jaws. In *Podiceps cristatus*, Bams (1956) observed that its aponeurosis joins that of the *M. adductor mandibulae externus*. Gennip (1986), studying the Columbidae, described dorsal and lateral insertions of this muscle according to the *spina* of the

pseudocoronoid process. The lateral insertion seems to have been noticed only by Gennip, since Rooth (1953) and Merz (1963) did not observe it when they studied species of the same family.

Aponeurosis 8 of the *M. pseudotemporalis profundus* was observed only in the Afrotropical species. In the studies on jaw musculatures of birds in literature, it was observed that in *Rhynchops nigra* this muscle is unique in entering caudally to the *M. pseudotemporalis superficialis* (Zusi, 1962). Moreover, it is poorly developed in this species, perhaps due to the limited orbital process of the quadrate, if compared with some other groups of birds (Zusi & Storer, 1969; Burton, 1984). According to Rooth (1953) and Merz (1963), this muscle varies greatly among the species of Columbidae analysed. Merz (1963) attributed the origin of the *M. pseudotemporalis profundus* to the medial surface of the mandible, whereas it entered the orbital process of the quadrate; it is interesting that he did not make the same description for the *M. adductor mandibulae posterior* which also originates at the orbital process of the quadrate. Other authors considered this muscle and *M. adductor mandibulae posterior* as a single muscle, *M. quadratomandibularis* (Hofer, 1950; Sims, 1955). In Psittacidae, the *M. pseudotemporalis profundus* was not observed by Burton (1974c).

The *M. adductor mandibulae posterior* is short and poorly developed in the woodpeckers studied. The same condition was attributed to the Bucconidae (Burton, 1984) and to the Galbulidae (Donatelli, 1992). On the other hand, this seems not to occur with the Indicatoridae and the Capitonidae (Burton, *op. cit.*) and with the Ramphastidae (Höfling & Gasc, 1984).

The reason why many authors consider the muscles, *protractor quadrati* and *protractor pterygoidei*, as a single muscle subdivided into two parts, *M. protractor quadrati et pterygoidei*, is probably related to the proximity of their fiber origins - if one considers structural aspects - or even their integrated functions. This muscle was described as a single unit by Bams (1956), Burton (1984) and Gennip (1986) among others (Table 1). These considerations are shared by Hofer (1950) and Sims (1955) who considered

Table 1. Synonymy of the Jaw Musculature

Present Paper	SHUFELDT (1890) apud MERZ (1963)	GADQW (1891) apud MERZ (1963)	LAKJER (1926)	EDGEWORTH (1935) apud MERZ (1963)	ADAMS (1942) apud MERZ (1963)	HOFER (1950)	BEECHER (1951)
<i>M. adductor mandibulae externus rostralis temporalis</i>	part of <i>M. temporalis</i>	parts 1 and 2 of <i>M. temporalis</i>	<i>M. adductor mandibulae externus superficialis</i>	<i>M. adductor mandibulae externus (part)</i>	<i>M. capiti mandibularis medius and profundus</i>	<i>M. adductor mandibulae externus superficialis</i>	<i>M. adductor mandibulae externus superficialis (part)</i>
<i>M. adductor mandibulae externus rostralis medialis</i>	-	-	-	-	-	-	-
<i>M. adductor mandibulae externus rostralis lateralis</i>	-	-	-	-	-	-	-
<i>M. adductor mandibulae externus ventralis</i>	part of <i>M. masseter and temporal</i>	parts 1, 2 and 3 of <i>M. temporalis</i>	<i>M. adductor mandibulae externus medialis</i>	<i>M. adductor mandibulae externus (part)</i>	<i>M. capiti mandibularis superficialis, 1st part</i>	<i>M.a.m.e. medius and part of superficialis</i>	<i>M. a. m. externus (part) and medialis</i>
<i>M. adductor mandibulae externus caudalis</i>	part of <i>M. masseter and temporal</i>	part 2 of <i>M. temporalis</i>	<i>M. adductor mandibulae externus profundus</i>	<i>M. adductor mandibulae externus (part)</i>	<i>M. capiti mandibularis medius and 2nd part of M.cm.s.</i>	<i>M. adductor mandibulae externus profundus</i>	<i>M. adductor mandibulae externus profundus</i>
<i>M. adductor mandibulae posterior</i>	part of <i>M. temporal</i>	part of <i>M. temporalis</i>	+	<i>M. adductor mandibulae medius (part)</i>	<i>M. pterygoideus posterior (part M)</i>	+	+
<i>M. pseudotemporalis superficialis</i>	part of <i>M. temporal</i>	<i>M. sphenomaxillaris</i>	+	<i>M. adductor mandibulae medius (part)</i>	<i>M. pterygoideus posterior</i>	part of <i>M. pseudotemporalis</i>	+
<i>M. pseudotemporalis profundus</i>	part of <i>M. pterygoideus externus</i>	<i>M. quadrato maxillaris</i>	+	<i>M. adductor mandibulae medius (part)</i>	<i>M. pterygoideus posterior (part)</i>	<i>M. quadrati mandibularis</i>	+
<i>M. protractor quadrati and M. protractor pterygoidei</i>	part of <i>M. entiotympanicus</i>	parts 4a and 4b of <i>M. temporalis</i> and <i>M. orbito-quadratus</i>	<i>M. protractor quadrati and M. pterygoideus sensu strictu</i>	<i>M. sphenopterygo quadratus</i>	-	+	+
<i>M. pterygoideus ventralis medialis</i>	part of <i>M. pterygoideus internus</i>	part of <i>M. pterygoidei</i>	+	<i>M. adductor mandibulae internus (part)</i>	part of <i>M. pterygoideus anterior</i>	+	<i>M. ventralis anterior</i>
<i>M. pterygoideus ventralis lateralis</i>	part of <i>M. pterygoideus internus</i>	part of <i>M. pterygoidei</i>	+	<i>M. adductor mandibulae internus (part)</i>	part of <i>M. pterygoideus ventralis anterior</i>	<i>dorsalis lateralis</i>	+ et <i>M. ventralis posterior</i>
<i>M. pterygoideus dorsalis lateralis</i>	part of <i>M. pterygoideus internus</i>	part of <i>M. pterygoidei</i>	+	<i>M. adductor mandibulae internus (part)</i>	-	+	-
<i>M. pterygoideus dorsalis medialis</i>	part of <i>M. pterygoideus internus</i>	part of <i>M. pterygoidei</i>	+	<i>M. adductor mandibulae internus (part)</i>	part of <i>M. pterygoideus dorsalis anterior and posterior</i>	+	<i>M. dorsalis anterior and posterior</i>
<i>M. depressor mandibulae</i>	+	+	-	-	-	+	+

Present Paper	STARCK & BARNIKOL (1954)	BAMS (1956)	ZUSI (1962)	MERZ (1963)	BURTON (1974a)	ZWEERS (1974)
<i>M. adductor mandibulae externus rostralis temporalis</i>	portion ap. 1 (of the <i>M.a.m.e.s.</i>)	<i>M. adductor mandibulae externus</i> and posterior	part M and part A dorsal portion of the <i>M. adductor mandibulae externus</i>	<i>M. adductor mandibulae externus superficialis</i>	part M external temporal	<i>M. adductor mandibulae externus, pars caudolateralis</i>
<i>M. adductor mandibulae externus rostralis medialis</i>	-	-	-	-	part M rostral portion	<i>M. adductor mandibulae externus, pars rostromedialis</i>
<i>M. adductor mandibulae externus rostralis lateralis</i>	-	-	-	-	part A rostral portion	-
<i>M. adductor mandibulae externus ventralis</i>	portion ap. 2 <i>M. adductor mandibulae externus superficialis</i>	<i>M. adductor mandibulae externus</i> and posterior	part A, ventral portion of <i>M. adductor mandibulae externus</i>	<i>M. adductor mandibulae externus medialis</i>	part A of <i>M. adductor mandibulae externus, ventral portion</i>	<i>M. adductor mandibulae externus, pars rostromedialis</i>
<i>M. adductor mandibulae externus caudalis</i>	portion ap. 3 <i>M. adductor mandibulae externus superficialis</i>	<i>M. adductor mandibulae externus</i> and posterior	part B, ventral portion of <i>M. adductor mandibulae externus</i>	<i>M. adductor mandibulae externus profundus</i>	part B of <i>M. adductor mandibulae externus</i>	<i>M. adductor mandibulae externus profundus</i>
<i>M. adductor mandibulae posterior</i>	+	<i>M. adductor externus profundus, caudal part</i>	+	+	+	+
<i>M. pseudotemporalis superficialis</i>	+	<i>M. adductor mandibulae internus</i> and <i>pseudotemporalis</i>	+	+	+	+
<i>M. pseudotemporalis profundus</i>	+	<i>M. adductor mandibulae externus profundus, rostral part</i>	+	+	+	+
<i>M. protractor quadrati</i> and <i>M. protractor pterygoidei</i>	+	<i>M. protractor quadrati</i> et <i>pterygoidei</i>	<i>M. protractor quadrati</i>	+	+	+
<i>M. pterygoideus ventralis medialis</i>	<i>M. pterygoideus ventralis lateralis</i> (part) and <i>ventralis medialis</i>	<i>M. adductor mandibulae internus pterygoideus, ventromedial portion</i>	part N of <i>M. pterygoideus</i>	+	part N of <i>M. pterygoideus</i>	+
<i>M. pterygoideus ventralis lateralis</i>	<i>M. dorsalis lateralis</i> and <i>M. ventralis lateralis</i>	<i>M.a.m.i.p., ventro and dorsolateral portions</i>	part M of <i>M. pterygoideus</i> and <i>dorsalis lateralis</i>	+	part N of <i>M. pterygoideus</i> and <i>dorsalis lateralis</i>	+
<i>M. pterygoideus dorsalis lateralis</i>	-	-	part O of <i>M. pterygoideus</i>	+	part O of <i>M. pterygoideus</i>	+
<i>M. pterygoideus dorsalis medialis</i>	<i>M. dorsalis medialis</i>	<i>M.a.m.i.p., dorsalis</i>	part O of <i>M. pterygoideus</i>	+	part O of <i>M. pterygoideus</i>	+
<i>M. depressor mandibulae</i>	-	-	+	+	+	+

PRESENT PAPER	HÖFLING & GASC (1984)	BURTON (1984)	ZUSI (1984)	GENNIP (1986)
<i>M. adductor mandibulae externus rostralis temporalis</i>	<i>M. adductor mandibulae externus superficialis</i>	+	+	<i>M. adductor mandibulae externus superficialis</i>
<i>M. adductor mandibulae externus rostralis medialis</i>	-	+	+	<i>M. adductor mandibulae externus superficialis, orbital portion</i>
<i>M. adductor mandibulae externus rostralis lateralis</i>	-	+	+	-
			(absent in some species)	
<i>M. adductor mandibulae externus ventralis</i>	<i>M. adductor mandibulae externus medialis</i>	<i>M. adductor mandibulae externus ventralis</i>	<i>M. adductor mandibulae externus, pars ventralis</i>	<i>M. adductor mandibulae externus medialis</i>
<i>M. adductor mandibulae externus caudalis</i>	<i>M. adductor mandibulae externus profundus</i>	<i>M. adductor mandibulae externus caudalis</i>	-	<i>M. adductor mandibulae externus profundus</i>
<i>M. adductor mandibulae posterior</i>	+	∓	<i>M. adductor mandibulae caudalis</i>	+
<i>M. pseudotemporalis superficialis</i>	+	+	+	+
<i>M. pseudotemporalis profundus</i>	+	+	+	+
<i>M. protractor quadrati and M. protractor pterygoidei</i>	<i>M. protractor quadrati</i>	+	+	<i>M. protractor quadrati et pterygoidei</i>
<i>M. pterygoideus ventralis medialis</i>	+	+	+	+
<i>M. pterygoideus ventralis lateralis</i>	+	+	+	+
<i>M. pterygoideus dorsalis lateralis</i>	+	+	+	<i>M. pterygoideus pars dorsalis rostralis</i>
<i>M. pterygoideus dorsalis medialis</i>	+	+	-	<i>M. pterygoideus pars dorsalis caudalis</i>
<i>M. depressor mandibulae</i>	+	+	+	+

Captions:

ap: aponeurosis

M: *Musculus*

M. a.m.e.s.: *Musculus adductor mandibulae externus superficialis*

M.a.m.i.p.: *Musculus adductor mandibulae internus pterygoideus*

M.cm.s.: *Musculus capiti mandibularis superficialis*

+: same nomenclature of the present paper

-: not described/not comparable

M. pseudotemporalis profundus and *M. adductor mandibulae posterior* as a single unit, *M. quadratomandibularis*. Burton (1984) subdivided this muscle into two distinct parts according to the origin: *M. protractor 1* which originates at the caudal portion of the interorbital septum; and *M. protractor 2* which originates at the ventromedial wall of the orbit.

However, this structure was not the same in the case of the woodpeckers: it was clearly observed that there are two distinct protractor muscles: *M. protractor pterygoidei* (treated elsewhere as *M. protractor pterygoidei sensu strictu*) and *M. protractor quadrati*. The first originates as fleshy fibers at the rostral portion of the interorbital septum; the second has two independent points of origin - although near to each other - in *C. rubricollis*, *C. flavescens*, *G. olivaceus* and *M. griseocephalus*. Other authors also consider them as two distinct muscles (Hofer, 1950; Starck & Barnikol, 1954; Merz, 1963; Zusi & Storer, 1969; Richards & Bock, 1973; Burton, 1974a and Zweers, 1974).

Among the woodpeckers studied, the *M. protractor pterygoidei* is not well-developed in *D. fuscescens* and *J. ruficollis*; the differences observed in *M. protractor quadrati* are not related to the development of its fleshy fibers but to the points of origin and insertion: both are fleshy in all species except in *C. rubricollis* and in *G. olivaceus*.

The pterygoid system shows a great structural diversity not only among different groups of birds, but also within the same group. Rooth (1953), Merz (1963) and Gennip (1986) described this diversity in the Columbidae. This could be noticed relatively among the woodpeckers studied. In the *M. pterygoideus ventralis medialis* at least one aponeurosis of origin can be observed in four species; although the other points of origin are fleshy in three species, two aponeurotic portions of this muscle were noticed. Only in *J. ruficollis* were two fleshy points of origin seen. In *M. pterygoideus ventralis lateralis* of *M. cruentatus* and *M. griseocephalus* it was described as a short portion inserted on the laterocaudal surface of the mandible in addition to its common fleshy insertion at the caudomedial surface of the mandible. Burton (1984) described this structure as a "moderately developed venter externus". In *J. ruficollis* the ori-

gin is fleshy. The aponeuroses of insertion XV and XVI of the *M. pterygoideus dorsalis lateralis* in *J. ruficollis* are connected to each other before their insertion at the mandible.

Thus, in addition to the diversity among the species of woodpeckers studied it seems that *J. ruficollis* has many characteristics which are distinct from the main pattern found in the pterygoid system of woodpeckers. Goodge (1972) also observed that the Jynginae, among other groups of woodpeckers, is very different in terms of limb musculature.

The only muscle responsible for the depression of the jaw is very conservative in the woodpeckers studied, in the others Piciformes, and also in a large part of the Coraciiformes (Burton, 1984). Different levels of development were observed in several species; in general, those with greater skull development also had better development of this muscle. Its function in relation to cranial kinesis, was very well investigated by Zusi (1967). He showed that the association between this muscle and the postorbital ligament is definite and efficient in separating the jaws; and that the protraction of the upper jaw was less efficient after the removal of this ligament.

C. Ligaments and tongue

The functions of the jaw ligaments are very well described and discussed by Bock (1964).

The epibranchials can extend to the nasal region and the nostril depending on the species (Alabarce, 1981). Wallace (1974) observed individual variations in the extensions of the epibranchials, whereas Alabarce (*op. cit.*) described the same aspect in relation to the number and disposition of the spines of the entoglossum. These variations can also be observed among woodpeckers.

ACKNOWLEDGMENTS

I am much indebted to my adviser, Dr. E. Höfling, for her secure orientation, patience and helpful advise. I am also much indebted to Museu Paraense Emilio Goeldi (MPEG), Pará, Brazil, in the name of Dr. F.C. Novaes and to Transvaal Museum (TM), Pretoria, Republic of South Af-

rica, in the name of Dr. A. Kemp and Mrs. T. Cassidy, for the loan of the Neotropical and Afrotropical species, respectively, without which this study would not be possible. I wish to thank France for her help with the illustrations. Financial support came from the Conselho Nacional de Desenvolvimento Científico e Tecnológico (CNPq - nº 840255/88-8).

REFERENCES

- Alabarce, E.A. 1981. Estudio comparativo de la porción superior del tracto digestivo y alimentación de los picidos de la provincia de Tucuman. *Acta Zool. Lilloana*, Tucuman, 36 (2): 129-137.
- Bans, R.A. 1956. On the relation between the attachment of the jaw muscles on the surface of the skull in *Podiceps cristatus* L., with some notes on the mechanical properties of this part of the head. *Proc. K. Akad. Wet.*, Amsterdam, 59 (1/2): 82-101.
- Baumel, J., King, A.S. Lucas, A.M. Breazile, J.E. & Evans, H.E. 1979. *Nomina Anatomica Avium*. London, Academic Press. 637p.
- Beecher, W.J. 1951 Adaptations for food-getting in the American Blackbirds. *Auk*, Washington, 68 (1): 51-86.
- Beecher, W.J. 1953. Feeding adaptations and systematics in the avian order Piciformes. *J. Wash. Acad. Sci.*, Washington, 43: 293-299.
- Berger, A.J. 1966. The musculature. In: eds. Avian Biology. George J.G.; Berger A.J.. New York, Academic Press.
- Bock, W.J. 1960. Secondary articulation of the avian mandible. *Auk*, Washington, 77 (1): 19-55.
- Bock, W.J. 1964. Kinetics of the avian skull. *J. Morphol.* Philadelphia, 114 (1): 1-52.
- Bock, W.J. 1966. An approach to the functional analysis of bill shape. *Auk*, Washington, 83 (1): 10-51.
- Bock, W.J., & Miller, W.W. 1959. The scansorial foot on the woodpeckers, with comments on the evolution of perching and climbing feet in birds. *Am. Mus. Novit.*, New York, (1931): 1-45.
- Bock, W.J., & Morioka, H. 1971. Morphology and evolution of the ectethmoid mandibular articulation in the Meliphagidae (Aves). *J. Morphol.*, Philadelphia, 135 (1): 13-50.
- Bühler, P. 1970. Schädelmorphologie und kiefermechanik der Caprimulgidae (Aves). *Z. Morphol. Tiere*, Berlin, 66(4): 337-399.
- Bühler, P. 1981. Functional anatomy of the avian jaw apparatus. In: *Form and Function in Birds*. King, A.S.; McLleland, J. eds. London, Academic Press. 2v.
- Burger, A.E. 1978. Functional anatomy of the feeding apparatus of four South African cormorans. *Zool. Afr.*, Pretoria, 13 (1): 81-102.
- Burt, W.H. 1930. Adaptive modifications in the woodpeckers. *Univ. Calif. Publ. Zool.*, Berkeley, 32 (8): 455-524.
- Burton, P.J.K. 1974a. Feeding and the feeding apparatus in waders. *Bull. Br. Mus. Nat. Hist.*, London, (719): 1-150.
- Burton, P.J.K. 1974b. Anatomy of the head and neck in the Huia (*Heteralocha acutirostris*) with comparative notes on other Callaeidae. *Bull. Br. Mus. Nat. Hist. Zool.* London, 27: 1-48.
- Burton, P.J.K. 1974c. Jaw and tongue features in Psittaciformes and other orders with special reference to the anatomy of the Toothbilled Pigeon (*Didunculus strigirostris*). *J. Zool. Res.*, London, 174: 255-276.
- Burton, P.J.K. 1977. Lower jaw action during prey capture by pelicans. *Auk*, Washington, 94 (4): 785-786.
- Burton, P.J.K. 1984. Anatomy and evolution of the feeding apparatus in the avian orders Coraciiformes and Piciformes. *Bull. Br. Mus. Nat. Hist. Zool.* London, 47: 331-443.
- Davids, J.A.G. 1952. Étude sur les attaches du crâne des muscles de la tête et du cou chez *Anas p. platyrhynca* (L.). *Proc. K. Ned. Akad. Wet.*, Amsterdam, 55 (1,3/4): 81-94; 525-533; 534-540.
- Donatelli, R.J. 1992. Cranial osteology and myology of the jaw apparatus in the Galbulidae (Aves Piciformes). *Arq. Zool.*, São Paulo, 32 (1): 1-32.
- Garrod, A.H. 1872. Notes on some of the cranial peculiarities of the woodpeckers. *Ibis*, London, p. 357-360.
- Gennip, E.M.S.J. van 1986. The osteology, arthrology and myology of the jaw apparatus of the Pigeon (*Columba livia* L.). *Neth. J. Zool. Wageningen*, 36 (1): 1-46.
- Goodge, W.R. 1972. Anatomical evidence for phylogenetic relationships among woodpeckers. *Auk*, Washington, 89 (1): 65-85.
- Goodwin, D. 1968. Notes on woodpeckers (Picidae). *Bull. Br. Mus. Nat. Hist. Zool.*, London, 17 (1): 1-44.
- Hofër, H. 1945. Untersuchungen über den Bau des Vogelschädels besonders über den der Spechte und Steinhühner. *Zool. Jahrb. Anat. Ont. Tiere*, Jena, 69 (1): 1-158.
- Hofër, H. 1950. Zur Morphologie der Keifermuskulatur der Vogel. *Zool. Jahrb. Anat. Ont. Tiere*, Jena, 70 (1): 427-600.
- Höfling, E., Gasc, J.P. 1984. Biomécanique du crâne et du bec chez Ramphastos (Aves, Ramphastidae). *Gegenbaurs Morphol. Jahrb.*, Leipzig, 130 (1): 125-147.
- Jenni, L. 1981. Das Skelettmuskelsystem des Halses von Buntspecht und Mittelspecht *Dendrocopus major* und *medius*. *J. Ornithol.*, Leipzig, 122 (1): 37-63.
- Jollie, M. 1957. The head skeleton of the chicken and remarks on the anatomy of this region in other birds. *J. Morphol.*, Philadelphia, 100 (4): 389-436.
- Kirby, V.C. 1980. An adaptive modification in the ribs of woodpeckers and piculets (Picidae). *Auk*, Washington, 97 (3): 521-532.
- Lakjer, T. 1926. *Studien über die Trigeminierversorgte Kaumuskulatur der Sauropsiden*. Kopenhagen, C. A. Reitzel Buchlandlung. 154p.
- Merz, R.L. 1963. Jaw musculature of the Mourning and White-winged Doves. *Univ. Kans. Publ. Mus. Nat. Hist.*, Lawrence, 12: 521-551.
- Parker, W.K. 1875. On the morphology of the skull in the woodpeckers (Picidae) and wrynecks (Jyngidae). *Trans. Linn. Soc. Lond.*, London, 1: 1-22.
- Peters, J.L. 1948. *Check-list of the birds of the world*. Cambridge, Harvard University Press. 6.
- Raikow, R.J. 1987. Hindlimb myology and evolution of the old world suboscine passerine birds (Acanthisitidae, Pittidae, Philipittidae, Eurylaimidae). *Ornithol. Monogr.*, Washington, 41: 1-81.
- Richards, L.P., & Bock, W.J. 1973. Functional anatomy and adaptive evolution of the feeding apparatus in the Hawaiian Honeycreeper genus *Loxops* (Drepanididae). *Ornithol.*

- Monogr.*, Washington, 15: 1-173.
- Rooth, J. 1953. On the correlation between the jaw muscles and the structure of the skull in *Columba palumbus palumbus* L. *Proc. K. Ned. Acad. Wet.*, Amsterdam, 56: 251-264.
- Scharmke, H. 1930. Physiologisch-anatomische Studien am Füssder Spechte. *J. Ornithol.*, Leipzig, 78 (3): 308-327.
- Short, L.L. 1982. *Woodpeckers of the world*. Greenville, Delaware Museum of Natural History. Monograph Series, (4): 676p.
- Shufeldt, R.W. 1891. On the question of saurognathism of the Pici, and other osteological notes upon that group. *Proc. Zool. Soc. Lond.*, London, 1891: 122-129.
- Simpson, S.F. & Cracraft, J. 1981. The phylogenetic relationships of the Piciformes (Aves). *Auk*, Washington, 98 (3): 481-94
- Sims, R.W. 1955. The morphology of the head of the Hawfinch, *Coccothraustes coccothraustes* with special reference to the myology of the jaw. *Bull. Br. Mus. Nat. Hist. Zool.*, London, 2 (13): 370-393.
- Spring, L.W. 1965. Climbing and pecking adaptations in some North American woodpeckers. *Condor*, Santa Clara, 67 (4): 457-488.
- Starck, D., & Barnikol, A. 1954. Beiträge zur Morphologie der Trigemini-muskulatur der Vogel (besonders der Accipitres, Cathartidae, Striges und Anseres). *Morph. Jahrb.*, Leipzig, 94 (1): 1-64.
- Steinbacher, J. 1934. Untersuchungen über den Zungenapparat Indischer Spechte. *J. Ornithol.*, Leipzig, 82 (4): 399-408.
- Steinbacher, J. 1935. Ueber den Zungenapparat Sudafricanischer Spechte. *Ornithol. Monatsber.*, Berlin, 43 (3): 85-89.
- Steinbacher, J. 1955. Zur Morphologie und Anatomie des Zungenapparates Brasilianischer Spechte. *Senckenb. Biol.*, Frankfurt, 36 (1/2): 1-8.
- Swierczewisky, E.V. & Raikow, R.J. 1981. Himp limb morphology, phylogeny and classification of the Piciformes. *Auk*, Washington, 98 (3): 466-80.
- Wallace, R. 1974. Aberrations in the tongue structure of some melanerpine woodpeckers. *Wilson Bull.*, Oberlin, 86 (1): 79-82.
- Zusi, R.L. 1962. Structural adaptations of the head and neck in the Black-skimmer *Rhynchops nigra*. Cambridge, Mass., Nuttall Ornithol. Club. 101p. Publication, 3.
- Zusi, R.L. 1967. The role of the depressor mandible muscle in kinesis of the avian skull. *Proc. U.S. Nat. Hist.*, Washington, 123: 1-28.
- Zusi, R.L. & Storer, R.W. 1969. Osteology and myology of the head and neck of the Pied-billed Grebes (*Podilymbus*). *Misc. Publ. Mus. Zool. Univ. Mich.*, Michigan, 139: 1-49.
- Zweers, G.A. 1974. Structure, movement and myography of the feeding apparatus of the Mallard (*Anas platyrhynchos* L.). A study in functional anatomy. *Neth. J. Zool.*, Wageningen, 24 (4): 323-467.