

Trabecular trichoblastoma in a domestic cat (*Felis catus domesticus*, Linnaeus 1758): Case report

Tricoblastoma trabecular em gato doméstico (Felis catus domesticus, Linnaeus 1758): Relato de caso

Thaís Fercher de Freitas¹; Siria da Fonseca Jorge¹ ; Maria Eduarda Monteiro Silva¹; Fernando Luis Fernandes Mendes¹; Tatiana Didonet Lemos¹

¹ Faculdade de Medicina Veterinária – UNIFESO, Teresópolis - RJ, Brazil

ABSTRACT

Trichoblastoma is characterized as a benign cutaneous neoplasm that originates in the trichoblastic epithelium of the hair bulb. The present report describes the case of a 4-year-old cross breed neutered male cat that had a history of a slow, freely movable, ulcerated, slow growing, solitary cutaneous nodule located on the left scapular region. Histopathological evaluation showed neoplastic cells arranged in cohesive nests or palisades with eosinophilic and scant cytoplasm. Based on the microscopic findings, a diagnosis of trabecular trichoblastoma was made. The treatment of choice consisted of total surgical excision of the mass with safe surgical margins. Tumor recurrence was not observed.

Keywords: Hair follicle. Neoplasia. Histopathology. Surgery. Feline.

RESUMO

O Tricoblastoma se caracteriza como uma neoplasia benigna cutânea que tem origem no epitélio tricoblástico do bulbo piloso. O presente relato descreve o caso de felino macho, sem raça definida (SRD), com histórico de nódulo solitário de crescimento lento, não aderido e ulcerado, localizado na região escapular esquerda. A histopatologia evidenciou células neoplásicas organizadas em ninhos coesos, em paliçadas com citoplasma eosinofílico e escasso, os achados foram compatíveis com a descrição de tricoblastoma trabecular. O tratamento de eleição consistiu na exérese cirúrgica total da massa com ampla margem de segurança e recidivas não foram observadas.

Palavras-chave: Folículo piloso. Neoplasia. Histopatologia. Cirurgia. Felino.

Correspondence to:

Siria da Fonseca Jorge
Centro Universitário Serra dos Órgãos, Faculdade de Medicina Veterinária
Estrada Wenceslau José de Medeiros, 1045, Prata
CEP: 25976-345, Teresópolis – RJ, Brazil
e-mail: siriavet@gmail.com

Submitted: September 10, 2018

Approved: August 26, 2019

How to cite: Freitas TF, Jorge SF, Silva MEM, Mendes FLE, Lemos TD. Trabecular trichoblastoma in a domestic cat (*Felis catus domesticus*, Linnaeus 1758): Case report. Braz J Vet Res Anim Sci. 2019;56(3):e150213. <https://doi.org/10.11606/issn.1678-4456.bjvras.2019.150213>

The skin is a vast organ that performs multiple functions. Factors such as exposure to the external environment and ability to regenerate frequently make the integumentary system especially susceptible to constant changes which predispose the skin to the development of different types of neoplasms (Ronaldo, 2008).

The dermis is composed of connective tissue, mainly composed of intertwined collagen fibers, dermal cellular elements, and epidermal appendages, i.e. hair follicles and adnexal glands (Conceição & Loures, 2016).

The hair follicles are epidermal tubular invaginations within the dermis which provide support to the intradermal segment of the hair stalk. The hair follicle is divided into three distinct zones: infundibulum (which extends from the surface of the epidermis to the opening of the sebaceous

glands open onto the skin surface), isthmus (which goes from the sebaceous glands until the insertion of the piloerector muscle), and bulb (which extends from the insertion of the piloerector muscle to the dermal papilla). This papilla plays a key role in nourishing the lower segment of the hair follicle and is also involved in the differentiation and proliferation of epithelial cells (Pinho et al., 2013).

Trichoblastoma is a cutaneous neoplasm formerly classified as a basal cell tumor which is a categorical term that encompasses several morphologically distinct skin tumors, all of which supposedly derive from basal cells of the epidermis and from hair follicles as well. However, they differ from one another in terms of pattern of growth and degree of differentiation (Conceição & Loures, 2016).

Trichoblastoma is a benign neoplasm derived from germinal cells of the hair follicle and presents a distinct growth pattern which differs from the solid and cystic types. However, occasionally it may exhibit microscopic features of both types (Conceição & Loures, 2016). According to Goldschmidt & Goldschmidt (2016), this neoplasm usually consists of an exophytic mass that may range between 0.5 cm to 18 cm in diameter. Most of these tumors extend from the epidermal-dermal interface in the dermis and subcutaneous tissue and are well-demarcated from the surrounding tissue by a pseudocapsule of compressed collagen. The overlying epidermis lack hairs and may exhibit secondary ulceration. In cats, trichoblastomas are firm and solitary nodules usually less than 2 cm in diameter (Gross et al., 2005). They are more frequent in the head and cranial half of the trunk (Gross et al., 2005).

Trichoblastoma subtypes can be recognized histologically, including cordonal (ribbon), medusoid trabecular, spindle cell, and granular cell patterns/types (Conceição & Loures, 2016). However, the prognosis for this benign tumor is good, regardless of subtype classification (Goldschmidt & Goldschmidt, 2016). Surgery is considered the most effective treatment for trichoblastomas. Recurrences have been rarely reported (Campos et al., 2014). Post-operative recurrence of the neoplasm may occur if the surgical excision of the tumor is incomplete (Conceição & Loures, 2016).

Hair follicular neoplasms are rarely reported in cats (less than 1%) and represent approximately 5% of the total number of cutaneous neoplasms diagnosed in dogs (Withrow & Vail, 2006).

The present report aimed to describe the clinical, gross, and microscopic aspects of a case of trabecular trichoblastoma in a 4-year-old male cat. Information on behavior, occurrence, prevalence, therapy and prognosis of this neoplasm is scarce the veterinary literature.

A 4-year-old, mixed breed male neutered cat with a round tumor mass with approximately 4 cm in diameter located in the scapular region of the left forelimb (Figure 1), was presented to the teaching hospital of the School of Veterinary Medicine of UNIFESO - Serra dos Órgãos University Center - located in the city of Teresópolis, State of Rio de Janeiro (RJ), southeast Brazil.

The cat had a 4-month history of a progressively growing mass on the scapular region with occasional bleeding. No physical or behavioral changes were noted. At physical examination, the animal presented a body temperature of 38.4 °C, normal mucous membrane color and no dehydration. The mass was ulcerated, well-circumscribed, firm, freely mobile-and painless.

The cytological exam showed uniform polyhedral cells extremely agglomerated, such arrangement made it difficult to assess the correlation between the nucleus and cytoplasm (N:C ratio), presence of basophilic amorphous substance and mild pleomorfis. No typical microscopic features of any particular type of tumor were observed in the samples examined, the diagnosis was inconclusive.

The tumor mass was surgically removed twenty days after cytological exam. The anesthetic premedication was done with Tramadol hydrochloride (3 mg/kg, subcutaneous), Midazolam (0.25 mg/kg, intramuscular) and Ketamine (5 mg/kg intramuscular). Venous access was performed, and Propofol (2.5 mg/kg) was used for induction. After intubation, anesthetic maintenance was established with Isoflurane and oxygen in a semi-open Baraka circuit. The incision was performed in horizontal ellipse around the neoplastic mass with a safety surgical margin of approximately 0.5 cm Tumor adhesions were not observed during the surgical procedure. The subcutaneous tissue was suture with absorbable, synthetic, multifilament, 3-0 polyglycolic acid

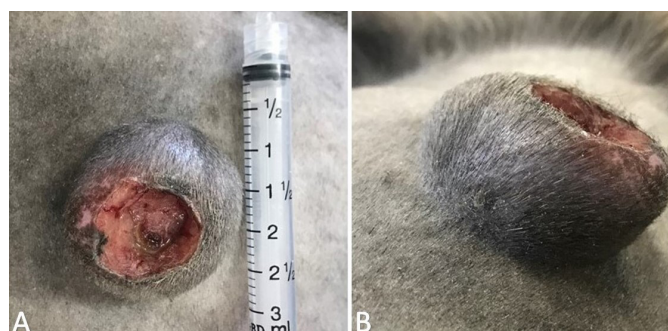

Figure 1 – Well-circumscribed mass located on the left scapular region, well-defined margins and presence of ulceration at the center. (A) The size of the cutaneous mass was determined by measuring the neoplasm with the scale (calibration markings) printed on the barrel of a 3 ml syringe. (B) Lateral views of the neoplastic nodule.

suture material with a simple continuous suture pattern. The intradermal suture was done with nylon 2.0 suture material. The excised tumor was fixed in 10% formalin, and submitted for histopathological analysis. Postoperative antibiotic therapy with amoxicillin with potassium clavulanate (25 mg/kg), twice a day was carried out for 10 days and non-steroidal anti-inflammatory ketoprofen (1 mg/kg), once a day, for 5 days. An Elizabethan collar and disinfection of the area with 70% alcohol were suggested after surgery.

Grossly, this was an ulcerated, soft, whitish cutaneous nodule measuring 4.0 cm × 3.5 cm × 2.0 cm. Microscopically, the skin mass was characterized by a well-circumscribed, expansive, encapsulated, densely cellular neoplasm formed by basal cells arranged in cohesive nests. Neoplastic cells were polyhedral, small and had indistinct margins. The cytoplasm of these tumor cells was eosinophilic and scanty. Nuclei were centrally located, rounded, and with dense chromatin. N:C ratio was 3:1. Neoplastic cells had a single, evident, distinct nucleolus. Mild anisocytosis and anisokaryosis, and rare mitotic figures in 10 fields of higher magnification (40X) were also observed. All surgical margins of the skin were devoid of neoplastic cells. According with histopathological findings it was concluded trichoblastoma.

The trichoblastoma reported in the present case was located in the cranial half of the body, in the scapular and middle regions, and had approximately 4 cm in diameter. Our findings corroborate those of and Sharif & Reinacher (2006), Grandi & Rondelli (2017) that report the occurrence of these cutaneous neoplastic lesions on the head, neck, and base of the ear and Gross et al. (2005) that describe the presence of this skin tumor on the cranial half of the body of dogs and cats. Magana et al. (2013) describe these cutaneous neoplasms as isolated, round or oval, firm, alopecic nodules which are usually melanocytic and symmetrical, have smooth and well-defined margins, and may be ulcerated and hyperpigmented. These characteristics reported by other authors in previous reports published elsewhere are consistent with the gross aspect of the tumor described in this case report. Alopecia and secondary ulceration were observed in the present case. These features are also described in the literature (Goldschmidt & Goldschmidt, 2016). The patient age was similar those reported by Campos et al. (2014) and Conceição & Loures, (2016) which reports that trichoblastomas may affect animals between 6 and 9 years of age.

Fine needle aspiration cytology (FNAC) is a reliable, rapid, and cost-effective screening and diagnostic tool. However, FNAC was inconclusive in our case. Adedeji et al. (2017) describe the predominance of small, uniform, and

agglomerated basal epithelial cells in cases of trichoblastoma of dogs. Cytologic findings in our case included high nucleus-to-cytoplasm ratio, presence of predominantly monomorphic nuclei, and neoplastic cells with basophilic cytoplasm. Similar findings are reported by Santos et al. (2016) in a case of trichoblastoma of a dog. In the present case, tumor cells arranged in clusters were seen in the cytologic preparations. However, the difficulty in visualizing the nuclei of these cells precluded the diagnosis of the neoplasm on cytologic samples. In our case, a definitive diagnosis of trichoblastoma was achieved via histopathology.

Histopathological findings in our case included small polyhedral cells with scant, eosinophilic cytoplasm and ovoid nucleus. Our findings are in accordance with those of Emanuelli & Bohn (2014). The neoplasm was densely cellular, well-circumscribed, expansive, encapsulated, and formed by basal cells arranged in cohesive nests. Neoplastic cell nests separated by connective tissue trabeculae with prominent peripheral palisade cells characterize trabecular trichoblastoma as stated by Mauldin & Kennedy (2015). These authors describe the histopathological findings of trabecular trichoblastoma as multiple lobes of neoplastic cells surrounded by an interlobular collagenous stroma. Abramo (1998) indicates the presence of islands of cells forming palisades in the periphery of the tumor as a typical feature of this particular subtype in cats.

More than one tumor subtype may be present and coexist in the same neoplasm as reported by Sawale et al. (2015) and Mineshige et al. (2014). The most common subtypes of trichoblastoma in dogs are granular and ribbon types whereas the trabecular and fusiform patterns are the ones most frequently diagnosed in cats (Goldschmidt & Goldschmidt, 2016; Mauldin & Kennedy, 2015). In the present case report, trabecular trichoblastoma was diagnosed by histopathology.

The treatment of choice of trichoblastoma is total surgical excision with safety margins ranging between 1 and 2 cm (Campos et al., 2014; Grandi & Rondelli, 2017). The safety surgical used in the patient from the present case report was 0.5 cm, because the mass had well-defined margins and was not adherent to deep structures. The surgical margins were devoid of tumor cells as evidenced by histopathology. In most of the cases prognosis after surgical excision of the cutaneous neoplastic mass is excellent (Conceição & Loures, 2016). There were no postoperative tumor recurrence within 18 months of the surgical excision of the skin mass.

The histopathological examination was conclusive for trichoblastoma (Figure 2). This observation emphasizes the importance of this ancillary test in order to reach a final,

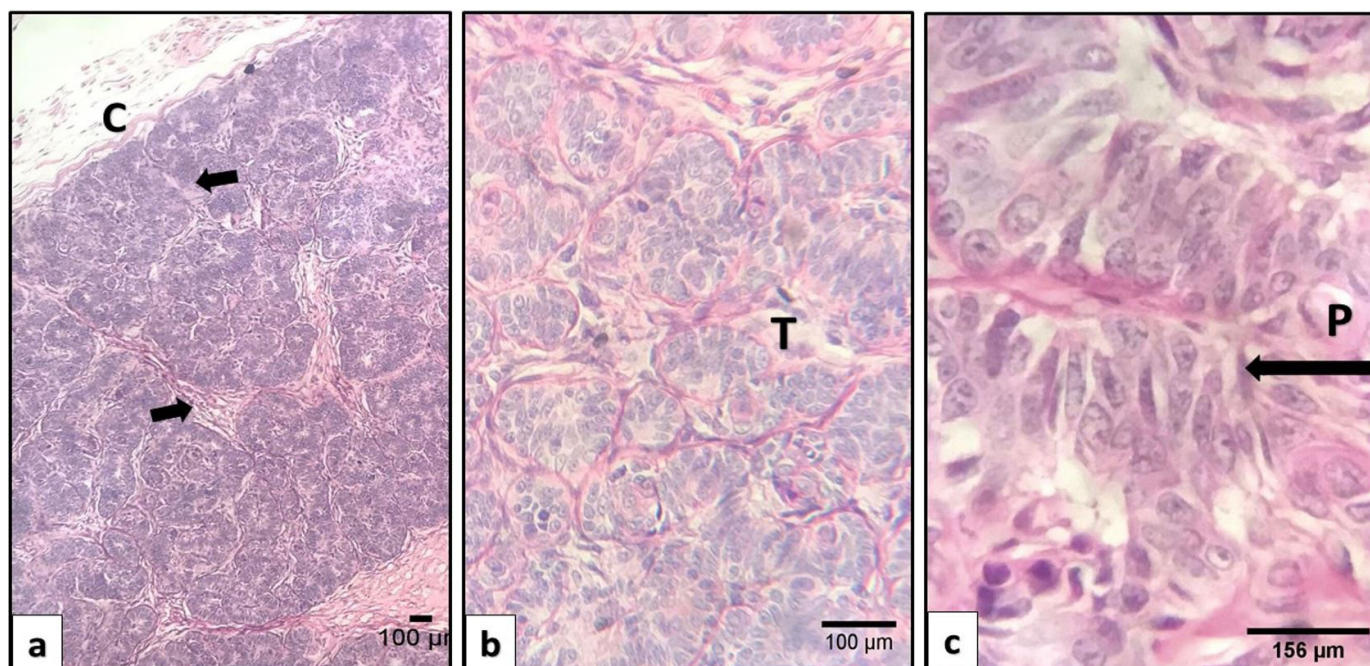


Figure 2 – Photomicrograph: Feline. Trichoblastoma. (a) Note the presence of a capsule (C) surrounding the neoplasm, the arrows indicates branching trabecular of tumor cells HE (40X). (b) Nests of neoplastic cells separated by trabeculae of connective tissue (T) HE (400X). (c) Presence of prominent palisade cells (P) at the periphery of the tumor, characterizing the cellular distinction of the neoplasm (arrow) HE (1000X).

definitive diagnosis, to assess the safety surgical margins in order to rule in or rule out the presence of tumor cells, and to differentiate between the different subtypes of this cutaneous neoplasm in the feline species.

The relevance and usefulness of this case report in the field of veterinary oncology should be emphasized as this particular type of follicular tumor is rarely diagnosed in cats in clinical practice. Misdiagnosis of basal cell tumors and lack of interest to pursue a histopathological diagnosis possibly account for the small number of cases of feline trichoblastoma diagnosed in clinical practice.

Subtype classification is a significant factor for understanding the general aspects of the tumor. According to the veterinary literature, there is a higher prevalence of some subtypes of this cutaneous neoplasm in dogs and cats. Our case has a number of features including occurrence, location, biological behavior, treatment and prognosis which are similar to the ones reported in dogs. There is scant literature on this particular hair follicle

tumor in the feline species which hampers a comparison between trichoblastomas of dogs and trichoblastomas of cats. Histopathological evaluation of skin masses in cats is essential to reach a definitive diagnosis of trichoblastoma. This report adds to the existing literature on the subject by describing the clinical, pathological and therapeutic aspects of a case of trichoblastoma in a cat.

Conflict of interest

There are no declared conflicts of interest

Ethics Statement

All authors have been personally and actively involved in the article, and are jointly and individually responsible for their content. Since this manuscript is a clinical case report and the therapeutic approach described is based on the literature, it was not necessary the approve of the animal ethics committee.

REFERENCES

Abramo F. Tumors and pseudotumors of the hair follicle. Pisa: Quaderni di Dermatology; 1998.

Adedeji AO, Affolter VK, Christopher MM. Cytologic features of cutaneous follicular tumors and cysts in dogs. *Vet*

Clin Pathol. 2017;46(1):143-50. <http://dx.doi.org/10.1111/vcp.12458>. PMID:28249100.

Campos AG, Cogliati B, Guerra JM, Matera JM. Multiple trichoblastomas in a dog. *Vet Dermatol.*

- 2014;25(1):48e19. <http://dx.doi.org/10.1111/vde.12100>. PMID:24461035.
- Conceição LR, Loures FH. The integumentary system. In: Santos RL, Alessi AC. *Veterinary pathology*. 2nd ed. Rio de Janeiro: Roca; 2016. p. 433-434.
- Emanuelli MP, Bohn AA. What is your diagnosis? Dermal mass in a dog. *Vet Clin Pathol*. 2014;43(2):285-6. <http://dx.doi.org/10.1111/vcp.12130>. PMID:24588743.
- Goldschmidt MH, Goldschmidt KH. Epithelial and melanocytic tumors of the skin. In: Meuten DJ. *Tumors in domestic animals*. 5th ed. Iowa: John Wiley & Sons, 2016. p. 101-104. <http://dx.doi.org/10.1002/9781119181200.ch4>.
- Grandi F, Rondelli MCH. Cutaneous neoplasm. In: Daleck CR, Nardi AB. *Oncology for cats and dogs*. 2. ed. Rio de Janeiro: Roca; 2017. p. 359-361.
- Gross TL, Ihrke PJ, Walder EJ, Affolter VR. *Skin diseases of the dog and cat: clinical and histopathology diagnosis*. 2nd ed. Oxford: Blackwell; 2005. <http://dx.doi.org/10.1002/9780470752487>.
- Magana M, Castellanos G, Meurehg C. Trichoblastoma. *Latin American Journal of Pathology*. 2013;5(1):49-55.
- Mauldin EA, Kennedy JP. Integumentary System. In: Maxie MG. *Jubb, Kennedy & Palmer's – Pathology of domestic animals*. 6th ed. Saunders Ltd, 2015. 716 p.
- Mineshige T, Yasuno K, Sugahara G, Tomishita T, Shimokawa N, Kamiie J, Nishifuji K, Shirota K. Trichoblastoma with abundant plump stromal cells in a dog. *J Vet Med Sci*. 2014;76(5):735-9. <http://dx.doi.org/10.1292/jvms.13-0516>. PMID:24430656.
- Pinho R, Monzón MF, Simões J. *Veterinary dermatology in companion animals: (I) the skin and its relevant aspects in clinical practice*. 2013. (Veterinary Dermatology Series; vol. 5; n. 1-2).
- Ronaldo L. Semiology of the skin. In: Feitosa FLF. *Veterinary semiology: the art of diagnosis*. 2nd ed. São Paulo: Roca; 2008.
- Santos IFC, Cardoso JMM, Soares JF, Assis ACG, Reis MG, Gomes MVF, Tannus FCI. Trichoblastoma in young dog (*Canis lupus familiaris*) – First case report in Mozambique, Africa. *Acta Vet. Bras*. 2016;10(4):357-362.
- Sawale GK, Gavhane DS, Mhase AK, Rohi RR, Moregaonkar SD. A case report on trichoblastoma in a Labrador dog. *Indian J Vet Pathol*. 2015;39(4):366-8. <http://dx.doi.org/10.5958/0973-970X.2015.00091.7>.
- Sharif M, Reinacher M. Clear cell trichoblastomas in two dogs. *J Vet Med A Physiol Pathol Clin Med*. 2006;53(7):352-4. <http://dx.doi.org/10.1111/j.1439-0442.2006.00834.x>. PMID:16922832.
- Withrow SJ, Vail DM. *Small animal clinical oncology*. 4th ed. Saunders; 2006. 388 p.

Financial support: None

Authors contributions: Thaís Fercher de Freitas, Siria da Fonseca Jorge, Maria Eduarda Monteiro da Silva, Fernando Luis Fernandes Mendes and Tatiana Didonet Lemos participated in the writing of the article, considering the reading and review stages.