


Morphometry of the mandibular foramen applied to the local anesthetic block to inferior alveolar nerve in boars (*Sus scrofa scrofa* Linnaeus, 1758)

Morfometria do forame mandibular aplicada ao bloqueio anestésico local do nervo alveolar inferior de javalis (Sus scrofa scrofa Linnaeus, 1758)

Caroline Bures de Paulo¹; Henrique Inhauser Riceti Magalhães²; Ygor Henrique de Paula³; Jeferson Borges Barcelos⁴; Fabiano Braz Romão³; Tânia Ribeiro Junqueira Borges³; Frederico Ozanam Carneiro e Silva⁵ 

¹ Instituto Master de Ensino Presidente Antônio Carlos, Faculdade de Medicina Veterinária, Araguari – MG, Brazil

² Universidade de São Paulo, Faculdade de Medicina Veterinária e Zootecnia, Departamento de Cirurgia, São Paulo – SP, Brazil

³ Centro Universitário de Patos de Minas, Grupo de Pesquisa em Anatomia Comparativa, Patos de Minas – MG, Brazil

⁴ Fundação Presidente Antônio Carlos, Faculdade de Medicina Veterinária, Uberlândia – MG, Brazil

⁵ Universidade Federal de Uberlândia, Faculdade de Medicina Veterinária e Zootecnia, Laboratório de Anatomia Animal, Uberlândia – MG, Brazil

ABSTRACT

Boars kept on commercial farms use their canine teeth as a mechanism of defense and attack in order to express their natural instincts, which could result in fractures of the teeth and jaws. Thus, utilizing local desensitization of the inferior alveolar nerve is crucial for executing therapeutic procedures in the oral cavities of those animals. Then, the goal is to carry out the morphometry of the mandibular foramen of that species, correlating it with the mandibular structures, while doing so in the safest manner for the animals. For that purpose, six hemimandibles of young-aged *Sus scrofa scrofa* were used, from which the proposed measurements were taken. On average, the lateral margin of the condylar process stood 142.43 mm away from the root of the lower medial incisive tooth. The longitudinal axis of the body of the mandible measured 22.3 mm at the level of the diastema that exists between the fourth lower premolar tooth and the first lower molar tooth. The mandibular foramen, from the caudal limit of the ventral margin, would be positioned at 26.6 mm from the ventral margin of the angle of the mandible in that level, 34.92 mm away from the medial margin of the condylar process, and 38.63 mm away from the dorsal limit from the caudal margin of the coronoid process. The lack of statistically significant differences, and observing that the osseous accident under scrutiny had been positioned in the ramus of the mandible, indicated that the proposed procedure should be performed from the introduction of the needle in an oblique and rostradorsal direction for 2.0 cm, and angulated at 60° with the anatomic reference created by the medial demarcation obtained via the support of the thumb on the lateral margin of the ramus of the mandible, ventrally to the zygomatic arch, all while preserving neighboring structures and establishing an unheard-of anesthetic methodology for boars.

Keywords: Anesthesia. Mandible. Morphology. Animal dentistry. Suidae.

RESUMO

Javalis mantidos em criatórios comerciais utilizam os dentes caninos como mecanismo de defesa e ataque a fim de expressar seus instintos naturais, o que pode resultar em fraturas dentárias e da mandíbula propriamente dita. Desta forma, propiciar a dessensibilização local do nervo alveolar inferior é essencial para a execução de procedimentos terapêuticos na cavidade oral destes animais. Logo, objetivou-se realizar a morfometria do forame mandibular desta espécie a fim de correlacioná-lo com as estruturas mandibulares, inferindo, também, sobre a forma mais segura de realização da referida técnica nos espécimes. Para tanto, foram utilizadas seis hemimandíbulas de *Sus scrofa scrofa* jovens, a partir das quais foram realizadas as mensurações propostas. Em média, a margem lateral do processo condilar distanciou-se 142,43 mm da raiz do dente incisivo medial inferior; o eixo longitudinal do corpo da mandíbula mediu 22,3 mm ao nível do diastema existente entre o quarto dente pré-molar e o primeiro dente molar inferiores; e o forame mandibular, a partir do extremo caudal de sua margem ventral, posicionou-se a 26,6 mm da margem ventral do ângulo da mandíbula neste nível, 34,92 mm da margem medial do processo condilar, e 38,63 mm do extremo dorsal da margem caudal do

processo coronóide. Na falta de diferenças estatisticamente significantes, e observando que o acidente ósseo estudado posicionou-se no ramo da mandíbula, indica que o procedimento proposto deva ser realizado a partir da introdução da agulha em sentido oblíquo rostroventral por 2,0 cm e angulada a 60° com o referencial anatômico criado pela delimitação medial obtida pelo apoio do dedo polegar na margem lateral do ramo da mandíbula, ventralmente ao arco zigomático, preservando as estruturas próximas e definindo-se uma metodologia anestésica inédita para os Javalis.

Palavras-chave: Anestesia. Mandíbula. Morfologia. Odontologia animal. Suidae.

Correspondence to:

Lucas de Assis Ribeiro
Universidade Federal de Uberlândia, Faculdade de Medicina
Veterinária e Zootecnia, Laboratório de Anatomia Animal
Rua Ceará, s/n, Bloco 2D, Umuarama
CEP: 38400-902, Uberlândia – MG, Brazil
e-mail: lucasassis83@yahoo.com.br

Received: August 29, 2019

Approved: January 07, 2020

How to cite: Paulo CB, Magalhães HIR, Paula YH, Barcelos JB, Romão FB, Borges TRJ, Silva FOC, Ribeiro LA. Morphometry of the mandibular foramen applied to the local anesthetic block to inferior alveolar nerve in boars (*Sus scrofa scrofa* Linnaeus, 1758). *Braz J Vet Res Anim Sci.* 2020;57(1):e161658. <https://doi.org/10.11606/issn.1678-4456.bjvras.2020.161658>

Introduction

The Boar (*Sus scrofa scrofa* Linnaeus, 1758), a mammal native to Eurasia and the Northwest region of Africa, is characterized as one of the oldest species ever purposefully introduced worldwide by humans. Recently, boars inhabit all continents, with the exception of Antarctica, and comprise one of the largest populations in the level of world geographic distribution (Puertas & Passamani, 2016), mostly due to their ecological and biological plasticity (Rosell et al., 2001).

It is believed that the entry of these animals in Brazilian territory took place via the border of the State of Rio Grande do Sul and Uruguay, after a drop in the availability of food due to severe drought in 1989 (Valério, 1999). However, that invasion might also have occurred from the clandestine transportation of specimens for reproductive purposes. From that point on, the existence of both wild and captive animals has been observed, the latter farmed for the production and commercialization of their meat (Deberdt & Scherer, 2007), which, incidentally, has been widely appreciated thanks to its organoleptic traits, low concentrations of fat and cholesterol, and high protein content (Antunes, 2001).

Extensive or semi-extensive systems are used to raise the species. When prepared in native areas, these systems

resemble the animals' natural *habitat* and provide easier access to food and water (Furtado, 2014). Apart from that, swine are free ranging, so they can express their natural habits of wallowing (Boughton & Boughton, 2014) and social interaction (Furtado, 2014). On the other hand, animals are defensive and combative (Long, 2003), which makes them especially prone to sustain fractures of teeth or the mandible (Long, 2003).

The remarkable preoccupation with their lacking odontostomatological health is supported by the possible systemic impacts known, which vary from a decrease in appetite and weight loss (Wiggs & Lobprise, 1997) to potential death of the animal, circumstances that are undesirable in commercial farming and production, due to the economic losses entailed. Thus, local desensitization of the inferior alveolar nerve is essential to execute therapeutic procedures in the oral cavity of these specimens, especially due to the vast territory of sensorial innervation involved, which encompasses molars, premolars, canines and lower incisive teeth, bone portion, gums, and related soft tissue, and the mental skin (Getty, 1986).

Therefore, it is important to carry out morphometric measurements of the mandibular foramen in boars to correlate with their mandibular structures, while performing the proposed anesthetic technique in the safest manner.

Materials and Methods

Six hemimandibles were used, originating from three young-aged cadavers of *Sus scrofa scrofa*, two male and one female, whose approximate age had been verified by the absence of appearance of the last molar tooth. Animals were donated to the didactic and scientific repository of the Animal Anatomy Laboratory of the School of Veterinary Medicine and Animal Science of the Federal University of Uberlândia (UFU-Brazil) by the commercial nursery Temra.

Material preparation started with removing the skin and soft tissue from the region of the animal's head, with the subsequent temporal-mandibular disarticulation. Each mandible was later macerated separately by immersion in sodium hydroxide (NaOH, Lavitex®, [98-99%]) more than 30 min for cleaning and then bleached for 30 min by immersion in an aqueous solution of hydrogen peroxide (H₂O₂, Dinâmica®, [30-36%]) in a dilution of 1:10.

Next, a single examiner proceeded with the biometry in each of the hemimandibles, using a Starrett® digital electronic pachymeter (capacity of 0-150 mm, resolution of 0.01 mm, and accuracy of ± 0.02 mm). Due to the lack of morphometric information pertinent to the mandibular foramen of swine, the measurements used here were based on and adapted from the studies conducted by Barroso et al. (2009), Souza et al. (2013, 2016), Igado (2014), Maximiano (2017), and Magalhães et al. (2019), which involved species of yet another order, the Carnivora. Thus, we defined: **LAM** – the distance between the lateral margin of the condylar process and the root of the lower medial incisive tooth; **SAM** – the distance between the ventral and alveolar margins of the body of the mandible at the level of the diastema that exists between the fourth lower premolar tooth and the first lower molar tooth; **MFVB** – the distance between the caudal limit of the ventral margin of the mandibular foramen to the ventral margin of the angle of the mandible in that same level; **MFCOND** – the distance between the caudal limit of the ventral margin of the mandibular foramen to the medial margin of the condylar process; **MFCOR** – the distance between the caudal limit of the ventral margin of the mandibular foramen to the dorsal limit of the caudal margin of the coronoid process (Figure 1).

The acquired morphometric data were subjected to a descriptive statistical analysis (arithmetic mean, standard

deviation, and coefficient of variation) and to the student's *t* test via BioEstat® 5.3 software. The entire nomenclature used for the description were in accordance with the International Committee on Veterinary Gross Anatomical Nomenclature (2017).

Results

In each of the boar hemimandibles, we observed that the mandibular foramen was located in the region of the ramus and, as from the caudal limit of its ventral margin, stood, on average, 26.6 mm from the ventral margin of the angle of the mandible in that same level (MFVB); 34.92 mm from the medial margin of the condylar process (MFCOND); and 38.63 mm from the dorsal limit of the caudal margin of the coronoid process (MFCOR). In addition, for the purposes of topographic reference, the figures of 142.43 mm and 22.3 mm were found, respectively, for the longitudinal (LAM) and sagittal (SAM) axis of the mandible.

When confronting the data obtained for the right and left antimeres, no statistically significant differences were observed, as shown in Table 1, together with the other numeric results.

It is suggested that the local desensitization of the inferior alveolar nerve, at the level where it penetrates the

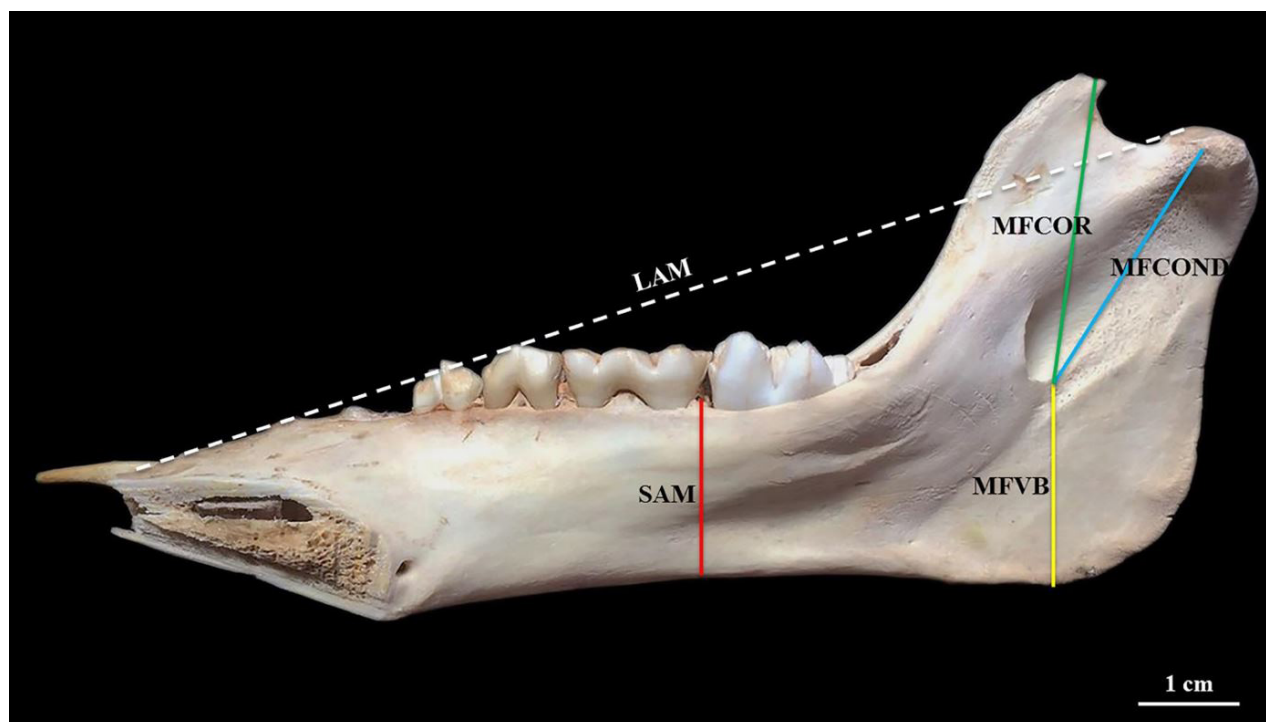


Figure 1 – Medial face of right hemimandible of a young-aged male of *Sus scrofa scrofa*. Demonstration of the measurements of the longitudinal (LAM) and sagittal (SAM) axis; and of the measurements between the caudal limit of the ventral margin of the mandibular foramen and the ventral margin of the angle of the mandible (MFVB), the medial margin of the condylar process (MFCOND), and the dorsal limit of the caudal margin of the coronoid process (MFCOR).

Table 1 – Figures of the morphometric measurements of the six hemimandibles of *Sus scrofa scrofa* – Uberlândia – Brazil, 2019

Measurements	Arithmetic mean and Standard deviation (mm)	Coefficient of variation (%)	p-test
LAM	142.43±1.79	1.26	0.0736
SAM	22.30±0.63	2.84	0.2136
MFVB	26.60±0.90	3.40	0.3941
MFCOND	34.92±0.82	2.37	0.5322
MFCOR	38.63±1.35	3.50	0.0530

LAM: Longitudinal axis of the mandible; SAM: sagittal axis of the mandible; MFVB: Measurements between the caudal limit of the ventral margin of the mandibular foramen and the ventral margin of the angle of the mandible; MFCOND: Measurements between the caudal limit of the ventral margin of the mandibular foramen and the medial margin of the condylar process of the mandible; MFCOR: Measurements between the caudal limit of the ventral margin of the mandibular foramen and the dorsal limit of the caudal margin of the coronoid process of the mandible

mandibular foramen, can be attained from the anesthetic depositing after the introduction of the needle in an oblique and rostradorsal direction for 2.0 cm, and at an angle of 60° with the anatomic reference created by the medial demarcation as defined by the support of the thumb on the lateral margin of the ramus of the mandible, ventrally to the zygomatic arch (Figure 2).

Discussion

Among several known techniques of local anesthesia, the regional neural block is the most widely used procedure in the routine of animal dentistry (Lopes & Gioso, 2007). In order to obtain satisfactory results, previous anatomic knowledge of the region to be manipulated is indispensable

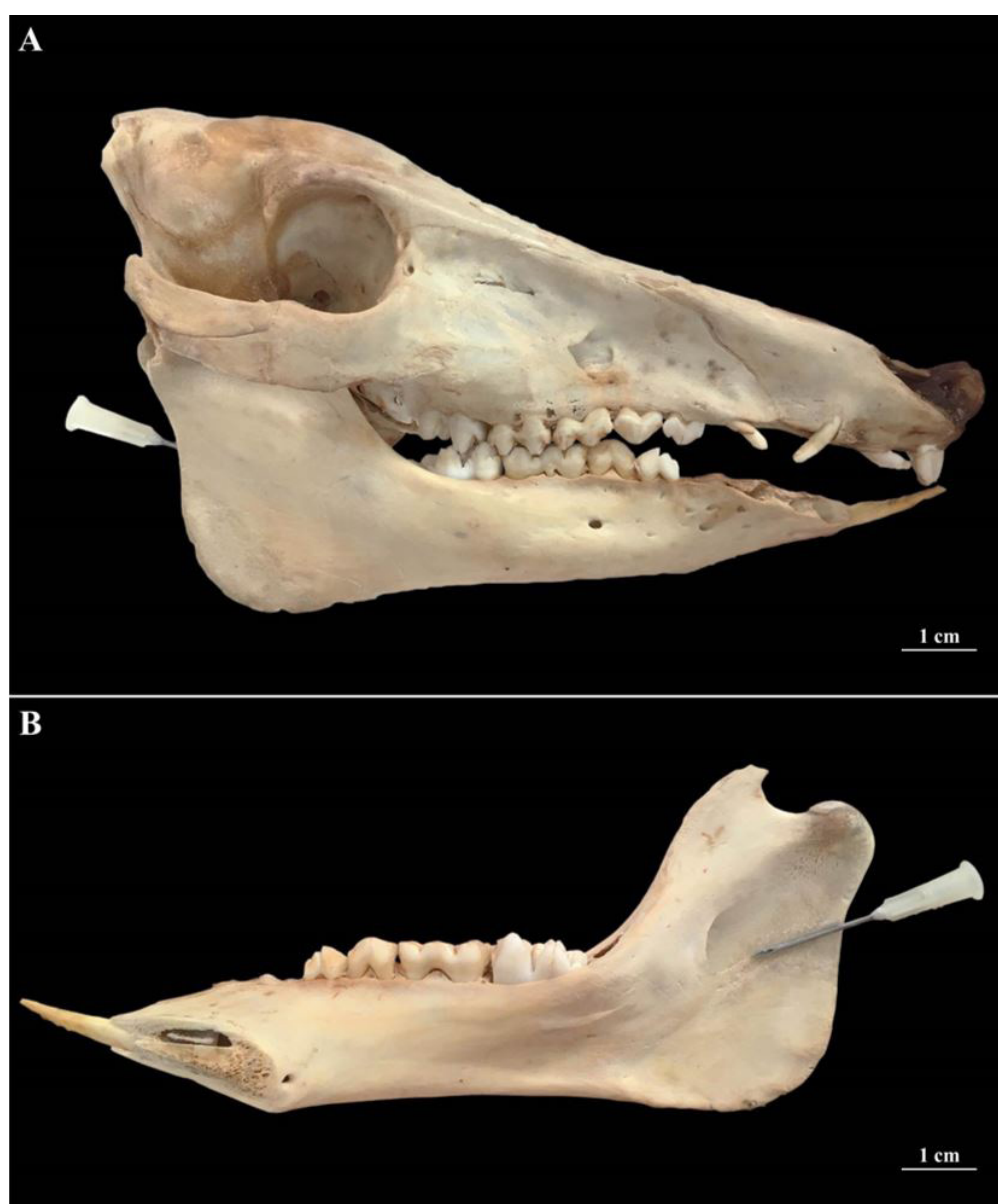


Figure 2 – Demonstration in young-aged male of *Sus scrofa scrofa* of the correct positioning of the needle, after the identification of the anatomic references, for the local desensitization of the inferior alveolar nerve at the level of the mandibular foramen in this species. (A) Right lateral face of skull with a highlight for the positioning of the needle in relation to the ramus of the mandible and to the zygomatic arch; (B) Medial face of the right hemimandible with a highlight for the positioning of the needle in an oblique manner, so as to reach the caudal limit of the ventral margin of the mandibular foramen.

(Moura et al., 2006). However, to date, little is known regarding the odontostomatologic morphology of boars.

Here, we observed that the mandibular foramen of this species was positioned in the ramus of the mandible, just as Getty (1986) mentioned for swine and other domestic animals, Souza et al. (2013) for the crab-eating fox (*Cerdocyon thous*), and Souza et al. (2016) for the maned wolf (*Chrysocyon brachyurus*). Yet, Magalhães et al. (2019) reported that, in the hoary fox (*Lycalopex vetulus*), the said structure was located in the region of angle of the mandible, while other authors, such as König & Liebich (2016), and Evans & Lahunta (2017) were less specific, as they had, respectively, indicated only the medial face of the mandible with the anatomic reference in domestic animals and in domestic dogs.

This topographic knowledge provides leeway not just for the planning of surgical mandibular interventions, but also for a better positioning of the needle during use of the local anesthetic block of the inferior alveolar nerve (Lima et al., 2011), wherein not only the nerve is preserved, but also the associated vascular part, with complete avoidance of hemorrhaging (Mendoza et al., 2004) and hematomas, intravascular injections, paraesthesia (Lopes & Gioso, 2007), and neural-sensory alterations (Mendoza et al., 2004), to name a few.

In that sense, Moraes (2016) champions development and perfection of new anesthetic techniques for the animals, especially wild ones. Hence, the vast majority of these procedures were conceived for the domestic species, while studies that demonstrate methodologies based on the specific anatomy of those animals become necessary, which would, in turn, lead to a higher degree of safety to those patients over clinical and/or surgical interventions (Moraes, 2016). Still, the focus given almost entirely to canids hinders the comparative aspect with the other orders. Therefore, there is a fundamental need to broaden the information and knowledge produced within the said area of work.

As far as one can tell, for domestic dogs (Beckman & Legendre, 2002) and cats (Barroso et al., 2009), crab-eating fox (Souza et al., 2013), maned wolf (Souza et al., 2016), and hoary fox (Magalhães et al., 2019), the authors have followed the recommendations of Gross et al. (1997) and Egger & Love (2009) to propose the introduction of the needle during the extra-oral technique of the anesthetic block under scrutiny, while using the depression present in the ventral margin of the mandible as a point of reference for the approach of the mandibular foramen. However, in boars, it had been noticed that such osseous accident, addressed by Magalhães et al. (2019) as angular incisure, would not

be positioned perpendicularly to this foramen, thus leaving it remarkably farther away from the ventral margin of the mandible, which would correlatively increase the space of contact between needle/structure and the risk of local lesions. In addition, in that species, the caudal-ventral-rostral projection of the sulcus for the mylohyoid nerve also renders that form of access unviable, as the nerve would be exposed to the direction of the piercing penetration.

So, for this swine, it is suggested that the needle be introduced in an oblique and rostrorodorsal direction for 2.0 cm, and at an angle of 60° with the anatomic reference created by the medial demarcation as defined by the support of the thumb on the lateral margin of the ramus of the mandible, ventrally to the zygomatic arch, which would preserve the neighboring structures and provide for a more effective temporary block of the inferior alveolar nerve. This is advantageous for any form of manipulation aimed at a better quality of life for the boars, especially since it is a species with potential for intensive exploitation, either as a source of protein or, even, as a biological model, as stated by Câmara et al. (2004) and Menezes et al. (2001).

Conclusion

We conclude that, in young-aged boars, the local desensitization of the inferior alveolar nerve, at the level where it penetrates the mandibular foramen, can be achieved from the anesthetic depositing after the introduction of the needle, in an oblique and rostrorodorsal direction for 2.0 cm, and at an angle of 60° with the anatomic reference created by the medial demarcation defined by the support of the thumb on the lateral margin of the ramus of the mandible, ventrally to the zygomatic arch, thus preserving the neighboring structures and establishing as an unheard-of anesthetic methodology for boars.

Conflict of Interest

The authors state that they have no conflicts of interest to declare.

Ethics Statement

The study was approved by the Ethics Committee on the Use of Animals of the Federal University of Uberlândia, under the protocol n° 103/13.

Acknowledgements

The authors do not have any acknowledgements in this paper.

References

- Antunes R. Comida de gaulês? Suinocultura Industrial. 2001;151:24-7.
- Barroso RMV, Ferreira FA, Silva RM, Lima EMM. Morphometric analysis of the mandibular foramen of cats (*Felis catus*, Linnaeus 1758) with no defined breed. Biosci J. 2009;25(4):135-42.
- Beckman B, Legendre L. Regional nerve blocks for oral surgery in companion animals. Comp Cont Educ Pract. 2002;24(6):439-44.
- Boughton EH, Boughton RK. Modification by an invasive ecosystem engineer shifts a wet prairie to a monotypic stand. Biol Invasions. 2014;16(10):2105-14. <http://dx.doi.org/10.1007/s10530-014-0650-0>.
- Câmara JA Fo, Scherer PO, Scherer RR, Menezes CMC. Características morfológicas da distribuição vascular cerebral de *Sus scrofa* Linnaeus (Mammalia, Artiodactyla). Rev Bras Zool. 2004;21(4):955-9. <http://dx.doi.org/10.1590/S0101-81752004000400033>.
- Deberdt AJ, Scherer SB. O javali asselvajado: ocorrência e manejo da espécie no Brasil. Nat Conserv. 2007;4(2):31-44.
- Egger C, Love L. Local and regional anesthesia techniques, part 3: blocking the maxillary and mandibular nerves. Vet Med. 2009;104(6):12-5.
- Evans HE, Lahunta A. Guide to the dissection of the dog. 8th ed. Saint Louis: Elsevier; 2017.
- Furtado MM. Artiodactyla - Tayassuidae e Suidae (Queixada, Cateto e Javali). In: Cubas ZS, Silva JCR, Catão-Dias JL, editors. Tratado de animais selvagens: medicina veterinária. 2a ed. São Paulo: Roca; 2014. p. 1037-53.
- Getty R. Anatomia dos animais domésticos. 5a ed. Rio de Janeiro: Guanabara Koogan; 1986.
- Gross ME, Pope ER, O'Brien D, Dodam JR, Polkow-Haight J. Regional anesthesia of the infraorbital and inferior alveolar nerves during noninvasive tooth pulp stimulation in halothane-anesthetized dogs. J Am Vet Med Assoc. 1997;211(11):1403-5. PMID:9394889.
- ICVGAN: International Committee on Veterinary Gross Anatomical Nomenclature. Nomina anatomica veterinaria. 6th ed. Hannover: Editorial Committee; 2017.
- Igado OO. Rostrofacial indices of the Nigerian local dog: implications in veterinary oral and maxillo-facial anaesthesiology of the dolichocephalic canine breed. Int J Morphol. 2014;32(2):738-43. <http://dx.doi.org/10.4067/S0717-95022014000200059>.
- König HE, Liebich HG. Anatomia dos animais domésticos: texto e atlas colorido. 6a ed. Porto Alegre: Artmed; 2016.
- Lima DSC, Figuerêdo AA, Rocha EA, Costa VHMV, Castro MP, Silva RCP, Chagas GL, Araújo LP, Mendonça VRR, Gravina PR, Menezes JVL. Estudo anatômico do forame mandibular e suas relações com pontos de referência do ramo da mandíbula. Rev Bras Cir Crânio-maxilo-facial. 2011;14(2):91-6.
- Long JL. Introduced mammals of the world: their history distribution and influence. Collingwood: CSIRO; 2003. <http://dx.doi.org/10.1071/9780643090156>.
- Lopes FM, Gioso MA. Anestesia local aplicada à odontologia veterinária. Medvep. 2007;5(14):32-9.
- Magalhães HIR, Romão FB, Paula YH, Luz MM, Barcelos JB, Silva Z, Carvalho-Barros RA, Ribeiro LA. Morphometry of the mandibular foramen applied to local anesthesia in hoary fox (*Lycalopex vetulus*). Pesq Vet Bras. 2019;39(4):278-85. <http://dx.doi.org/10.1590/1678-5150-pvb-5749>.
- Maximiano A. Morfometria do crânio de Cachorro-domato *Cerdocyon thous* [tese]. Uberlândia: Faculdade de Medicina Veterinária e Zootecnia, Universidade Federal de Uberlândia; 2017. 58 p.
- Mendoza CC, Vasconcelos BCE, Sampaio G, Cauás M, Batista JEM. Localização topográfica do forame mandibular: estudo comparativo em mandíbulas humanas secas. Rev Cir Traum Buco-Maxilo-Facial. 2004;4(2):137-42.
- Menezes DJA, Carvalho MAM, Cavalcante MF Fo, Souza WM. Configuração do sistema venoso portal da cutia (*Dasyprocta aguti*, RODENTIA). Braz J Vet Res Anim Sci. 2001;38(6):263-6. <http://dx.doi.org/10.1590/S1413-95962001000600003>.
- Moraes FM. Morfometria dos forames mandibular, mental e infraorbital de lobo-guará *Chrysocyon brachyurus*, Illiger, 1815 aplicada a bloqueios anestésicos [tese]. Uberlândia: Faculdade de Medicina Veterinária e Zootecnia, Universidade Federal de Uberlândia; 2016. 55 p.

- Moura AG, Bernardino R Jr, Severino RS, Teixeira CS. Topografia dos forames mentonianos laterais em suínos das linhagens Agroceres e Seghers Genetics do Brasil. *Biosci J*. 2006;22(2):119-23.
- Puertas F, Passamani M. A invasão do javali. *Ciência Hoje*. 2016;336:28-33.
- Rosell C, Fernández-Llario P, Herrero YJ. El jabalí (*Sus scrofa* Linnaeus, 1758). *Galemys*. 2001;13(2):1-25.
- Souza P Jr, Moraes FM, Carvalho NC, Canelo EA, Thiesen R, Santos ALQ. Mandibular morphometry applied to anesthetic blockage in the maned wolf (*Chrysocyon brachyurus*). *J Zoo Wildl Med*. 2016;47(1):91-7. <http://dx.doi.org/10.1638/2015-0092.1>. PMID:27010268.
- Souza P Jr, Pinto RJF, Freitas AB, Carvalho NC. Morfometria do forame mandibular de *Cercopithecus* (Linnaeus, 1766) (cachorro-do-mato). *Biotemas*. 2013;26(2):175-83.
- Valério LAJ. Ocorrência e alimentação da linhagem javali (*Sus scrofa*, Mammalia, Artiodactyla) em estado silvestre no sudoeste do Rio Grande do Sul, Brasil [tese]. Porto Alegre: Universidade Federal do Rio Grande do Sul; 1999. 56 p.
- Wiggs RB, Lobprise HB. *Veterinary dentistry: principles and practice*. Philadelphia: Lippincott-Raven; 1997.

Financial Support: This paper had no financial support.