

Association of intraperitoneal ceftriaxone, intravenous gentamicin and oral metronidazole in the treatment of an abdominal abscess and peritonitis in a horse: case report

Associação da ceftriaxona intraperitoneal, gentamicina intravenosa e do metronidazol oral no tratamento de abscesso abdominal e peritonite em equino: relato de um caso

Juliana de Moura Alonso¹; Alice Ribeiro Ávila¹; Emanuel Vitor Pereira Apolonio¹; Bruna dos Santos²; Ana Liz Garcia Alves¹; Marcos Jun Watanabe¹; Celso Antônio Rodrigues¹; Carlos Alberto Hussni¹ 

¹ Universidade Estadual Paulista, Faculdade de Medicina Veterinária e Zootecnia, Departamento de Cirurgia Veterinária e Reprodução Animal, Botucatu – SP, Brazil

² Universidade Estadual Paulista, Faculdade de Medicina Veterinária e Zootecnia, Departamento de Clínica Veterinária, Botucatu – SP, Brazil

ABSTRACT

Medical management of abdominal abscesses in horses requires prolonged antibiotic therapy and presents varied success rates. A 6-year-old male horse with a history of colic and multiple abdominal punctures to relieve gas was attended. At admission, tachycardia, tachypnea, hyperthermia, mucosal congestion, dehydration, and rigid gait were observed. The association of physical examination, laboratory and ultrasonographic findings allowed the diagnoses of peritonitis and abdominal abscess. Supporting treatment plus broad spectrum antibiotic therapy was performed: daily intraperitoneal ceftriaxone (25 mg/kg, 7 days); daily intravenous gentamicin (6.6 mg/kg, 7 days); *per os* metronidazole three times a day (15 mg/kg 12 days), followed by the same dose twice a day (15 mg/kg 33 days), totaling 45 days of treatment. Plasma fibrinogen and ultrasonographic examination were the most effective tools to evaluate abscess evolution. There was normalization of the physical examination 24 h after beginning the treatment, consecutive regression of the nucleated cell count in the peritoneal fluid, and regression of plasma fibrinogen and size of the abscess. On the 10th treatment day, the animal was discharged from the hospital, maintaining oral therapy with metronidazole every 12 h (15 mg / kg). When the animal returned on the 30th day, an abscess size regression was observed. However, there was no resolution, and therapy with metronidazole was maintained. On the 45th day of treatment, a new hospital evaluation was performed, where the abscess resolved, and metronidazole was suspended. It is highlighted that the therapeutic association used in the treatment of abdominal infection and abscess resulted in a rapid clinical response.

Keywords: Horses. Abdominal infection. Fibrinogen. Sonography. Intraperitoneal route.

RESUMO

O tratamento conservativo dos abscessos abdominais em equinos requer antibioticoterapia prolongada e apresenta variadas taxas de sucesso. Foi atendido um cavalo de seis anos de idade, com histórico de cólica e múltiplas punções abdominais por agulha para esvaziamento de gás. Na admissão, foram observados taquicardia, taquipnéia, hipertermia, congestão mucosa, desidratação e marcha rígida. A associação do exame físico, achados laboratoriais e ultrassonográficos permitiu o diagnóstico de peritonite e abscesso abdominal. Foi realizado tratamento suporte e antibioticoterapia de amplo espectro: ceftriaxona intraperitoneal diária (25 mg/kg, 7 dias); gentamicina intravenosa diária (6,6 mg/kg, 7 dias); metronidazol oral três vezes ao dia (15 mg/kg, 12 dias), seguido de mesma dose duas vezes ao dia, por mais 33 dias, totalizando 45 dias de tratamento. O fibrinogênio plasmático e o exame ultrassonográfico foram os recursos mais eficazes para a avaliação da evolução do abscesso. Após 24 horas do início do tratamento foi constatada a normalização do exame físico, regressão progressiva da contagem de células nucleadas no líquido peritoneal, do fibrinogênio plasmático e do tamanho do abscesso. No 10º dia de tratamento o animal recebeu alta hospitalar, mantendo-se a terapia oral com metronidazol a cada 12 horas (15 mg/Kg). Em retorno, ao 30º dia, observou-se regressão do tamanho do abscesso, entretanto, não houve resolução, tendo sido mantida a terapia com metronidazol. No 45º dia de tratamento, realizou-se nova avaliação hospitalar, onde foi observada a resolução do abscesso e a administração do metronidazol foi suspensa. Destaca-se, que a associação terapêutica utilizada no tratamento de infecção abdominal e abscesso resultou em rápida resposta clínica.

Palavras-chave: Cavalos. Fibrinogênio. Infecção abdominal. Ultrassom abdominal. Via intraperitoneal.

Correspondence to:

Carlos Alberto Hussni
 Universidade Estadual Paulista, Faculdade de Medicina
 Veterinária e Zootecnia, Departamento de Cirurgia Veterinária
 e Reprodução Animal
 Rua Prof. Doutor Walter Mauricio Correa, s/n, UNESP
 Campus de Botucatu
 CEP: 18618-681, Botucatu – SP, Brazil
 e-mail: carlos.hussni@unesp.br

Received: February 04, 2020

Approved: May 19, 2020

How to cite: Alonso JM, Ávila AR, Apolonio EVP, Santos B, Alves ALG, Watanabe MJ, Rodrigues CA, Hussni CA. Association of intraperitoneal ceftriaxone, intravenous gentamicin and oral metronidazole in the treatment of an abdominal abscess and peritonitis in a horse: case report. *Braz J Vet Res Anim Sci.* 2020;57(2):e166204. <https://doi.org/10.11606/issn.1678-4456.bjvras.2020.166204>

Introduction

Abdominal abscesses may develop from different etiologies, either by hematogenous or lymphatic bacterial dissemination, gastrointestinal perforation or devitalization, or previous abdominal surgery (Arnold & Chaffin, 2012; Berlin et al., 2013; Elce, 2006). The diagnosis of abdominal abscesses is challenging due to anatomical location and nonspecific clinical signs (Arnold et al., 2010; Elce, 2006; Mair & Sherlock, 2011; Zicker et al., 1990). Treatment requires prolonged systemic antibiotic therapy or surgical intervention (Berlin et al., 2013; Elce, 2006; Mair & Sherlock, 2011).

Horses with abdominal abscesses often present with a history of colic, fever, weight loss, depression, and anorexia (Arnold & Chaffin, 2012; Elce, 2006). The survival rate varies between 24.6% to 80% and is apparently related to the presence of complications such as adhesions and the severity of the inflammatory response (Berlin et al., 2013).

The use of intraperitoneal route for ceftriaxone administration in horses has recently been described by Alonso et al. (2017, 2018), and prolonged use of metronidazole without occurrence of adverse effects is reported as effective in abdominal abscesses treatment (Sweeney et al., 1991). The aim of this report is to describe a successful medical management of peritonitis and abdominal abscess with an association of intraperitoneal ceftriaxone, systemic gentamicin, and metronidazole.

Case Report

A 6-year-old gelding quarter horse with a history of colic and abdominal distension was seen on the farm by a veterinarian who performed multiple bilateral abdominal

punctures to relieve gas distention. The punctures were performed without clipping and antisepsis, and with extravasation of fecal contents. According to the owner, no diagnosis was performed by the veterinarian, and there was a full recovery of the animal from the colic, yet five days later, apathy and significant decrease in food intake was observed. The animal was treated for gastritis with once daily oral omeprazol (4mg/Kg). Due to lack of clinical improvement, the owner chose to refer the animal to the veterinary hospital. The referral occurred nine days after the multiple abdominal punctures.

At admission, tachycardia (72 bpm), tachypnea (36 mpm), hyperthermia (39.0°C), mildly congested mucosa, 3-second capillary filling time, intestinal hypomotility, rigid gait, abdominal muscular tension line and normal pulmonary auscultation were observed. Rectal palpation was painful, although no more abnormalities were identified. Based on the history of previous colic with multiple abdominal punctures and clinical signs, peritonitis was suspected. Blood samples were harvested for white blood cell count, fibrinogen, renal and hepatic function evaluation, and abdominal sonography was performed. Peritoneal fluid harvest was unproductive in many attempts, including after systemic hydration.

White blood cell (WBC) count was within normal reference, but showed neutrophilia (8,300/μL) and intense hyperfibrinogenemia (1,200 mg/dL). Renal and hepatic functions were within normal reference and globulins increased (4.7 g/dL). Ultrasound examination revealed thickening of the wall of small (0.5 cm) and large intestine segments (0.4 cm), small amount of peritoneal fluid with increased echogenicity and the presence of a 5.99 cm diameter structure, with a heterogeneous appearance, and hyperechoic points inside (Figure 1). The structure was located in the region of the transition between dorsal and right ventral colon, occupying three intercostal spaces (ICS) (12° to 10° ICS) and was compatible with an abdominal abscess. It was not possible to identify if the abscess was attached to the right ventral or dorsal colon. However, the persistent location in subsequent sonographic examinations suggested a right dorsal colon fixation, since this structure is fixed.

Although peritoneal fluid collection was unproductive at admission, ultrasonographic findings associated with clinical manifestation, fibrinogen and subsequent peritoneal fluid collections were consistent with the tentative diagnosis of diffuse peritonitis associated with abdominal abscess formation.

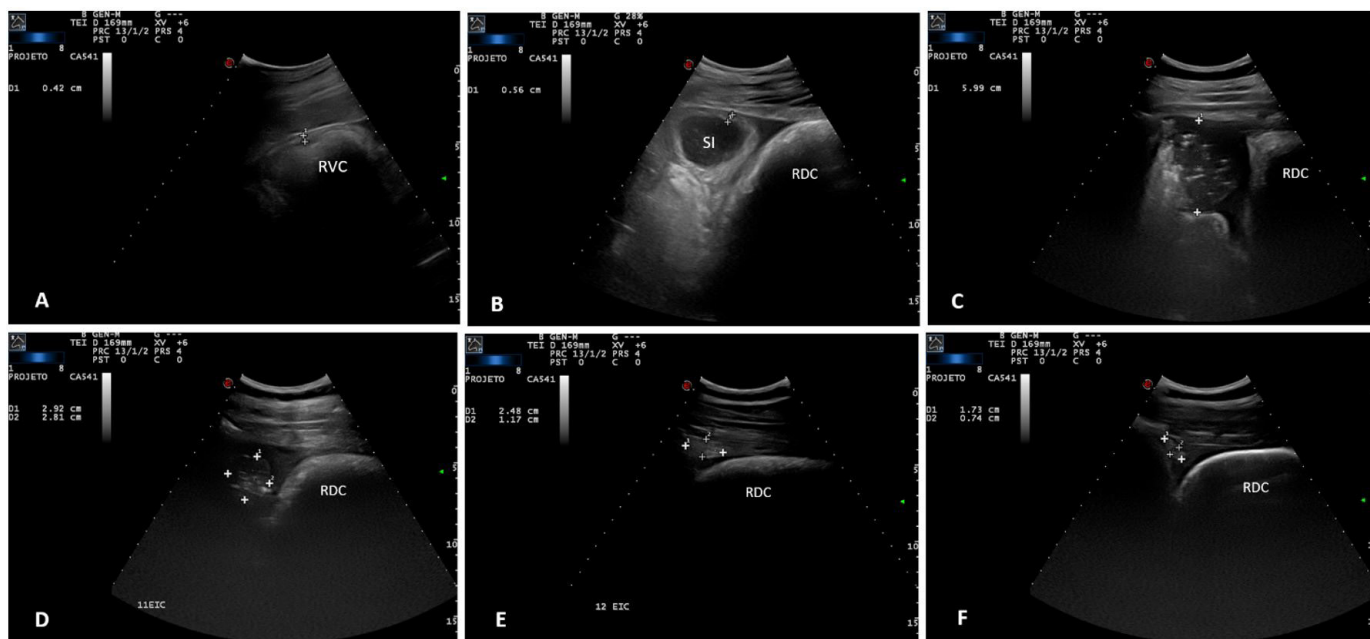


Figure 1 – Ultrasonographic findings. (A) thickening of the wall of the right ventral colon-RVC (0.42 cm) at admission; (B) thickening of the wall of the small intestine-SI (0.56 cm) at admission; (C) Abscess at the first day of treatment (5,99 cm); (D) view of the abscess at 11th ICS region after 30 days of treatment (2,92 x 2,81 cm) – heterogeneous structure with hyperechoic points; (E) view of the abscess at 12th ICS region after 30 days of treatment (2,48 x 1,17 cm) – homogeneous structure; (F) view of the abscess at the 12th ICS region at the 45th day of treatment (1,71 x 0,74 cm) – homogeneous structure. RDC-Right dorsal colon; SI-Small intestine.

An aggressive and immediate antimicrobial therapy, consisting of intravenous gentamicin (6.6 mg/Kg SID 7 days), intraperitoneal ceftriaxone (25 mg/Kg SID 7 days) and oral metronidazole (15 mg/kg TID 12 days; 15 mg/kg BID 33 days) was started in association with flunixin meglumine (1.1 mg/kg IV SID 3 days) and hydroelectrolytic repository.

Prior to ceftriaxone intraperitoneal administration, the skin of the left paralumbar fossa was clipped, the thickness of abdominal wall was measured by ultrasound and routinely antisepsis performed. The dosage of 25 mg/Kg was prepared in 250 mL of saline solution. Abdominal wall and skin were anesthetized with 10mL of lidocaine and access was performed with the stylet of a 14 G catheter. After skin transposition, one drop of solution was applied inside the catheter and then progressively introduced until reaching the abdominal cavity. Due to negative pressure, the solution was aspirated at the moment of abdominal access indicating the position where the solution could be coupled to the catheter (Figure 2). Intraperitoneal ceftriaxone administration was repeated for 7 days, respecting the interval of doses of 24 h established by Alonso et al. (2018).

After 24 h of treatment, no hyperthermia was observed (38.1°C), there was progressive improvement of the clinical signs, represented by increase of appetite, absence of abdominal stiffness and normalization of vital parameters

(heart rate: 40 bpm; respiratory rate: 12 mpm; capillary refill time: 2 sec) and intestinal motility.

On the fifth day of treatment, peritoneal fluid was with 15.500 nucleated cells/ μ L with a predominance of segmented neutrophils (11,625/ μ L), followed by typical lymphocytes (2,790/ μ L), mononucleated cells (930/ μ L) and macrophages (155/ μ L). At this time, hyperfibrinogenemia (600 mg/dL) was maintained, though with a 50% reduction in relation to the initial value (Figure 3). Seven days after the beginning of the treatment, peritoneal fluid was with 7,500 nucleated cells/ μ L and with a predominance of segmented neutrophils (4,575/ μ L), followed by typical lymphocytes (1,875/ μ L) and mononucleated cells (1,050/ μ L). Due to the maintenance of clinical parameters within the reference normality and reduction of nucleated cell count to less than 10,000 cells/ μ L, and no ultrasonographic signs of diffuse peritonitis, ceftriaxone and gentamicin were discontinued, patient monitoring was performed until day 10 of treatment with metronidazole. At day 10, the abscess presented the same structural characteristic, but with a reduction of its diameter to 3.87 cm. The animal was discharged, with prescription of metronidazole for a total of 30 days and return for reevaluation.

At the 12th day of treatment, at the property, the owner reported the occurrence of softening feces, with no evident signs of dehydration, apathy, or increased defecation

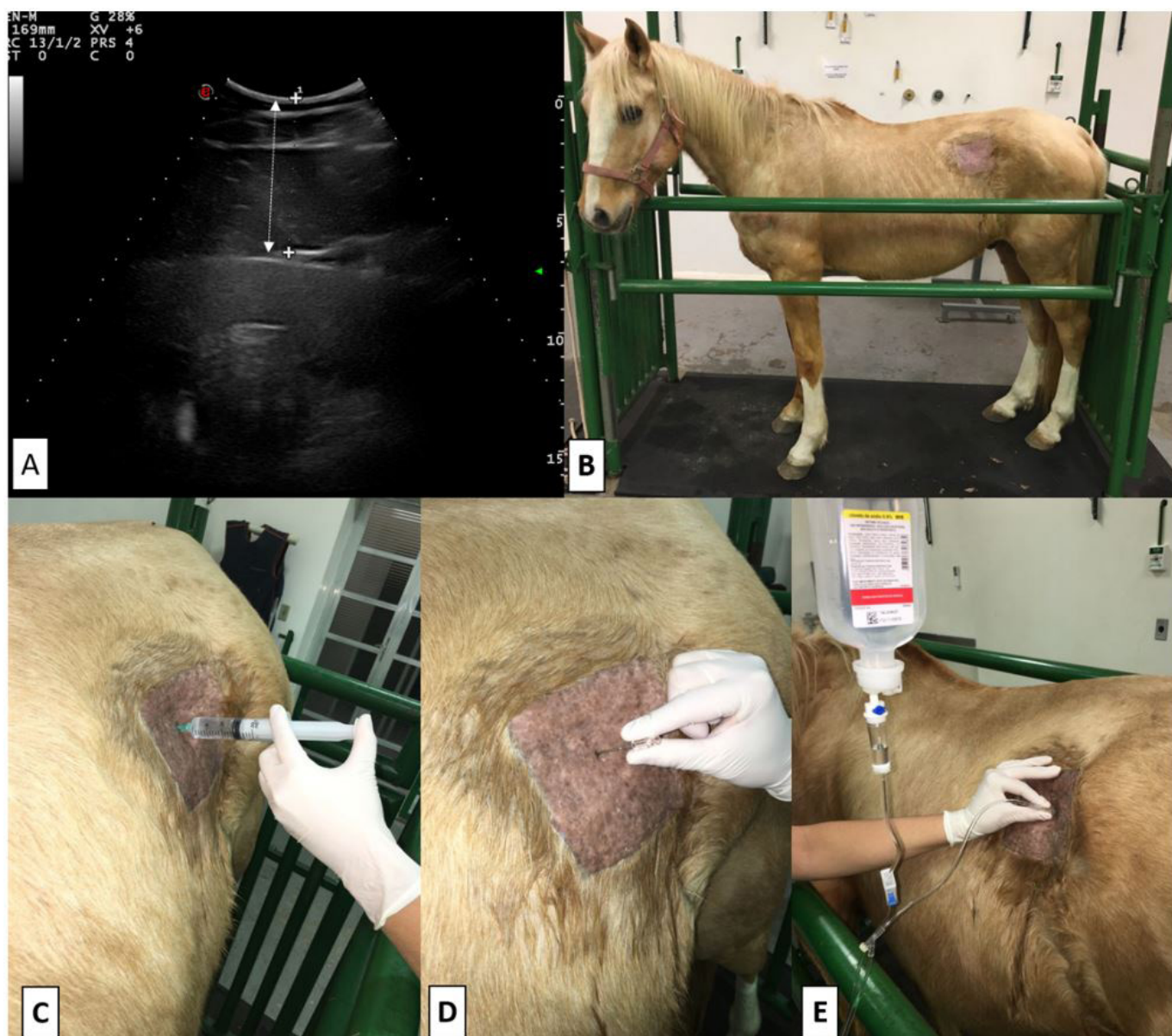


Figure 2 – Intraoperative ceftriaxone administration. (A) Abdominal wall ultrasonographic measurement (arrow); (B) Lateral view of the animal with the left paralumbar fossa clipped and prepared for administration; (C) Local anesthetic block; (D) Progressive introduction of 14G catheter in order to identify the access to abdominal cavity; (E) Ceftriaxone solution administration.

frequency. WBC count, fibrinogen, liver, and renal function was evaluated in the property and all values were within normal values. Administration of metronidazole was maintained at the same dose, administered every 12 h. After the change, there was feces normalization.

After 30 days of treatment, a hospital re-evaluation was performed. WBC count was normal, although with neutrophilia (8,100/ μ L), fibrinogen was 400 mg/dL (Figure 3), creatinine, aspartate aminotransferase and alkaline phosphatase were within normal reference, but urea (55 mg/dL) and gamma glutamyl transferase (44.7 IU/L) were slightly increased. Peritoneal fluid presented 4.400 nucleated cells/ μ L with a predominance of segmented neutrophils (3,476/ μ L), followed by typical lymphocytes (528/ μ L). Ultrasound

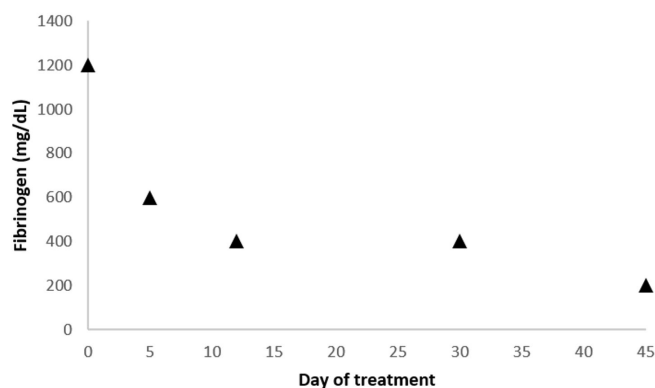


Figure 3 – Fibrinogen evolution during treatment period.

examination revealed no inflammatory alterations in the abdominal cavity. It was possible to observe the abscess in 2 ICS (12th and 11th) and its diameter was reduced

to 2.92 x 2.81 cm in the 11th ICS and 2.48 x 1.17 cm in the 12th ICS (Figure 2). Only in the 11th ICS was it possible to observe the presence of hyperechoic points inside the abscess, and in the 12th ICS region it was possible to observe only a homogeneous structure compatible with fibrosis of the healing process.

Due to maintenance of the abscess in the 11th ICS, and the favorable clinical and ultrasonographic response to the adopted therapy, metronidazole was maintained and a new return was requested in 15 days. In the re-evaluation, WBC count was within normal limits; peritoneal fluid with 1,600 nucleated cells/ μ L with a predominance of segmented neutrophils (1,088/ μ L), followed by mononucleated cells (336/ μ L), macrophages (112/ μ L) and typical lymphocytes (64/ μ L) renal and hepatic function were within normal values. Ultrasonographic examination showed only one small homogeneous structure of 1.71 x 0.74 cm in diameter in the region of the 12th ICS (Figure 2). Treatment with metronidazole was discontinued, and the disease was considered resolved. Through telephone contact after 12 months of treatment discontinuation no clinical abnormalities were reported.

Discussion

Abdominal abscesses can develop from different etiologies, being classified as primary or secondary. In the primary form, the abscesses originate from hematogenous or lymphatic spread, and in the secondary form, due to abdominal traumatic perforations, ulcers, gastrointestinal tract necrosis or after exploratory celiotomy (Arnold & Chaffin, 2012; Berlin et al., 2013; Elce, 2006). It is believed that the development of the abscess was secondary, and due to multiple abdominal punctures performed during colic treatment. Since the abdominal punctures were realized bilaterally and in many positions of the abdomen, the location of the abscess should be varied. Nine days is a compatible time for the development of an abdominal abscess, and is considered a short evolution, which can be compatible with a conservative approach (Berlin et al., 2013; Elce, 2006).

In spite of the non-realization of the peritoneal fluid culture, it is important to recognize the main associated agents with abdominal abscesses and peritonitis in order to choose the best therapeutic approach. The most common agents associated with abscess formation in adult horses are *Streptococcus equi*, *Streptococcus equi* subsp. *zooeconomicus*, *Corynebacterium spp.*, *Rhodococcus equi*, *Enterobacteriaceae* and strict anaerobes (*Bacteroides spp.*, *Fusobacterium necrophorum*, and *Clostridium spp.*) (Berlin et al., 2013;

Mair & Sherlock, 2011; Mogg & Rutherford, 2006). Despite the higher prevalence of *Streptococcus equi* as an etiological agent of abdominal abscesses in horses (Berlin et al., 2013; Elce, 2006; Mair & Sherlock, 2011; Pusterla et al., 2007), its etiology is associated with hematogenous dissemination in cases of strangles (Elce, 2006; Pusterla et al., 2007), not compatible with the animal history in this case.

Imprudent drainage of abdominal gas may result in the development of peritonitis and abdominal abscesses as a result of contamination by skin colonizing agent or intestinal bacterial flora (Unger et al., 2014). Thus, the previous colic episode with multiple abdominal punctures without clipping and antisepsis, and with extravasation of fecal contents, suggested that the etiological agent of peritonitis and abdominal abscess may arise from skin colonizing agents such as *Staphylococcus spp.* and *Corynebacterium pseudotuberculosis* (White & Yu, 2006) and from intestinal bacterial flora, such as *Bacteroides spp.*, *Clostridium spp.*, and *Escherichia coli* (Elce, 2006). The analysis and culture of the peritoneal fluid would be fundamental to define the etiological agent; however it was unproductive.

The diagnosis of abdominal abscesses is challenging due to anatomical location and nonspecific clinical signs, such as colic, hyperthermia, weight loss, depression, lethargy, anorexia, tachycardia, and tachypnea (Arnold & Chaffin, 2012; Mair & Sherlock, 2011; Zicker et al., 1990). In addition to the classic signs, abdominal stiffness and reluctance to locomotion were observed. Observed clinical signs were compatible with those previously described (Aleman et al., 2003; Mair & Sherlock, 2011; Pusterla et al., 2007; Rumbaugh et al., 1978; Sweeney et al., 1986). The diagnosis of abdominal abscesses is based on clinical signs, rectal palpation, ultrasonographic findings, peritoneal fluid analysis, WBC count and surgical approach (Berlin et al., 2013). In the present case, the association of history, clinical, laboratorial and ultrasonographic findings allowed the diagnosis of diffuse septic peritonitis and abdominal abscess.

Abdominal abscesses are described in the liver, mesenteric lymph nodes, kidneys, spleen, uterus, bladder, intestine and abdominal wall (Berlin et al., 2013). Ultrasonographic examination detected the presence of diffuse peritonitis, with thickening of the intestinal walls and increased echogenicity of the peritoneal fluid and the presence of abdominal abscess adjacent to the right dorsal colon in the middle third of the right abdomen. Mair & Sherlock (2011) described six cases of abdominal abscess in adult horses with a variable location between jejunum, ileum, mesenteric root, and cecum, in which, according to the authors, all

abscesses were identified through rectal palpation and at ultrasound. In the present case, the identification was exclusively identified via ultrasonographic examination, due to its cranial location.

WBC count showed total leukocytes within the normal range, but with neutrophilia and hyperfibrinogenemia. According to Jacobsen et al. (2009), in cases of chronic inflammatory response, fibrinogen reflects more clearly the intensity of the inflammatory process than the peripheral leukocyte count. Fibrinogen is an acute phase protein widely used for monitoring the therapeutic response in cases of abdominal abscess (Berlin et al., 2013; Mair & Sherlock, 2011).

Abdominal abscess treatment requires prolonged systemic antibiotic therapy (Berlin et al., 2013; Elce, 2006) or surgical excision, drainage, and lavage procedure (Mair & Sherlock, 2011) or marsupialization (Prades et al., 1989; Rigg et al., 1987). The success rate of conservative or surgical therapy ranges from 24.6 to 100% and is related to the occurrence of complications such as adhesion formation and diffuse peritonitis (Berlin et al., 2013; Mair & Sherlock, 2011). Pusterla et al. (2007) obtained 40% success with the conservative treatment of 10 horses with abdominal abscesses due to *Streptococcus*, and Berlin et al. (2013) obtained 100% success in 4 horses with *Streptococcus* secondary abscesses treated with penicillin G. Mair & Sherlock (2011) obtained 66.7% success, performing drainage and abdominal lavage in 6 horses. The absence of an exudative peritonitis, with increased free peritoneal fluid and debris supported the decision to institute antibiotic therapy without abdominal lavage.

It is described that the location, time of evolution and size of the abscess can interfere in the results obtained in the conservative treatment (Mair & Sherlock, 2011). According to Haggett & Wilson (2008) and Mair & Sherlock (2011), medical treatment of large abscesses (≥ 15 -20 cm) is not effective due to the difficulty of antibiotics penetration, requiring surgical removal. Yet Berlin et al. (2013) demonstrated efficacy of conservative therapy even in abscesses with a diameter between 15 and 25 cm.

Although surgical removal results in a reduction of antibiotic therapy duration (Blot & Dewaele, 2005; Elce, 2006), the conservative approach was chosen, considering the short time of disease evolution, which favors the penetration of antimicrobials and the difficult surgical approach of the right dorsal colon. The presence of diffuse and active peritonitis favored the choice of clinical therapy. Controlled clinical trials are necessary to compare surgical and conservative approaches of abdominal abscesses. In the

absence of these studies, it is difficult to compare the merits and efficacy of both therapeutic options.

The treatment of abdominal abscesses in horses has previously been described with ceftiofur, rifampicin, potentiated sulfonamides, chloramphenicol, gentamicin, and metronidazole (Aleman et al., 2003; Elce, 2006; Haggett & Wilson, 2008; Mogg & Rutherford, 2006; Pusterla et al., 2007). Due to the high occurrence of abdominal abscesses secondary to hematogenous spread of *Streptococcus equi* in cases of strangles, treatment with penicillin (Berlin et al., 2013) and combination of sulfonamide potentiated and rifampicin (Haggett & Wilson, 2008; Pusterla et al., 2007) are more frequently used. In spite of the described low penetration of penicillin, Berlin et al. (2013) used penicillin G at a dose of 44.000 IU/kg and obtained 100% therapeutic success in 4 animals with abscesses secondary to strangles.

The adopted therapeutic strategy was based on the association of antimicrobials to obtain a broad spectrum of action, with coverage for *gram* positive, *gram* negative and anaerobic bacteria. The therapy consisted of ceftriaxone, gentamicin, and metronidazole combination.

Ceftriaxone is a third-generation cephalosporin that has a broad antibacterial spectrum, acting against gram-positive, gram-negative, and certain anaerobic bacteria. It has established clinical efficacy, and excellent penetration and therapeutic concentration in most body fluids (Alonso et al., 2018; Bijie et al., 2005; Lamb et al., 2002; Ringger et al., 1996, 1998). The best therapeutic results are obtained when a dose regimen that results in high concentrations of the drug at the site of infection, above the minimum inhibitory concentration (MIC) for prolonged periods is used (Alonso et al., 2018; Levison & Levison, 2009). According to Alonso et al. (2018) ceftriaxone intraperitoneal administration results in concentrations above the MIC for enterobacteria for 24 h in the peritoneal fluid of healthy horses. In order to provide high and long-lasting antimicrobial concentrations in the peritoneal fluid, daily ceftriaxone was given intraperitoneally.

Gentamicin was added to the treatment because of its established efficacy against gram-negative bacteria (Haggett & Wilson, 2008). Despite the known limitation of gentamicin penetration into abscesses (Haggett & Wilson, 2008; Jones et al., 1998), it was used due to the presence of associated diffuse and active peritonitis and earlier treatment. Administration of gentamicin occurred systemically, due to the absence of controlled studies evaluating its use by the intraperitoneal route.

Due to the history of fecal extravasation and the high prevalence of anaerobic bacteria in intestinal flora, metronidazole was added to therapy with the objective of action against anaerobic and due to its wide tissue distribution and penetration in abscesses (Aleman et al., 2003; Baggot et al., 1998; Haggett & Wilson, 2008; Specht et al., 1992; Steinman et al., 2000; Sweeney et al., 1986).

Appropriate duration of antimicrobial therapy in cases of abdominal abscess is not known, and the range of treatment durations are described as 35 days (Berlin et al., 2013); 47 days (Mair & Sherlock, 2011); 72 days (Pusterla et al., 2007); and three months in an isolated case (Aleman et al., 2003). Therapy discontinuation should be based on clinical evolution, fibrinogen, WBC count, abdominal sonography, rectal palpation, and laparoscopy (Elce, 2006; Mair & Sherlock, 2011).

Gentamicin and ceftriaxone therapy lasted 7 days. Clinical improvement was observed after 12 h of the institution of antimicrobial therapy and support, such as return of appetite, alertness, and reduction of locomotion stiffness. The occurrence of adverse effects to antimicrobial therapy was observed after 12 days of therapy, with the occurrence of feces softening, with no signs of dehydration, apathy, or increased defecation frequency. After increasing the interval of metronidazole doses, feces returned to normal.

Although fecal softening occurred on the 12th day of metronidazole treatment, it cannot be inferred that the occurrence of this adverse effect was exclusively due to the use of metronidazole. Diarrhea secondary to antimicrobial use is described during and after the discontinuation of these drugs (Barr et al., 2013), and it is believed that the association of the antibiotics may have contributed to the imbalance of the intestinal flora.

In a retrospective study evaluating the use of metronidazole in 200 horses with various infectious processes, including 39 cases of peritonitis and / or abdominal abscess, anorexia was observed in 4/200 animals as an adverse effect and whose resolution occurred after discontinuation of treatment (Sweeney et al., 1991). Cypher et al. (2015) described the use of metronidazole (25 mg/kg - VO - TID) for the treatment of hepatic abscess in a horse for 10 days; however, it was discontinued after signs of anorexia. No previous studies reported the occurrence of diarrhea after prolonged metronidazole therapy.

Intraperitoneal ceftriaxone administration at a dose of 25 mg/kg for 5 days did not result in adverse effects in the study of Alonso et al. (2018) and gentamicin despite known nephrotoxicity (Haggett & Wilson, 2008) did not result in adverse effects. Corroborating with the possibility

that the association of the drugs have triggered the intestinal flora imbalance.

The long-term use of metronidazole is poorly reported in horses (Sweeney et al., 1991), although it is widely used in medicine (Mikamo et al., 2015, 2016; Smith et al., 1983). After feces normalization at the 14th day of treatment, no clinical or laboratorial adverse effects were observed until the 45th day of treatment and progressive regression of abscess size was obtained.

Abdominal sonography, fibrinogen, leukocyte count and nucleated cells in the peritoneal fluid allow strict control of the evolution of the disease, emphasizing abdominal ultrasonography and fibrinogen evolution for the decision to treatment discontinuation. Abdominal ultrasound examination revealed reduction of abscess size and acquired hyperechoic and homogeneous aspect, suggesting resolution of infection and fibrosis.

Although the collection of peritoneal fluid was not productive at hospital admission and prior to the installation of therapeutic management, the evolution of nucleated cell counts throughout the treatment period demonstrated the presence of peritonitis, and a favorable response to therapy.

Based on the clinical, laboratorial and sonographic findings, it was possible to identify resolution of the diffuse peritonitis during hospitalization (10 days). The favorable evolution obtained in a short period of treatment of the abscess is highlighted when compared to the average duration of the therapies. Furthermore, abdominal sonography and plasma concentration of fibrinogen were decisive for monitoring resolution of the abdominal abscess.

Due to the impossibility of identifying the etiological agent, it is difficult to attribute the result obtained to the use of a specific drug. However, the rapid recovery after association of the drugs is emphasized and a favorable evolution continues after exclusive maintenance of metronidazole. Studies are required using these drugs in combination or alone and by different routes in a larger number of animals in order to support the indication of this therapy.

Conflict of Interests

The authors declare no conflict of interests.

Ethics Statement

All animals owners signs a consentment with an agreement for cases and images divulgation at hospital admission.

Acknowledgements

None to declare.

References

- Aleman M, Watson JL, Jang SS. Clostridium novyi type A intra-abdominal abscess in a horse. *J Vet Intern Med.* 2003;17(6):934-6. <http://dx.doi.org/10.1111/j.1939-1676.2003.tb02537.x>. PMID:14658735.
- Alonso JM, Nitta TY, Akutagawa TYM, Crescencio AP, Takahira RK, Santos B, Alves ALG, Watanabe MJ, Rodrigues CA, Hussni CA. Evaluation of *Tenckhoff* catheter use and ceftriaxone intraperitoneal administration in horses. *J Eq Vet Sci.* 2017;53:55-63. <http://dx.doi.org/10.1016/j.jevs.2017.01.011>.
- Alonso JM, Peccinini RG, Campos ML, Nitta TY, Akutagawa TYM, Crescencio AP, Alves ALG, Rodrigues CA, Watanabe MJ, Hussni CA. Plasma and peritoneal fluid concentrations of ceftriaxone after intravenous and intraperitoneal administration in horses. *Vet J.* 2018;234:72-6. <http://dx.doi.org/10.1016/j.tvjl.2018.02.006>. PMID:29680398.
- Arnold CE, Chaffin MK, Cohen ND. Abdominal abscesses in adult horses: 61 cases (1993-2008). *Proc Am Ass Eq Pract.* 2010;56:269.
- Arnold CE, Chaffin MK. Abdominal abscesses in adult horses: 61 cases (1993-2008). *J Am Vet Med Assoc.* 2012;241(12):1659-65. <http://dx.doi.org/10.2460/javma.241.12.1659>. PMID:23216043.
- Baggot JD, Wilson WD, Hietala S. Clinical pharmacokinetics of metronidazole in horses. *J Vet Pharmacol Ther.* 1998;11(4):417-20. <http://dx.doi.org/10.1111/j.1365-2885.1998.tb00205.x>. PMID:3210271.
- Barr BS, Waldridge BM, Morresey PR, Reed SM, Clark C, Belgrave R, Donecker JM, Weigel DJ. Antimicrobial-associated diarrhoea in three equine referral practices. *Eq Vet J.* 2013;45(2):154-8. <http://dx.doi.org/10.1111/j.2042-3306.2012.00595.x>. PMID:22779907.
- Berlin D, Kelmer G, Steinman A, Sutton GA. Successful medical management of intra-abdominal abscesses in 4 adult horses. *Can Vet J.* 2013;54(2):157-61. PMID:23904639.
- Bijie H, Kulpradist S, Manalaysay M, Soebandrio A. In vitro activity, pharmacokinetics, clinical efficacy, safety and pharmacoeconomics of ceftriaxone compared with third and fourth generation cephalosporins. *J Chemother.* 2005;17(1):3-24. PMID:15828439.
- Blot S, DeWaele JJ. Critical issues in the clinical management of complicated intra-abdominal infections. *Drugs.* 2005;65(12):1611-20. <http://dx.doi.org/10.2165/00003495-200565120-00002>. PMID:16060697.
- Cypher EE, Kendall AT, Panizzi L, Stewart AJ, Taylor SL, Bodaan CJ, Riley CB, Gordon SJG, Whitfield LK. Medical and surgical management of an intra-abdominal abscess of hepatic origin in a horse. *J Am Vet Med Assoc.* 2015;247(1):98-105. <http://dx.doi.org/10.2460/javma.247.1.98>. PMID:26086235.
- Elce YA. Infections in the equine abdomen and pelvis: perirectal abscesses, umbilical infections, and peritonitis. *Vet Clin North Am Equine Pract.* 2006;22(2):419-36, ix. <http://dx.doi.org/10.1016/j.cveq.2006.04.002>. PMID:16882482.
- Haggett EF, Wilson WD. Overview of the use of antimicrobials for the treatment of bacterial infections in horses. *Eq Vet Educ.* 2008;20(8):433-48. <http://dx.doi.org/10.2746/095777308X338893>.
- Jacobsen S, Nielsen JV, Kjelgaard-Hansen M, Toelboell T, Fjeldborg J, Halling-Thomsen M, Martinussen T, Thoenner MB. Acute phase response to surgery of varying intensity in horses: A preliminary study. *Vet Surg.* 2009;38(6):762-9. <http://dx.doi.org/10.1111/j.1532-950X.2009.00564.x>. PMID:19674420.
- Jones SL, Wilson WD, Milhalyi JE. Pharmacokinetics of gentamicin in healthy adult horses during intravenous fluid administration. *J Vet Pharmacol Ther.* 1998;21(3):247-9. <http://dx.doi.org/10.1046/j.1365-2885.1998.00123.x>. PMID:9673967.
- Lamb HM, Ormrod D, Scott LJ, Figgitt DP. Ceftriaxone: an update of its use in the management of community-acquired and nosocomial infections. *Drugs.* 2002;62(7):1041-89. <http://dx.doi.org/10.2165/00003495-200262070-00005>. PMID:11985490.
- Levison ME, Levison JH. Pharmacokinetics and pharmacodynamics of antibacterial agents. *Infect Dis Clin North Am.* 2009;23(4):791-815, vii. <http://dx.doi.org/10.1016/j.idc.2009.06.008>. PMID:19909885.
- Mair TS, Sherlock CE. Surgical drainage and post-operative lavage of large abdominal abscesses in six mature horses. *Equine Vet J Suppl.* 2011;43(39):123-7. <http://dx.doi.org/10.1111/j.2042-3306.2011.00405.x>. PMID:21790766.
- Mikamo H, Matsumizu M, Nakazuru Y, Nagashima M. Efficacy and safety of metronidazole injection for the

- treatment of infectious peritonitis, abdominal abscess and pelvic inflammatory diseases in Japan. *J Infect Chemother.* 2015;21(2):96-104. <http://dx.doi.org/10.1016/j.jiac.2014.10.005>. PMID:25442806.
- Mikamo H, Yuasa A, Wada K, Crawford B, Sugimoto N. Optimal treatment for complicated intra-abdominal infections in the era of antibiotic resistance: a systematic review and meta-analysis of the efficacy and safety of combined therapy with metronidazole. *Open Forum Infect Dis.* 2016;3(3):ofw143. <http://dx.doi.org/10.1093/ofid/ofw143>. PMID:27704002.
- Mogg TD, Rutherford DJ. Intra-abdominal abscess and peritonitis in an Appaloosa gelding. *Vet Clin North Am Equine Pract.* 2006;22(1):e17-25. <http://dx.doi.org/10.1016/j.cveq.2005.12.027>. PMID:16627091.
- Prades M, Peyton L, Pattio N, Langlois J. Surgical treatment of an abdominal abscess by marsupialisation in the horse: a report of two cases. *Equine Vet J.* 1989;21(6):459-61. <http://dx.doi.org/10.1111/j.2042-3306.1989.tb02196.x>. PMID:2531655.
- Pusterla N, Whitcomb M, Wilson W. Internal abdominal abscesses caused by *Streptococcus equi* subspecies *equi* in 10 horses in California. *Vet Rec.* 2007;160(17):589-92. <http://dx.doi.org/10.1136/vr.160.17.589>. PMID:17468322.
- Rigg DL, Gatlin SJ, Reinertson EL. Marsupialization of an abdominal abscess caused by *Serratia marcescens* in a mare. *JAVMA.* 1987;191(2):222-4. PMID:3301767.
- Ringger NC, Brown MP, Kohlepp SJ, Gronwall RR, Merritt K. Pharmacokinetics of ceftriaxone in neonatal foals. *Equine Vet J.* 1998;30(2):163-5. <http://dx.doi.org/10.1111/j.2042-3306.1998.tb04477.x>. PMID:9535074.
- Ringger NC, Pearson EG, Gronwall R, Kohlepp SJ. Pharmacokinetics of ceftriaxone in healthy horses. *Equine Vet J.* 1996;28(6):476-9. <http://dx.doi.org/10.1111/j.2042-3306.1996.tb01620.x>. PMID:9049497.
- Rumbaugh GE, Smith BP, Carlson GP. Internal abdominal abscesses in the horse: a study of 25 cases. *J Am Vet Med Assoc.* 1978;172(3):304-9. PMID:621178.
- Smith JA, Forward AD, Skidmore AG, Bell GA, Murphy JM, Sutherland E. Metronidazole in the treatment of intra-abdominal sepsis. *Surgery.* 1983;93(Pt 1):217-20. PMID:6336865.
- Specht TE, Brown MP, Gronwall RR, Rib WJ, Houston AE. Pharmacokinetics of metronidazole and its concentration in body fluids and endometrial tissues of mares. *Am J Vet Res.* 1992;53(10):1807-12. PMID:1456525.
- Steinman A, Gips M, Lavy E, Sinay I, Soback S. Pharmacokinetics of metronidazole in horses after intravenous, rectal and oral administration. *J Vet Pharmacol Ther.* 2000;23(6):353-7. <http://dx.doi.org/10.1046/j.1365-2885.2000.00294.x>. PMID:11168912.
- Sweeney RW, Sweeney CR, Soma LR, Woodward CB, Charlton CA. Pharmacokinetics of metronidazole given to horses by intravenous and oral routes. *Am J Vet Res.* 1986;47(8):1726-9. PMID:3752681.
- Sweeney RW, Sweeney CR, Weiher J. Clinical use of metronidazole in horses: 200 cases (1984-1989). *J Am Vet Med Assoc.* 1991;198(6):1045-8. PMID:2032913.
- Unger L, Fouché N, Schnider D, Witte S. Peritonitis, abscessation and haemorrhage: Complications of transcutaneous caecal decompression. *Eq Vet Educ.* 2014;26(8):430-5.
- White SD, Yu AA. Equine dermatology. Selected Topics in Dermatology. 2006;52:463-6.
- Zicker SC, Wilson WD, Medearis I. Differentiation between intra-abdominal neoplasms and abscesses in horses, using clinical and laboratory data: 40 cases (1973-1988). *J Am Vet Med Assoc.* 1990;196(7):1130-4. PMID:2329084.

Financial Support: none to declare.