


# Ocular lesions in a domestic feline: a closer look at the fungal pathogen *Sporothrix brasiliensis*

## Lesões oculares em um felino doméstico: um olhar atento ao patógeno fúngico *Sporothrix brasiliensis*

Gabriele Barros Mothé<sup>1</sup>; Nathália Faria Reis<sup>1</sup>; Carla Stefany Isla Melivilu<sup>2</sup>; Aginaldo Francisco Mendes Junior<sup>3</sup>; Cinthia Silva dos Santos<sup>4</sup>; Ana Maria Dieckmann<sup>5</sup>; Ricardo Luiz Dantas Machado<sup>1</sup>; Elisabeth Martins da Silva da Rocha<sup>1</sup>; Andréa Regina de Souza Baptista<sup>1</sup> 

<sup>1</sup> Universidade Federal Fluminense, Instituto Biomédico, Centro de Investigação de Microrganismos, Niterói – RJ, Brazil

<sup>2</sup> Universidad de Las Américas, Facultad de Medicina Veterinaria y Agronomía, Concepción, Chile

<sup>3</sup> Universidade Santa Úrsula, Rio de Janeiro – RJ, Brazil

<sup>4</sup> Prefeitura Municipal de Niterói, Fundação Municipal de Saúde, Centro de Controle de Zoonoses, Niterói – RJ, Brazil

<sup>5</sup> Universidade Federal Fluminense, Faculdade de Medicina Veterinária, Niterói – RJ, Brazil

### ABSTRACT

Sporotrichosis is a dermatozoonosis, caused by dimorphic pathogenic fungi of the genus *Sporothrix*. Although *Sporothrix brasiliensis* is the most frequent and pathogenic species identified from the Brazilian sporotrichosis hyperendemic, to the best of our knowledge this is the first report of its molecular diagnosis from a cat with ocular lesions. A 3-month-old female, domestic feline presented an ocular manifestation with granuloma in the lower-left palpebral conjunctiva, in addition to mucocutaneous lesions in varied locations throughout the body. Samples were collected for subsequent cytopathology, fungal culture, serology, and molecular genotyping. Itraconazole was prescribed for the treatment of sporotrichosis and the animal was considered clinically cured at the end of 5 months of treatment and discharged. *S. brasiliensis*-cat interactions can manifest with a multitude of clinical forms that resemble either infectious or noninfectious diseases. Both the need for meticulous cat physical evaluation by a veterinarian followed by accurate laboratory diagnosis are key Public Health measures in the Brazilian sporotrichosis hyperendemic area.

**Keywords:** Conjunctivitis. Granuloma. Mycosis. Public health. Sporotrichosis. Zoonosis.

### RESUMO

A esporotricose é uma dermatozoonose causada por fungos patogênicos dimórficos do gênero *Sporothrix*. Embora o *Sporothrix brasiliensis* seja a espécie mais patogênica e prevalente na hiperendemia brasileira de esporotricose, segundo nosso conhecimento este é o primeiro relato de um gato com lesões oculares causadas por esta espécie, via diagnóstico molecular. Um felino doméstico com três meses de idade apresentou manifestação ocular com granuloma em conjuntiva palpebral inferior esquerda, além de lesões mucocutâneas em diferentes áreas do corpo. Amostras foram coletadas para posterior citopatologia, cultura de fungos, sorologia e genotipagem molecular. O itraconazol foi prescrito para o tratamento da esporotricose e o animal foi considerado clinicamente curado ao final de cinco meses de tratamento, recebendo alta. As interações do *S. brasiliensis* com o gato podem se manifestar com uma infinidade de formas clínicas que se assemelham a doenças infecciosas ou não. A necessidade de avaliação física meticulosa desses animais por um médico veterinário, seguida do diagnóstico laboratorial preciso, são medidas essenciais em saúde pública na área hiperendêmica para a esporotricose no Brasil.

**Palavras-chave:** Conjuntivite. Granuloma. Micose. Saúde Pública. Esporotricose. Zoonose.

**Correspondence to:**

Andréa Regina de Souza Baptista  
 Universidade Federal Fluminense, Instituto Biomédico, Centro  
 de Investigação de Microrganismos  
 Bloco E, Alameda Barros Terra, s/nº, Salas 526/527  
 CEP: 24020 150, Niterói – RJ, Brazil  
 E-mail: andrearegina@id.uff.br

Received: March 17, 2021

Approved: May 11, 2021

**How to cite:** Mothé GB, Reis NF, Melivilu CSI, Mendes Junior AF, Santos CS, Dieckmann AM, Machado RLD, Rocha EMS, Baptista ARS. Ocular lesions in a domestic feline: a closer look at the fungal pathogen *Sporothrix brasiliensis*. *Braz J Vet Res Anim Sci.* 2021;58:e183219. <https://doi.org/10.11606/issn.1678-4456.bjvras.2021.183219>

## Introduction

Sporotrichosis is caused by dimorphic pathogenic fungi of the genus *Sporothrix*, widely distributed in nature (Rodrigues et al., 2020) while in the Brazilian scenario, *Sporothrix brasiliensis* plays a major role (Macêdo-Sales et al., 2020). Rio de Janeiro, Southeast Brazil, is a hyperendemic area for sporotrichosis affecting cats and humans, as well as other animals, and whose main form of transmission is zoonotic via domestic felines (Gremião et al., 2017; Pereira et al., 2014). From 1998-2015, the main referral center for the treatment of this mycotic disease, Oswaldo Cruz Foundation (FIOCRUZ) in Rio de Janeiro, recorded ≈5,000 human cases with almost the same number of animal cases (5,113) from 1998-2018 (Gremião et al., 2021). In parallel, for four years (2015-2019), the Reference Unit in Animal Sporotrichosis Diagnosis, Federal Fluminense University (UDEA-UFF) Niterói, Metropolitan Rio de Janeiro area, notified around 800 sporotrichosis suspicious feline patients, 56% were laboratory confirmed (unpublished data).

Recently, to contribute with professionals and health authorities facing the challenges to control this infection, the Brazilian committee on feline sporotrichosis published guidelines emphasizing the need to promptly diagnose and appropriately treat this mycosis (Gremião et al., 2020). The growing number of cases and the significant geographic expansion of this serious public health problem, not only within Brazil but also, recently, to Argentina, is a major concern (Etchecopaz et al., 2020; Orofino-Costa et al., 2017; Rodrigues et al., 2020).

Most frequently established as a dermatozoonosis, feline sporotrichosis can present as subacute to chronic manifestations, clinically divided into cutaneous fixed,

lymphocutaneous and/or cutaneous disseminated forms. Nevertheless, mucous and/or extracutaneous presentations are also reported (Schubach et al., 2004). The ophthalmic involvement in sporotrichosis can be considered an atypical presentation of the disease and can easily be misdiagnosed as other pathologies, including mycotic, such as cryptococcosis and histoplasmosis, in which ocular involvement is more frequent (Gremião et al., 2020; La Croix, 2005; Pereira et al., 2015).

To the best of our knowledge, this is the first report of a cat with ocular lesions caused by *S. brasiliensis*. This case will add information about the specific clinical-diagnostic approaches in the face of atypical sporotrichosis manifestations facilitating quick and accurate diagnosis.

## Case Report

A 3-month-old female, mixed-breed domestic feline, weighing 1.5 kg was attended at UDEA-UFF (Niterói, Metropolitan Region, Rio de Janeiro), with a history of facial lesions detected about a month after adoption. Disseminated cutaneous lesions, including on the face, body, and thoracic and pelvic limbs were evaluated during the physical clinical examination. The cat had facial erythematous and ulcerated cutaneous lesions, and also nasal swelling and nodules on the inner side of the pinna with pronounced eye edema (Figure 1A, B and C).

A thorough investigation allowed the visualization of a granulomatous lesion located in the inner face of the conjunctival sac, resulting in the eyelid edema, more precisely in the lower palpebral conjunctiva of the left eye (Figure 1B). Also, enlarged regional lymph nodes (mandibular lymph centers) were detected. The metatarsal region in the left pelvic limb (Figure 1D) and the digital cushions of the left thoracic limb (Figure 1E) were also affected.

Clinical specimens were collected from the lesions using imprint and sterile swab for cytopathology and fungal culture, respectively. From the eye granuloma, independent slide and swab samples were collected. One milliliter of peripheral blood was collected from the jugular vein. Cytopathology was conducted by impression smears prepared on clean and dry glass slides, subsequently stained by the quick panoptic method (Laborclin, Brazil), as previously described (Macêdo-Sales et al., 2018a). The slides were analyzed by light microscopy using 40X objective allowing the detection of numerous structures compatible with yeasts of *Sporothrix* spp., some internalized by phagocytes (Figure 2).

Diagnostic confirmation was carried out using thermal dimorphism and microculture tests. All swabs

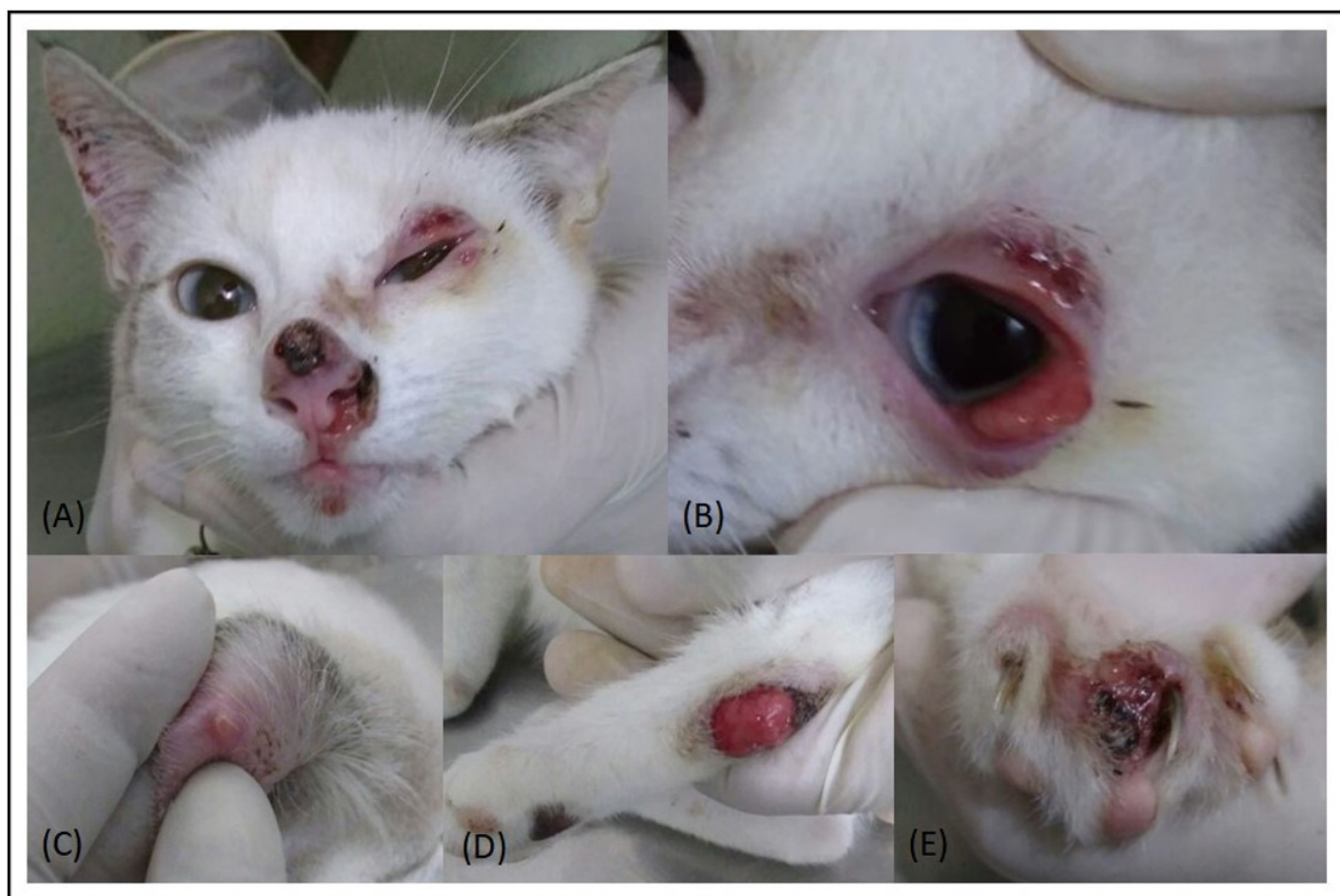

Figure 1 – Domestic feline diagnosed with cutaneous and mucosal disseminated sporotrichosis, showing: (A) erythematous, nodular and ulcerated skin lesions in face topography (nasal, ocular, and pinna); (B) Granulomatous lesion on the inner face of the conjunctival sac of the left eye; (C) Nodular lesion on the inner side of the ear; (D) Left metatarsal region and (E) Digital left pad of the thoracic limb.

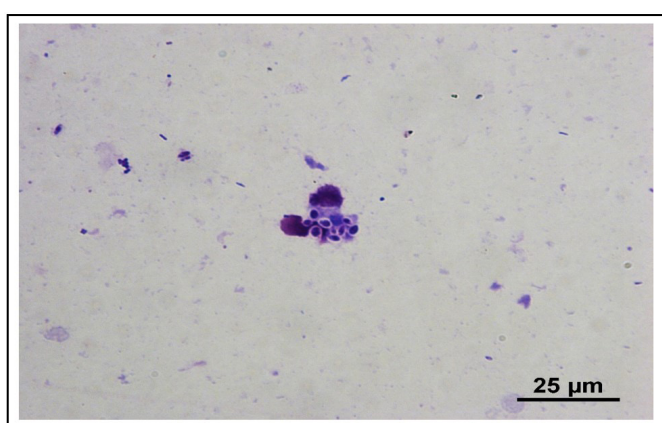


Figure 2 – Cytology by *imprint* from the feline eye granulomatous lesion, showing structures compatible with yeasts of *Sporothrix* spp., stained by the Rapid Panotic method (1000x).

(lesion exudates) were submitted to routine mycological processing, as described (Macêdo-Sales et al., 2018b). For microculture, the plates containing the colonies of the fungus in Potato Dextrose Agar medium (BD, New Jersey, EUA) were incubated at room temperature for 10 days,

followed by the evaluation of the micromorphology also characteristic of *Sporothrix* spp. (Macêdo-Sales et al., 2018b). Later, the dimorphism test was performed by subculturing filamentous colonies in brain-heart infusion agar (BHI; Becton Dickinson, USA) at 37°C, 7–10 days, for conversion to the yeast phase of *Sporothrix*.

Subsequently, this isolate was typed as *S. brasiliensis* by species-specific PCR targeting the calmodulin gene (*CAL*) as described by other studies (Macêdo-Sales et al., 2018b, 2020; Rodrigues et al., 2015). In parallel, IgG antibodies were detected by ELISA with the SsCBF antigen (*Sporothrix schenckii* ConA Binding Fraction) (Bernardes-Engemann et al., 2015) with adaptations (Baptista et al., 2021), resulting in a positive diagnosis.

Standard treatment was initiated with itraconazole at a dose of 30mg/cat according to the weight and age of the animal, every 24 h for 150 days. Monthly follow-ups were carried out and adjustments were made to the appropriate dose for the weight (reaching 100mg/cat when the patient exceeded 2.5 kg). Gradually, the lesions regressed and fully healed after 5 months of treatment.



## Discussion

Although sporotrichosis is primarily a dermatozoonosis, atypical clinical manifestations, such as the ocular manifestation described here, may occur (Schubach et al., 2004). Several case series or case reports of ocular sporotrichosis affecting human patients have previously been published (Arinelli et al., 2020; Lacerda et al., 2019; Ribeiro et al., 2020). Nevertheless, only two previous studies of ocular involvement in a domestic feline with this mycosis have been published (Silva et al., 2008; Spinelli et al., 2021). The first report describes a young cat (10-month-old) resident of the same Brazilian hyperendemic area and with a similar lesion pattern, both ocular and cutaneous (Silva et al., 2008). The second and most recent report discussed primary conjunctival sporotrichosis in three cats from Northeastern Brazil (Spinelli et al., 2021). However, in these two studies, they referred to the isolation of yeast belonging to the *Sporothrix schenckii* complex which, unfortunately, does not allow species determination (Rodrigues et al., 2015). Another difference between both reports is the drug of choice for treatment. Silva et al. (2008) prescribed cetoconazol while Spinelli et al. (2021) oral itraconazole. A recent Brazilian guideline advocates that itraconazole is the drug of election for feline sporotrichosis treatment (Gremião et al., 2020).

Interestingly, a parallel can be drawn between the clinical presentation of this cat's eye, pinna, and regional lymph nodes with the Parinaud's Oculoglandular Syndrome, a relatively frequent sporotrichosis presentation in humans (Ribeiro et al., 2010, 2020). Whether this similarity can be related to *S. brasiliensis* pathophysiology in both hosts has yet to be investigated. Ophthalmic alteration associated with sporotrichosis in humans without a history of trauma can be explained by the hematogenous spread of the fungus (Orofino-Costa et al., 2017). Likewise, the feline's eye lesion reported here may be the result of yeast hematogenous and/or lymphatic spreading (Gremião et al., 2020; Schubach et al., 2003). Finally, self-inoculation cannot be ruled out since this animal had other skin and mucosal lesions too.

*S. brasiliensis*-cat interactions can manifest with a multitude of clinical forms that resemble either infectious or noninfectious diseases (Gremião et al., 2020; Schubach et al., 2004). Squamous cell carcinoma, a neoplasm with a poor prognosis that mainly affects the domestic cat's facial area, can cause eye lesions, similar to those from sporotrichosis. Furthermore, cryptococcosis ocular lesions can occur with congestion of the retinal vessels, absence of pupillary reflex, and blindness. Likewise, histoplasmosis can manifest as granulomatous chorioretinitis, conjunctivitis, blepharospasm,

and ulcerated and nodular lesions in the eyelid mucocutaneous junctions (La Croix, 2005; Pereira et al., 2015).

Some of the most severe fungal infections may require a combination of laboratory investigation methods to offer a precise diagnosis. Unfortunately, we were not able to perform hematological and biochemical laboratory tests as well as FIV/FELV testing due to the owner's considerable financial constraints. After fungal culture, a species-specific PCR approach was used allowing identification of *S. brasiliensis*. This can be important since this species was previously associated with higher virulence and reduced susceptibility to azoles (Della-Terra et al., 2017; Macêdo-Sales et al., 2020).

Frequently in Brazilian hyperendemia, cats presented to the outpost clinic have been mistreated in terms of the drug and dose used. This can compromise *Sporothrix* culture isolation, a method considered the gold standard for diagnosis (Macêdo-Sales et al., 2018a). In these situations, serological tools such as the anti-SsCBF ELISA can be very important. The *S. brasiliensis* domestic feline reported here had an IgG titer compatible with a sporotrichosis positive diagnosis. Therefore, as previously described by our group (Baptista et al., 2021), this method could be applied for therapeutic follow-up, an important approach in severe cases.

A rare and atypical clinical case of sporotrichosis can make the diagnosis challenging, mainly due to the possibilities of differential diagnoses and the scarcity of literature. Hopefully, taken together this present case and the two previous reports will draw attention to the possibility of eye injury accompanied or not by skin involvement in sporotrichosis. The need for meticulous cat physical evaluation by a veterinarian, followed by accurate laboratory diagnosis, are key Public Health measures in the Brazilian sporotrichosis hyperendemic area.

## Conflict of Interest

No conflicts of interest have been declared by the other authors.

## Ethics Statement

This study was approved and conducted according to the norms of the Ethics Committee on Animal Use from the Federal Fluminense University (CEUA-UFF, protocol number 7561040518/2018).

## Acknowledgments

The authors would like to thank the veterinarian collaborators and the cat tutors for allowing their animals to take part in this study. We also thank Dr. Pâmella Antunes de Macêdo-Sales, for assisting on *Sporothrix* spp. genotyping. We are grateful to

Dr. Norman Ratcliffe for English Language reviewing of the manuscript. The authors also thank the National Council for Scientific and Technological Development (CNPq) for granting fellowships (PQ-CNPq to RLDM and ARSB) and the Rio de

Janeiro Research Foundation (FAPERJ; E-26/010.001882/2014). Also, this study was financed in part by the Coordination for the Improvement of Higher Education Personnel - Brazil (CAPES) - Finance Code 001 and PROEX-MEC.

## References

Arinelli A, Aleixo AL, Freitas DF, do Valle ACF, Almeida-Paes R, Gutierrez-Galhardo MC, Curi ALL. Ocular Sporotrichosis: 26 cases with bulbar involvement in a hyperendemic area of zoonotic transmission. *Ocul Immunol Inflamm.* 2020;28(5):764-71. <http://dx.doi.org/10.1080/09273948.2019.1624779>. PMID:31411512.

Baptista VS, Mothé GB, Santos GMP, Melivilu CSI, Santos TO, Virginio ED, de Macêdo-Sales PA, Pinto MR, Machado RLD, Rocha EMS, Lopes-Bezerra LM, Baptista ARS. Promising application of the SsCBF ELISA test to monitor the therapeutic response of feline sporotrichosis caused by *Sporothrix brasiliensis* from Brazilian epidemics. *Braz J Microbiol.* 2021;52(1):145-53. PMID:32812211.

Bernardes-Engemann AR, de Lima Barros M, Zeitune T, Russi DC, Orofino-Costa R, Lopes-Bezerra LM. Validation of a serodiagnostic test for sporotrichosis: a follow-up study of patients related to the Rio de Janeiro zoonotic outbreak. *Med Mycol.* 2015;53(1):28-33. <http://dx.doi.org/10.1093/mmy/myu058>. PMID:25477075.

Della-Terra PP, Rodrigues AM, Fernandes GF, Nishikaku AS, Burger E, De Camargo ZP. Exploring virulence and immunogenicity in the emerging pathogen *Sporothrix brasiliensis*. *PLoS Negl Trop Dis.* 2017;11(8):e0005903. <http://dx.doi.org/10.1371/journal.pntd.0005903>. PMID:28854184.

Etchecopaz A, Scarpa M, Mas J, Cuestas M. *Sporothrix brasiliensis*: a growing hazard in the Northern area of Buenos Aires Province. *Rev Argent Microbiol.* 2020;52(4):350-1. <http://dx.doi.org/10.1016/j.ram.2020.02.002>. PMID:32192862.

Gremião ID, Miranda LHM, Reis EG, Rodrigues AM, Pereira SA. Zoonotic epidemic of sporotrichosis: cat to human transmission. *PLoS Pathog.* 2017;13(1):e1006077. <http://dx.doi.org/10.1371/journal.ppat.1006077>. PMID:28103311.

Gremião ID, Oliveira MME, Monteiro de Miranda LH, Saraiva Freitas DF, Pereira SA. Geographic Expansion of Sporotrichosis, Brazil. *Emerg Infect Dis.* 2020;26(3):621-4. <https://doi.org/10.3201/eid2603.190803>. PMID: 32091376.

Gremião IDE, Martins da Silva da Rocha E, Montenegro H, Carneiro AJB, Xavier MO, de Farias MR, Monti F,

Mansho W, de Macedo Assunção Pereira RH, Pereira SA, Lopes-Bezerra LM. Guideline for the management of feline sporotrichosis caused by *Sporothrix brasiliensis* and literature revision. *Braz J Microbiol.* 2021;52(1):107-24. <http://dx.doi.org/10.1007/s42770-020-00365-3>. PMID:32990922.

La Croix NC. Ocular manifestations of systemic disease in cats. *Clin Tech Small Anim Pract.* 2005;20(2):121-8. <http://dx.doi.org/10.1053/j.ctsap.2004.12.017>. PMID:15948427.

Lacerda AM Fo, Cavalcante CM, Da Silva AB, Inácio CP, de Lima-Neto RG, de Andrade MCL, Magalhães OMC, Dos Santos FAG, Neves RP. High-virulence cat-transmitted ocular Sporotrichosis. *Mycopathologia.* 2019;184(4):547-9. <http://dx.doi.org/10.1007/s11046-019-00347-6>. PMID:31230198.

Macêdo-Sales PA, Souto SRLS, Destefani CA, Lucena RP, Rocha SEM, Baptista ARS. Diagnóstico laboratorial da esporotricose felina em amostras coletadas no estado do Rio de Janeiro, Brasil: limitações da citopatologia por *imprint*. *Rev Pan-Amazônica Saúde.* 2018a;9(2). <http://dx.doi.org/10.5123/S2176-62232018000200002>.

Macêdo-Sales PA, Souto SRLS, Destefani CA, Lucena RP, Machado RLD, Pinto MR, Rodrigues AM, Lopes-Bezerra LM, Rocha EMS, Baptista ARS. Domestic feline contribution in the transmission of *Sporothrix* in Rio de Janeiro State, Brazil: a comparison between infected and non-infected populations. *BMC Vet Res.* 2018b;14(1):19. <http://dx.doi.org/10.1186/s12917-018-1340-4>. PMID:29347940.

Macêdo-Sales PA, Souza LOP, Della-Terra PP, Lozoya-Pérez NE, Machado RLD, Rocha EMDSD, Lopes-Bezerra LM, Guimarães AJ, Rodrigues AM, Mora-Montes HM, Santos ALS, Baptista ARS. Coinfection of domestic felines by distinct *Sporothrix brasiliensis* in the Brazilian sporotrichosis hyperendemic area. *Fungal Genet Biol.* 2020;140:103397. <http://dx.doi.org/10.1016/j.fgb.2020.103397>. PMID:32325170.

Orofino-Costa R, Macedo PM, Rodrigues AM, Bernardes-Engemann AR. Sporotrichosis: an update on epidemiology, etiopathogenesis, laboratory and clinical therapeutics. *An Bras Dermatol.* 2017;92(5):606-20. <http://dx.doi.org/10.1590/abd1806-4841.2017279>. PMID:29166494.

- Pereira SA, Gremião IDF, Kitada AAB, Boechat JS, Viana PG, Schubach TMP. The epidemiological scenario of feline sporotrichosis in Rio de Janeiro, State of Rio de Janeiro, Brazil. *Rev Soc Bras Med Trop*. 2014;47(3):392-3. <http://dx.doi.org/10.1590/0037-8682-0092-2013>. PMID:25075494.
- Pereira SA, Gremião IDF, Menezes RC. Sporotrichosis in animals: zoonotic transmission. In: Carlos IZ, editor. *Sporotrichosis. New developments and future prospects*. USA: Springer; 2015, pp. 83-102.
- Ribeiro ASA, Bisol T, Menezes MS. Síndrome oculoglandular de Parinaud causada por esporotricose. *Rev Bras Oftalmol*. 2010;69(5):317-22. <http://dx.doi.org/10.1590/S0034-72802010000500008>.
- Ribeiro CR, Silva BP, Almeida Costa AA, Basile A No, Vieira LA, Lima MA, Lima MHC. Ocular Sporotrichosis. *Am J Ophthalmol Case Rep*. 2020;19:100865. <http://dx.doi.org/10.1016/j.ajoc.2020.100865>. PMID:32885097.
- Rodrigues AM, de Hoog GS, de Camargo ZP. Molecular diagnosis of pathogenic *Sporothrix* species. *PLoS Negl Trop Dis*. 2015;9(12):e0004190. <http://dx.doi.org/10.1371/journal.pntd.0004190>. PMID:26623643.
- Rodrigues AM, Della Terra PP, Gremião ID, Pereira SA, Orofino-Costa R, de Camargo ZP. The threat of emerging and re-emerging pathogenic *Sporothrix* species. *Mycopathologia*. 2020;185(5):813-42. <http://dx.doi.org/10.1007/s11046-020-00425-0>. PMID:32052359.
- Schubach TM, Schubach A, Okamoto T, Barros MB, Figueiredo FB, Cuzzi T, Fialho-Monteiro PC, Reis RS, Perez MA, Wanke B. Evaluation of an epidemic of sporotrichosis in cats: 347 cases (1998-2001). *J Am Vet Med Assoc*. 2004;224(10):1623-9. <http://dx.doi.org/10.2460/javma.2004.224.1623>. PMID:15154732.
- Schubach TM, Schubach A, Okamoto T, Pellon IV, Fialho-Monteiro PC, Reis RS, Barros MB, Andrade-Perez M, Wanke B. Haematogenous spread of *Sporothrix schenckii* in cats with naturally acquired sporotrichosis. *J Small Anim Pract*. 2003;44(9):395-8. <http://dx.doi.org/10.1111/j.1748-5827.2003.tb00174.x>. PMID:14510328.
- Silva DT, Pereira SA, Gremião IDF, Chaves AR, Cavalcanti MCH, Silva JN, Schubach TMP. Esporotricose conjuntival felina. *Acta Sci Vet*. 2008;36(2):181-4. <http://dx.doi.org/10.22456/1679-9216.17283>.
- Spinelli TP, Bezerra LM, Souza BOF, Rocha A, Neto JE, Sá FB. Primary conjunctival sporotrichosis in three cats from Northeastern Brazil: case report. *Vet Ophthalmol*. 2021;24(2):209-15. <http://dx.doi.org/10.1111/vop.12865>. PMID:33608958.

---

**Financial Support:** The authors would like to thank the National Council for Scientific and Technological Development (Conselho Nacional de Desenvolvimento Científico e Tecnológico—CNPq) for granting fellowships (ARSB and RLDM are research fellows of CNPq - PQ/CNPq) and the Rio de Janeiro Research Foundation (Fundação de Amparo à Pesquisa do Estado do Rio de Janeiro—FAPERJ (E-26/010.001882/2014)). Also, it was financed in part by the Coordenação de Aperfeiçoamento de Pessoal de Nível Superior—Brasil (CAPES) Finance Code 001 and PROEX-MEC.