

## The structure of the liver of captive lion-tamarins (*Callitrichidae, Primates*): a stereologic approach

Carlos Henrique de Freitas BURITY<sup>1</sup>  
Alcides PISSINATTI<sup>2,3,4</sup>  
Carlos Alberto MANDARIM-DE-LACERDA<sup>5</sup>

1- Universidade do Grande Rio (Unigranrio), Duque de Caxias - RJ  
2- Centro Universitário Plínio Leite (UNIPLI), Itaboraí - RJ  
3- Fundação Educacional Serra dos Órgãos (FESO), Teresópolis - RJ  
4- Centro de Primatologia do Rio de Janeiro (CPRJ-FEEMA), Guapimirim - RJ  
5- Universidade Estadual do Rio de Janeiro, Rio de Janeiro - RJ

### Correspondence to:

CARLOS HENRIQUE FREITAS BURITY  
Universidade do Grande Rio (Unigranrio)  
Instituto de Biociências – Setor de Morfologia  
Rua Prof. José de Souza Herdy, 1160  
25071-200 - Duque de Caxias – RJ  
cburity@unigranrio.com.br

Received: 14/11/2003  
Accepted: 13/07/2005

### Abstract

Studies on liver morphology and stereology are relevant to the comparative anatomical and pathological research. They also facilitate the use of nonhuman primates in basic research, which has substantially supported studies in human medicine. Quantitative studies of liver structures have also been more extensive in Old World primates and other vertebrates. Twenty-three livers of adult lion tamarins were studied (06 *Leontopithecus rosalia*, 07 *Leontopithecus chrysomelas*, and 10 *Leontopithecus chrysopygus*), dissected, and fixed in 10% neutral buffered formalin solution. For stereological quantification, the liver was regarded as consisting of parenchyma (hepatocytes) and stroma (nonhepatocytes). The stereologic parameter volume density ( $V_v$ ) was determined by point counting, using M42 test-system. Hepatic stereological differences among the three species of lion tamarins were not statistically significant. Therefore, the pooled  $V_{V[\text{hepatocyte}]}$  and  $V_{V[\text{stroma}]}$  could be determined as 96.2% and 7.4%, respectively. Significantly different, the values found for  $V_{V[\text{hepatocyte}]}$  in lion tamarins were 0.09 times greater than those in baboons, and 0.17 in man. However, the  $V_{V[\text{stroma}]}$  was 1.04 times smaller than that in baboons and 1.79 times smaller than that in man. The differences found among the rates studied, even if not proven statistically, point out to the need for further studies to correlate the morphological and physiological features of those tamarins.

### Key-words

Tamarins.  
*Leontopithecus*.  
Liver.  
Stereology.

### Introduction

The *Leontopithecus* genus (Lesson, 1840) includes four recognized species: the golden lion tamarin *Leontopithecus rosalia* (Linnaeus, 1766), the golden-headed lion tamarin *Leontopithecus chrysomelas* (Kuhl, 1820), the black lion tamarin *Leontopithecus chrysomelas* (Mikan, 1823), and the black-faced lion tamarin *Leontopithecus caissara* (Persson & Lorini, 1990)<sup>1</sup>. They are the largest Callitrichid species occupying the isolated remnants of the Atlantic Forest in Brazil. Three of them have been considered “critically endangered” by the IUCN Species Survival Commission<sup>2,3,4</sup>: *Leontopithecus rosalia* in the state of Rio de Janeiro; *Leontopithecus chrysopygus* in the state of São Paulo; and

*Leontopithecus chrysomelas*, restricted to the forests of the southern region of the state of Bahia. Concern regarding the survival of these primates<sup>1,5,6,7,8,9,10</sup> has given rise to major research, management (including reintroduction of captive born animals), and environmental education programs over the last two decades<sup>11,12</sup>. There are captive breeding programs for all lion tamarins, except *Leontopithecus caissara*<sup>13,14,15</sup>.

Unfortunately, very few studies on the morphological and stereological aspects of New World monkeys have been published<sup>16,17,18</sup>. Quantitative studies of liver structures have also been more extensive in Old World primates and other vertebrates as follows: Primates<sup>19,20,21,22,23,24</sup>, rat<sup>25,26,27,28</sup>, and *Salmo*<sup>29,30</sup>.

Studies on liver morphology and stereology are relevant to the comparative anatomical and pathological research. They also facilitate the use of nonhuman primates in basic research, which has substantially supported studies in human medicine<sup>31</sup>.

The purpose of the present study was to establish quantitative data in the liver of *Leontopithecus*, and thus contribute to this branch of morphological and clinical knowledge, as well as to the health control in *in situ* and *ex situ* colonies.

## Materials and Methods

Lion tamarins from the Center of Primatology of Rio de Janeiro (CPRJ-FEEMA) were studied. The facility is located 100 km northeast of the city of Rio de Janeiro, in a protected forest area of the Serra dos Órgãos mountain range. At this facility, the animals were housed in groups and the enclosures were located outdoors, being, thus, exposed to the Atlantic Forest conditions (e.g., sounds, temperature, and rainfall). The enclosures measured 6.0 x 3.0 x 2.5 meters. The south wall of each was made of concrete, and the other three walls were made of wire mesh. Food and fresh water were provided twice a day. The diet consisted of bread, bananas, eggs, raisins, meat, various commercially prepared protein supplements, and invertebrate larvae<sup>32</sup>.

The samples were obtained from 23 tamarins (all adults) kept in the museum collection of the CPRJ-FEEMA as follows: 06 *Leontopithecus rosalia* (01 female), 07 *Leontopithecus chrysomelas* (all males), and 10 *Leontopithecus chrysopygus* (03 females). Therefore, the sex and age of the animals born in captivity or born in the wild, but monitored in their natural environment, were known.

Fragments were taken from the liver fixed in 10% formalin and processed in 5- $\mu$ m-thick paraffin sections. The sections were stained in hematoxylin-eosin (H-E).

Fifteen random fields were studied in each specimen. Counting was carried out

using a M42 testing system mounted in a Nikon CFW eyepiece (x10) and an objective (N Plan, 40x/1.25). The M42 testing system<sup>33, 34</sup>, which has 21 straight-line segments and 42 testing points in a testing area (*At*) equal to 36.36 d<sup>2</sup>, was used for microscopic examination and morphometric measurements.

For stereological quantification, the liver was regarded as consisting of parenchyma (hepatocytes) and stroma (nonhepatocytes). The volume density ( $V_V$ ) was determined from the points lying over these structures. The  $V_V$ <sup>[hepatocyte]</sup> comprised the hepatocyte nuclei and the  $V_V$ <sup>[connective tissue]</sup> comprised the connective tissue, cells other than hepatocytes, and nerves. The volume densities of these structures were calculated using the following formula<sup>33</sup>:

$$V_V = \frac{P_{structure}}{P_{Test}} \% \quad \text{where: } P_{structure} \text{ denotes the number of points over the structure and } P_{Test} \text{ represents the total number of test points, 42 in this case - (M 42).}$$

Quantitative differences in stereological parameters between species were tested with the nonparametric unpaired Mann-Whitney-U test (two-tailed test,  $\alpha=0.05$ ). This test combined and ranked data from the two samples. The ranks were added together, and a mean for each parameter in each sample was calculated. The mean ranks were then compared through statistic calculation<sup>35</sup>.

## Results

Microscopically, the liver of *Leontopithecus* is mainly formed by a compact mass of hepatocytes, some of which binucleated, with interspersed sinusoids and islands of connective tissue containing bile ducts, and venous and arterial vessels (Figure 1).

The descriptive statistics of the stereological parameters and the comparisons between species are shown in table 1. In regard to the  $V_V$ <sup>[hepatocyte]</sup> *Leontopithecus chrysomelas* is 0.021 and 0.053 times greater than *Leontopithecus chrysopygus* and *Leontopithecus rosalia*, respectively. On the other hand, in

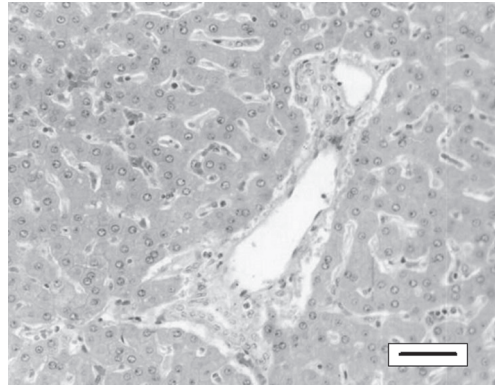
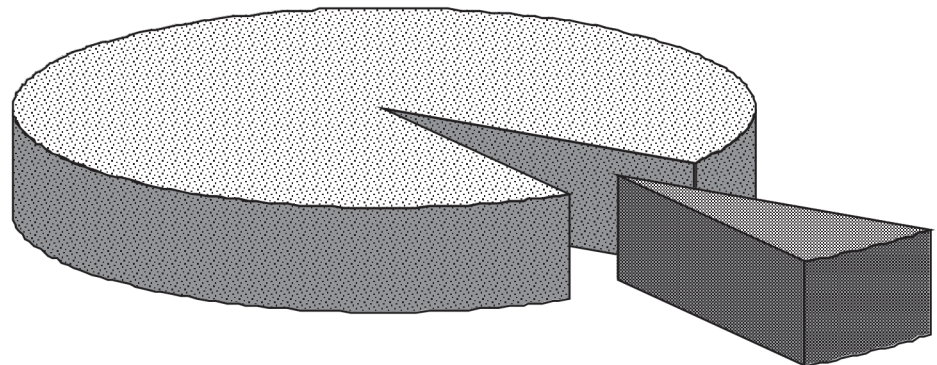


Figure 1 - Overview of the lion tamarin liver on light microscopy. Male of *Leontopithecus rosalia*; Hematoxylin-eosin, bar = 30mm

regard to the stroma, the magnitude sequence was not maintained for all three species, i.e., *Leontopithecus rosalia* is 0.94 and 0.39 times greater than *Leontopithecus chrysomelas* and *Leontopithecus chrysopygus*, respectively. However, no quantitatively significant difference was detected in this stereological parameters in the liver, when comparing these three species.

In this study, hepatic stereological differences among the three species of lion tamarins were not statistically significant. Therefore, the pooled  $V_v$  could be determined as shown in figure 2.

$V_v$  parenchyma  
92.6



$V_v$  stroma  
7.4

Figure 2 - A sector graph showing: the mean  $V_v$  [parenchyma] (%) and  $V_v$  [stroma] (%) in the lion tamarin liver (*Leontopithecus*)

### Discussion

Carrière et al.<sup>19</sup> studied six baboon livers (*Papio papio*) and established some stereological parameters in the liver parenchyma and stroma. In the baboon, the stereological parameters for parenchyma and stroma were smaller than those in the lion tamarin. In the baboon,  $V_v$  [hepatocyte] was 84.9% and  $V_v$  [stroma] was 15.1%.

In man, a stereological study of liver biopsies from healthy volunteers reported the following:  $V_v$  [hepatocyte] of 79.3% and  $V_v$  [stroma] of 20.7%<sup>23</sup>.

The values found for  $V_v$  [hepatocyte] in lion tamarins were 0.09 times greater than those in baboons, and 0.17 times greater than those in man. However, the  $V_v$  [stroma] was 1.04 times smaller than that in baboons and 1.79 times smaller than that in man. The differences between lion tamarins and baboons and between lion tamarins and man are highly significant ( $p < 0.01$ , Figure 3).

Only adult animals with sex-pooled samples (except for *Leontopithecus chrysomelas* – all males) were studied. No sex-related differences in parameters were observed, as in previous studies with baboons<sup>19</sup>, man<sup>23</sup>, and brown trout<sup>30</sup>.

Table 1 - Descriptive statistics for stereological parameters volume density (mean  $\pm$  standard error of the mean). All comparisons between species were not statistically significant ( $p > 0.05$ ) using Mann-Whitney test

	<i>L. rosalia</i> (n = 06)	<i>L. chrysomelas</i> (n = 07)	<i>L. chrysopygus</i> (n = 10)
The volume density – Vv (%)			
Hepatocyte	90.1 $\pm$ 2.1	94.9 $\pm$ 1.4	92.9 $\pm$ 1.3
Stroma	9.9 $\pm$ 2.1	5.1 $\pm$ 1.4	7.1 $\pm$ 1.3

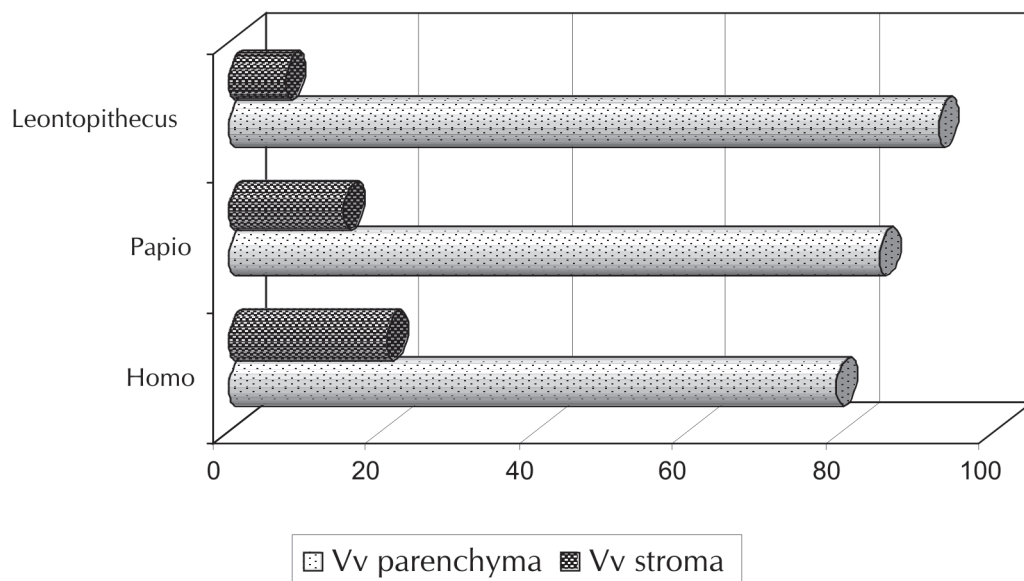


Figure 3 - A error-bar graph comparing the mean  $V_{v[\text{parenchyma}]}$  (%) and  $V_{v[\text{stroma}]}$  (%) in man (*Homo*), baboon (*Papio*) and lion tamarin (*Leontopithecus*). All differences are statistically significant ( $p < 0,01$ )

The present study was performed on lion tamarins under captive conditions. However, interference with the action of drugs or metabolic disturbances due to underlying diseases or stress may render interpretation of liver stereological findings difficult.

The study on liver stereology in Neotropical primates, are scarce in the literature, which may explain the difficulty in comparing data in this investigation.

The differences found among the rates studied, even if not proven statistically, point out to the need for further studies to correlate the

morphological and physiological features of those tamarins. This study also demonstrates the importance of knowledge to support more appropriate clinical examination of those tamarins.

### Acknowledgments

The authors thank the Brazilian Federal Public Ministry (RJ) for supporting several phases of this study and the conservation of Neotropical Primates at CPRJ-FEEMA. This study was supported by a grant from Faperj (C.H.F.B. 170-873/00 and A.P. 171-573/00).

### A estrutura do fígado de micos-leões de cativeiro (*Callithrichidae, Primates*): uma abordagem estereológica

#### Resumo

Estudos sobre a morfologia e estereologia hepática são relevantes em

#### Palavras-chave

Micos.  
*Leontopithecus*.

pesquisa de anatomia e patologia comparada. Estes também facilitam o uso de primatas não-humanos como modelos experimentais em pesquisa básica, fato que tem auxiliado os estudos em medicina humana. Estudos quantitativos de estruturas hepáticas também têm sido mais prevalentes em Primatas do Velho Mundo e outros vertebrados. Foram estudados vinte e três fígados de micos-leões adultos, sendo : 06 *Leontopithecus rosalia*, 07 *Leontopithecus chrysomelas* e 10 *Leontopithecus chrysopygus*, os quais foram dissecados e fixados com formol tamponado a 10%. Para a quantificação estereológica, o fígado foi considerado como consistindo de parênquima (hepatócitos) e estroma (não-hepatócitos). O parâmetro estereológico densidade de volume (Vv) foi determinado por contagem de pontos, utilizando-se do sistema teste M42. As diferenças estereológicas hepáticas entre as três espécies de micos-leões não foram estatisticamente significativas. Portanto, um valor único de  $V_v^{[hepatócito]}$  e  $V_v^{[estroma]}$  podem ser determinados como 96,2% e 7,4%, respectivamente. Significativamente diferente, os valores encontrados para o  $V_v^{[hepatócito]}$  em micos-leões foram 0,09 vez maior do que em babuínos, e 0,17 em humanos. Contudo, o  $V_v^{[estroma]}$  foi 1,04 vez menor do que o de babuínos e 1,79 vez menor do que o de humanos. As diferenças encontradas entre as proporções estudadas, mesmo que não comprovadas estatisticamente, mostram a necessidade de estudos futuros para correlacionar os aspectos morfo-fisiológicos destes micos.

Fígado.  
Estereologia.

## References

- 1 COIMBRA-FILHO, A. F. Sistemática, distribuição geográfica e situação atual dos símios brasileiros (Platyrrhini – Primates). **Revista Brasileira de Biologia**, v. 50, p. 1063-1079, 1990.
- 2 IUCN. **Red list of threatened animals**. Gland Switzerland: The World Conservation Union Gland: IUCN, 1996. 254 p.
- 3 ROSEMBERGER, A. L.; COIMBRA-FILHO, A. F. Morphology, taxonomic status and affinities of the lion tamarins, *Leontopithecus* (Callitrichidae, Cebidae). **Folia Primatologica**, v. 42, p. 149-179, 1984.
- 4 RYLANDS, A. B.; COIMBRA-FILHO, A. F.; MITTERMEIER, R. A. Systematics, geographic distribution and some notes on the conservation status of the Callitrichidae. In: RYLANDS, A. B. **Marmosets and tamarins systematics, behaviour, and ecology**. Oxford: Science Publications, 1993. p. 11-77.
- 5 COIMBRA-FILHO, A. F. Mico leão, *Leontideus rosalia* (Linnaeus, 1766) situação da espécie no Brasil. **Anais da Academia Brasileira de Ciências**, v. 41, p. 29-52, 1969. Suplemento.
- 6 COIMBRA-FILHO, A. F. Acerca da redescoberta de *Leontopithecus chrysomelas* (Mikan, 1823) e apontamentos sobre a ecologia. **Revista Brasileira de Biologia**, v. 30, p. 609-615, 1970a.
- 7 COIMBRA-FILHO, A. F. Considerações gerais e situação atual dos micos-leões escuros, *Leontideus chrysomelas* (Kuhl, 1820) e *Leontideus chrysopygus* (Mikan, 1823). **Revista Brasileira de Biologia**, v. 30, p. 249-268, 1970b.
- 8 COIMBRA-FILHO, A. F.; MAIA, A. A. Alimentação de sagüis em cativeiro. **Brasil Florestal**, v. 29, p. 15-26, 1977.
- 9 COIMBRA-FILHO, A. F.; MITTERMEIER, R. A. Taxonomy of the genus *Leontopithecus* (Lesson, 1840). In: BRIDGEWATER, D. **Saving the Lion Tamarin**. West Virginia: Wild Animal Propagation Trust, 1972. p. 7-22.
- 10 COIMBRA-FILHO, A. F.; MITTERMEIER, R. A. Distribution and ecology of the genus *Leontopithecus* in Brazil. **Primates**, v. 14, p. 47-66, 1973.
- 11 BECK, B. B. et al. Losses and reproduction in reintroduced golden lion tamarins *Leontopithecus rosalia*. **Dodo Journal of Jersey Wildlife Preservation Trust**, v. 27, p. 50-61, 1991.
- 12 KENNEDY, S. J. Ultrastructure of normal monkey liver. **Laboratory Animals**, v. 13, p. 125-129, 1979.
- 13 BALLOU, J. D. Emergence of the captive population of golden-headed lion tamarins *Leontopithecus chrysomelas*. **Dodo Journal of Jersey Wildlife Preservation Trust**, v. 26, p. 70-77, 1989.
- 14 BALLOU, J. D.; LACY, R. C.; ELLIS, S. (Comp.). **Leontopithecus II: the second population and habitat viability assessment for lion tamarins (*Leontopithecus*)**. Minnesota, Apple Valley: IUCN/SSC Conservation

- Breeding Specialist Group (CBSG), 1997.
- 15 BALLOU, J. D.; SHERR, A. **1996 International studbook golden lion tamarin *Leontopithecus rosalia***. Washington, DC: National Zoological Park, 1997.
- 16 BURITY, C. H. F.; MANDARIM-DE-LACERDA, C. A.; PISSINATTI, A. Stereology of the myocardium in two species of *Callithrix* (Callitrichidae, *Primates*). **Annals of Anatomy**, v. 178, p. 437-441, 1996.
- 17 PISSINATTI, A.; BURITY, C. H. F.; MANDARIM-DE-LACERDA, C. A. Morphological and morphometric age-related changes of the upper thoracic aorta in *Leontopithecus* (Lesson, 1840) (Callitrichidae – *Primates*). **Journal of Medical Primatology**, v. 29, p. 421-426, 2000.
- 18 PISSINATTI, A.; BURITY, C. H. F.; MANDARIM-DE-LACERDA, C. A. Stereology of the myocardium in *Leontopithecus* (Lesson, 1840) Callitrichidae – *Primates*. **Journal of Medical Primatology**, v. 32, p. 139-147, 2003.
- 19 CARRIÈRE, D. et al. Analyse stéréologique du parenchyma hepatic chez le singe babouin (*Papio papio*). **Archives D'Anatomie Microscopie**, v. 69, p. 267-280, 1980.
- 20 CASALLI, A. M. et al. Quantitative analysis of intrahepatic bile duct component in normal adult human liver and in primary biliary cirrhosis. **Pathology Research Practice**, v. 190, p. 201-206, 1994.
- 21 CHAGULA, W. K. The liver of the mountain gorilla (*Gorilla gorilla beringei*). **American Journal Physical Anthropology**, v. 19, p. 309-315, 1961.
- 22 KLEIMAN D. G. et al. Conservation program for the golden lion tamarin: captive research and management: ecological studies, educational strategies, and reintroduction. In: BENIRSCHKE, K. **Primates: The road to self-sustaining populations**. New York: Springer, 1986. p. 959-979.
- 23 ROHR, H. P. et al. Stereology of liver from healthy volunteers. **Virchows Archives**, v. 371, p. 251-263, 1976.
- 24 TANUMA, Y. Occurrence of crystalloids in the sinusoidal endothelium of a crab-eating monkey liver. **Archives of Histology Japan**, v. 46, p. 523-531, 1983.
- 25 CARTHEW, P. et al. Method for determining whether the number of hepatocytes in rat liver is increased after treatment with the peroxisome proliferator gemfibrozil. **Journal Applied Toxicology**, v. 17, p. 47-51, 1996.
- 26 JONES, A. L. et al. Morphometric analysis of rat hepatocytes after total biliary obstruction. **Gastroenterology**, v. 71, p. 1050-1060, 1976.
- 27 LOUD, A. V. A quantitative stereological description of the ultrastructure of normal liver parenchymal cells. **Journal of Cell Biology**, v. 37, p. 27-46, 1968.
- 28 VASSY, J. et al. Development of the fetal rat liver: ultrastructural and stereological study of hepatocytes. **Cellular Differentiation**, v. 24, p. 9-24, 1988.
- 29 ROCHA, E.; MONTEIRO, R. A. F.; PEREIRA, C. A. Microanatomic organization of hepatic stroma of the Brown trout, *Salmo trutta fario* (Teleostei, Salmonidae): a qualitative and quantitative approach. **Journal Morphology**, v. 223, p. 1-11, 1995.
- 30 ROCHA, E.; MONTEIRO, R. A. F.; PEREIRA, C. A. Liver of the Brown trout; *Salmo trutta* (Teleostei, Salmonidae): A stereological study at light and electron microscopic levels. **Anatomical Records**, v. 247, p. 317-28, 1997.
- 31 HELD, J. R. Appropriate animal models. In: SECHZER, J. A. **The role of animals in biomedical research**. New York: Annals of New York Academic Science, p.13-19, 1983.
- 32 COIMBRA-FILHO, A. F.; SILVA, R. R.; PISSINATTI, A. Sobre a dieta de Callitrichidae em cativeiro. **Revista Biotérios**, v. 1, p. 83-93, 1981.
- 33 WEIBEL, E. R. **Stereological methods**. Practical methods for biological morphometry. London: Academic Press, 1979. 279 p.
- 34 WEIBEL, E. R.; KISTLER, G. S.; SCHERLE, W. F. Practical stereological methods for morphometric cytology. **Journal of Cell Biology**, v. 30, p. 23-28, 1966.
- 35 ZAR, H. **Biostatistical analysis**. Englewood Cliffs: Prentice Hall, 1984. 718 p.