

## Patterns of shedding of cryptosporidial oocysts by ewes and lambs kept indoors

Renata Elisa GREEN<sup>1</sup>;  
Alessandro Francisco  
Talamini do AMARANTE<sup>1</sup>;  
Luciene Maura MASCARINI<sup>1</sup>

1 - Departamento de Parasitologia, Instituto de Biociências, Universidade  
Estadual Paulista, Botucatu - SP

### Abstract

This study was carried out to determine the pattern of shedding of cryptosporidial oocysts by lambs and their dams kept indoors from lambing to weaning in Botucatu, São Paulo State, Brazil. A group of 20 Ile de France ewes in late pregnancy was housed in a facility with concrete floor. The concrete floor was cleaned daily and vigorously washed three times per week. Lambing occurred in August and September/2001. Fecal samples were taken from ewes and lambs on the day of the lambing, 4, 8, 16, 32 and 64 days after lambing. Samples were processed using a centrifuge-sedimentation technique in ether. Fecal smears were stained with auramine O and by Ziehl-Neelsen modified technique. The overall percentages of fecal samples of lambs and ewes positives for *Cryptosporidium* oocysts were 26.7% and 31.9%, respectively ( $P>0.05$ ). Four of the 20 lambs and two of the 20 ewes did not shed oocysts in any of the faecal samples examined. The highest percentage of positive samples occurred in 4-day-old lambs. In ewes a peak in the percentage of positive samples occurred 4 days after lambing. Despite the relative high rate of animal shedding oocysts in feces, the cryptosporidial infection was asymptomatic in all ewes and lambs.

### Key-words:

*Cryptosporidium*.  
Sheep.  
Lamb.  
Transmission.

**Correspondência para:**  
ALESSANDRO FRANCISCO TALAMINI  
DO AMARANTE  
Departamento de Parasitologia  
Instituto de Biociência - UNESP  
Caixa Postal 510  
18618-000 - Botucatu - SP  
amarante@ibb.unesp.br

Received: 22/09/2003  
Accepted: 15/03/2005

### Introduction

*Cryptosporidium parvum* is the most commonly enteropathogen found during the first weeks of the life of calves, lambs and goat kids<sup>1</sup>. The role of *Cryptosporidium* as a primary etiological agent was confirmed in studies on experimental infections in the absence of other enteropathogenic agents<sup>2,3</sup>. Cryptosporidiosis is most severe in newborn animals; older lambs and kids may demonstrate growth retardation, and adult animals are generally refractory to infection and disease<sup>4,5,6,7</sup>.

Unlike a relative coccidia of the genus *Eimeria*, which are host specific, *Cryptosporidium parvum* has loose host specificity. Because of the resistance of cryptosporidial oocysts to many disinfectants and to other factors, oocysts from a variety of sources pose a threat to man<sup>8</sup>. Therefore, cryptosporidiosis is a zoonotic disease of

great importance in waterborne-related human outbreaks of diarrhoea<sup>9</sup> and a life-threatening disease in immunodeficient people<sup>10,11</sup>.

Adult sheep can act as asymptomatic carriers shedding small numbers of oocysts to the environment, which was shown to increase in number in the perinatal period and contribute to maintaining the infection between lambing periods<sup>1,12</sup>.

This study was carried out to determine patterns of shedding of cryptosporidial oocyst in lambs and their dams from lambing to weaning in a flock kept indoors in São Paulo State, Brazil, and also to evaluate the role of *C. parvum* in cases of diarrhea in newborn lambs.

### Materials and Methods

The study was carried out at the Universidade Estadual Paulista (UNESP),

Botucatu, São Paulo State.

A group of 20 Ile de France ewes in late pregnancy (August/2001) was housed in a facility with concrete floor. The concrete floor was cleaned daily and vigorously washed three times per week. Lambing occurred in August and in September/2001. Animals were supplied twice a day with a commercial diet (Ração Noel® - Cafenoel) and had free access to Tifton hay and potable water.

Fecal samples were taken from ewes and lambs on the day of the lambing, 4, 8, 16, 32 and 64 days after lambing. Fecal samples were taken from the rectum of each ewe. In young lambs, a detachable discardable plastic bag was fitted to the posterior region to allow collection of defecated feces.

One gram of feces preserved in 6 ml of 10% formalin was processed using a centrifuge-sedimentation technique in ether<sup>13</sup>. A 10 µl sample of the washed material, concentrated in 0.5 ml suspension, was spotted and distributed on a glass slide, dried at room temperature, and then fixed with absolute methyl alcohol for 3 minutes and stained with auramine O 1%<sup>14</sup>. The entire surface of the smear was examined for the presence of *C. parvum* oocysts at 400x magnifications using an epifluorescent microscope. *Cryptosporidium* oocysts fluoresce under ultraviolet light. Positive slides for the presence of oocysts in this first exam were, then, stained by Ziehl-Neelsen modified technique<sup>15</sup>, and again examined to confirm the diagnosis.

Chi-square test was used to compare infection rates using Minitab Version 11.

## Results

Oocysts of *Cryptosporidium* were found in fecal samples of lambs of one day of age. At this age, 25 % of the lambs shed oocysts (Figure 1). The highest percentage of positive samples occurred in 4-days-old lambs, and then decreased progressively as the lambs grow older. In ewes a peak in the

percentage of positive samples occurred 4 days after lambing. In ewes, the percentage decreased in the eighth day post-lambing, but increased again in the following weeks to reach a high of 45%, 64 days after lambing (Figure 1).

The overall percentages of fecal samples of lambs and ewes positives to *Cryptosporidium* oocysts were 26.7% and 31.9%, respectively. These percentages were statistically similar ( $P>0.05$ ). Four of the 20 lambs and two of the 20 ewes did not shed oocysts in any of the fecal samples examined.

Despite the relative high rate of animal shedding oocysts in feces, the cryptosporidial infection was asymptomatic in all ewes and lambs.

## Discussion

Independently of the age, animals in this study did not display any clinical sign of cryptosporidiosis, as diarrhea. They were simply asymptomatic carriers of the infection. Olson et al.<sup>16</sup> and Majewska et al.<sup>17</sup> also found lambs and adult sheep asymptotically infected with *Cryptosporidium* in Canada and Poland, respectively. In contrast, symptomatically infected lambs were described in other studies. Angus et al.<sup>4</sup> reported an outbreak of diarrhea associated with cryptosporidiosis in naturally reared lambs in Scotland. Causapé et al.<sup>18</sup> found cryptosporidial infection rates significantly higher in diarrheic (79.4%) than in non-diarrheic lambs (22.4%) in Spain. In that country, 7.8% of ewes shed *C. parvum* in the feces<sup>18</sup>, but these infections were asymptomatic, as observed in the present research.

In lambs, chilling due to adverse weather conditions in the neonatal period, intercurrent infections or nutritional or mineral deficiencies could exacerbate or increase the likelihood of disease<sup>19</sup>. In other hand, colostrum may prevent mortality and clinical cryptosporidiosis in neonatal lambs<sup>20</sup>. In the present experiment, all lambs suckle

their dams just after birth and were in good nutritional condition without being exposed to hazard weather conditions. This might have conferred resistance to the animals to support the pathogenic effects of the infection.

Variability in virulence of *C. parvum* may also play a role in the discrepancy regarding the severity of the infection observed in different regions of the world. Recently, Chalmers et al.<sup>21</sup> described a novel isolate of *Cryptosporidium* in sheep based on genotype. The sheep in which the novel isolate was identified were wealthy and showed no symptoms of cryptosporidiosis. According to the authors, the novel sheep isolate could represent a non-pathogenic strain. Their results suggest that a previously undetected *Cryptosporidium* sub-type may exist in sheep populations, reflecting the increasingly recognized diversity within the parasite genus. The *Cryptosporidium* detected in the present study was also apparently non-pathogenic and could be an isolate similar to that described by Chalmers et al.<sup>21</sup>. Further genetic and biological studies are necessary to characterize the isolate of *C. parvum* that occur in sheep in São Paulo State, Brazil.

Similar proportions of lambs and ewes shed oocysts in feces. Olson et al.<sup>16</sup> also found a similar prevalence of *C. parvum* in lambs less than 6-months-old (23%) and in animals with more than six months of age (27%). In contrast, Majewska et al.<sup>17</sup> observed that lambs were more often infected than adult sheep, and the intensity of infection was higher in lambs than in adult sheep in Poland.

The percentage of lambs shedding oocysts peaked at 4 days of age in lambs (45%) in the present study. Because oocysts are infective when passed in feces, transmission between animals can occur quickly<sup>4</sup>. Lambs artificially infected with *C. parvum* oocysts at 6 days of age showed a prepatent period of 3 to 4 days, while oocysts shedding reached a peak on day 6 post infection and fell below detectable levels

between days 13 and 18 post infection<sup>17</sup>. Snodgrass, Angus and Gray<sup>3</sup> also observed oocysts in feces from the third or fourth day post infection of gnotobiotic lambs.

Ortega-Mora et al.<sup>22</sup> reported, in dairy flocks of sheep kept indoors, that 71% of the lambs acquired infection in the first 2 weeks of life. Causapé et al.<sup>18</sup> also found a high percentage of lambs shedding oocysts in the first week of age (67.4%), nevertheless, the percentage of infected lambs peaked in the second week of age (76.2%). A similar trend of reduction in oocyst shedding occurred, as the animals grow older in the present study.

Causapé et al.<sup>17</sup> found *C. parvum* oocysts in feces of 59% of the lambs with age range of 1-90 days. A higher percentage was found in animals of the present study (80%). It is likely that the close contact between the animals and the feces had facilitated the parasite transmission at suckling.

In the present experiment, oocysts were found in fecal samples obtained from lambs with one day of age. Anderson<sup>23</sup> also found oocysts in feces of one- and two-day-old calves. According to the authors, this may have been due to orally ingested oocysts passing unchanged through the digestive tract. However, there are many case reports describing human patients with cryptosporidia in extraintestinal sites as gall bladder, bile ducts, pancreatic ducts and respiratory tract<sup>8</sup>. Extra-intestinal infections by *C. parvum*, including the gall bladder, mesenteric lymph nodes, trachea, lung and the uterus, have also been detected in sheep slaughtered in abattoirs<sup>24</sup>. Despite being able to colonize extra-intestinal sites, there is no report of fetal infection in sheep. Although the transmission of the parasite from dam to fetus had not been documented, the finding of several lambs shedding oocysts in feces in the first day of their lives are indicative that this form of infection could occur and should be investigated.

Oocyst shedding was detected in 90% of the ewes. This result shows that adult

ewes were an important source of infection for neonates. In agreement with our results, Ortega-Mora et al.<sup>22</sup> reported that 13 of 14 ewes excreted *C. parvum* oocysts at some time from the 6<sup>th</sup> week before birth until 2 weeks after birth and that oocysts excretion in the peripartum period was significantly greater than in previous weeks. Causapé et al.<sup>18</sup> reported a lower percentage (7.8%) of ewes shedding oocysts. Xiao, Herd and McClure<sup>12</sup> detected *C. parvum* only at the start of parturition in 4 of 32 housed ewes. In this study, excretion rates and intensities of oocysts in lambs were also low<sup>12</sup>. However, Xiao, Herd and Rings<sup>7</sup>, on a sheep farm with neonatal diarrhea, observed that all newborn lambs, 78.3% of older lambs and 17.3% of ewes excrete *Cryptosporidium* oocysts.

Animals may serve as a reservoir of *Cryptosporidium*, with potential for the

contamination of immediate household water sources. In an urban slum in Brazil, Newman et al.<sup>25</sup> reported several cases of human cryptosporidiosis associated with the presence of domestic animals shedding oocysts in feces. In Campo Grande - MS, of the 12 children with cryptosporidiosis, 10 had contact with dogs and or cats<sup>26</sup>. Molecular epidemiological studies show that the human genotype of *C. parvum* has so far been found only in humans, while the cattle genotype has been found in humans, as well as in domestic livestock such as cattle, sheep and goats<sup>27</sup>. In this context, sheep in Brazil can potentially play a role as reservoirs of infection for humans. However, further molecular epidemiological studies will be necessary to clarify the role of the livestock in human cryptosporidiosis in Brazil.

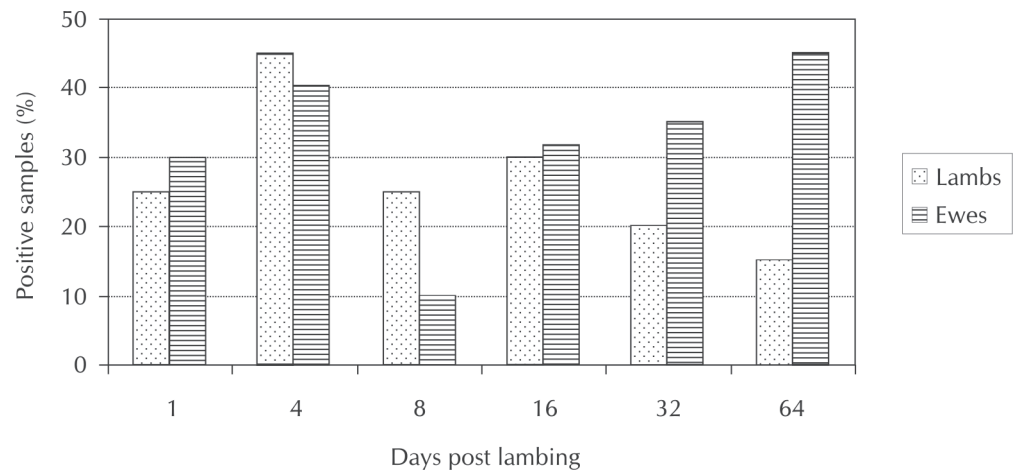


Figure 1 - Percentage of ewes and lambs shedding oocyst of *C. parvum* from lambing to weaning

## Eliminação de oocistos de *Cryptosporidium parvum* por ovelhas e cordeiros confinados

### Resumo

Este experimento foi realizado com o objetivo de determinar a variação na eliminação de oocistos de *Cryptosporidium parvum* nas fezes de cordeiros e ovelhas, mantidos confinados do nascimento a desmama, em uma criação localizada em Botucatu -SP. Um grupo de 20 ovelhas da raça Ile de France em final de gestação foi confinado em instalações com piso de concreto. O piso era lavado três vezes por semana e as fezes eram removidas diariamente. O nascimento dos cordeiros ocorreu em Agosto e Setembro/2001. Amostras de fezes foram colhidas das

### Palavras-chave:

*Cryptosporidium*.  
Ovinos.  
Cordeiros.  
Transmissão.

ovelhas e dos cordeiros no dia do nascimento, 4, 8, 16, 32 e 64 dias pós-parto. As amostras foram processadas pela técnica de centrifugo-sedimentação em éter. Esfregaços foram confeccionados e corados com auramina O e pela técnica de Ziehl-Neelsen modificada. Do total de amostras de cordeiros e ovelhas, 26,7% e 31,9%, respectivamente ( $P > 0,05$ ) apresentaram oocistos de *Cryptosporidium*. Quatro dos 20 cordeiros e duas das 20 ovelhas não apresentaram oocistos em nenhuma das amostras examinadas. O percentual mais alto de amostras positivas ocorreu nas amostras dos cordeiros com quatro dias de vida. Nas ovelhas o maior percentual de amostras positivas foi registrado quatro dias após o parto. Apesar da taxa relativamente elevada de animais que eliminaram oocistos nas fezes, a infecção por *C. parvum* foi subclínica nas ovelhas e nos cordeiros.

## References

- 1 GRAAF, D. C. et al. A review of the importance of Cryptosporidiosis in farm animals. **International Journal for Parasitology**, v. 29, p. 1269-1287, 1999.
- 2 ORTEGA-MORA, L. M.; WRIGHT, S. E. Age-related resistance in ovine cryptosporidiosis: patterns of infection and humoral immune response. **Infection and Immunity**, v. 62, p. 5003-5009, 1994.
- 3 SNODGRASS, D. R.; ANGUS, K. W.; GRAY, E. W. Experimental cryptosporidiosis in germfree lambs. **Journal of Comparative Pathology**, v. 94, p. 141-152, 1984.
- 4 ANGUS, K. W. et al. An outbreak of diarrhoea associated with cryptosporidiosis in naturally reared lambs. **Veterinary Record**, v. 110, p. 129-130, 1982.
- 5 FOREYT, W. J. Coccidiosis and cryptosporidiosis in sheep and goats. **The Veterinary Clinics of North America: Food Animal Practice**, v. 6, p. 655-670, 1990.
- 6 VIEIRA, L.S. et al. Outbreak of cryptosporidiosis in dairy goats in Brazil. **Veterinary Record**, v. 140, p. 427-428, 1997.
- 7 XIAO, L.; HERD, R. P.; RINGS, D. M. Diagnosis of *Cryptosporidium* on a sheep farm with neonatal diarrhea by immunofluorescence assays. **Veterinary Parasitology**, v. 47, p. 17-23, 1993.
- 8 STERLING, C. R.; ARROWOOD, M. J. Cryptosporidia. In: KREIER, J. P. **Parasitic protozoa**. 2. ed. San Diego: Academic Press, 1993. v. 6, p. 159-225.
- 9 SMITH, H. V.; ROSE, J. B. Waterborne cryptosporidiosis: current status. **Parasitology Today**, v. 14, p. 14-22, 1998.
- 10 KASPER, L. H.; BUZONI-GATEL, D. Some opportunistic parasitic infections in AIDS: candidiasis, pneumocystosis, cryptosporidiosis, toxoplasmosis. **Parasitology Today**, v. 14, p. 150-156, 1998.
- 11 UGA, S. et al. Cryptosporidium infection in HIV-seropositive and seronegative populations in Southern Thailand. **The Southeast Asian Journal of Tropical Medicine and Public Health**, v. 29, p. 100-104, 1998.
- 12 XIAO, L.; HERD, R. P.; McCLURE, K. E. Periparturient rise in the excretion of *Giardia* sp. cysts and *Cryptosporidium parvum* oocysts as a source of infection for lambs. **Journal of Parasitology**, v. 80, p. 55-59, 1994.
- 13 RITCHIE, L. S. An ether sedimentation technique for routine stool examination. **Bulletin of the United States Army Medicine Department**, v. 8, p. 326, 1948.
- 14 IDRIS, M. A.; AL-JABRI, A. M. Usefulness of Kato-Katz and trichrome staining as diagnostic methods for parasitic infections in clinical laboratories. **Journal of Science Research: Medical Science**, v. 3, p. 65-68, 2001.
- 15 HENRIKSEN, A.; POHLENZ, J. F. L. Staining of *Cryptosporidium* by a modified Ziehl-Neelsen technique. **Acta Veterinaria Scandinavica**, v. 22, p. 594-596, 1981.
- 16 OLSON, M. E. et al. *Giardia* and *Cryptosporidium* in Canadian farm animals. **Veterinary Parasitology**, v. 68, p. 375-381, 1997.
- 17 MAJEWSKA, A. C. et al. Prevalence of *Cryptosporidium* in sheep and goats bred on five farms in west-central region of Poland. **Veterinary Parasitology**, v. 89, p. 269-275, 2000.
- 18 CAUSAPÉ, A. C. et al. Prevalence and analysis of potential risk factors for *Cryptosporidium parvum* infection in lambs in Zaragoza (northeastern Spain). **Veterinary Parasitology**, v. 104, p. 287-298, 2002.
- 19 TAYLOR, M. A.; WEBSTER, K. A. Recent advances

in the diagnosis in livestock of *Cryptosporidium*, *Toxoplasma*, *Giardia* and other protozoa of veterinary importance. **Research in Veterinary Science**, v. 65, p. 183-193, 1998.

20 NACIRI, M. et al. Treatment of experimental ovine cryptosporidiosis with ovine or bovine hyperimmune colostrum. **Veterinary Parasitology**, v. 53, p. 173-190, 1994.

21 CHALMERS, R. M. et al. *Cryptosporidium* in farmed animals: the detection of a novel isolate in sheep. **International Journal for Parasitology**, v. 32, p. 21-26, 2002.

22 ORTEGA-MORA, L. M. et al. Role of adult sheep in transmission of infection by *Cryptosporidium parvum* to lambs: confirmation of periparturient rise. **International Journal for Parasitology**, v. 29, p. 1261-1268, 1999.

23 ANDERSON, B. C. Patterns of shedding of cryptosporidial oocyst in Idaho calves. **Journal of the American Veterinary Medical Association**, v. 178, p. 982-984, 1981.

24 FL ETA, J. et al. Detection of *Cryptosporidium* oocysts in extra-intestinal tissues of sheep and pigs. **Veterinary Parasitology**, v. 59, p. 201-205, 1995.

25 NEWMAN, R. D. et al. Environmental sources of *Cryptosporidium* in an urban slum in Northeastern Brazil. **The American Journal of Tropical Medicine and Hygiene**, v. 49, p. 270-275, 1993.

26 OSHIRO, E. T. et al. Prevalência do *Cryptosporidium parvum* em crianças abaixo de 5 anos, residentes na zona urbana de Campo Grande, MS, Brasil, 1996. **Revista da Sociedade Brasileira de Medicina Tropical**, v. 33, p. 277-280, 2000.

27 MORGAN, U. M. et al. Variation in *Cryptosporidium*: towards a taxonomic revision of the genus. **International Journal for Parasitology**, v. 29, p. 1733-1751, 1999.