

# Arthroscopic study of the dog's knee joint with clinical cranial cruciate ligament injury

Angelica Cecilia  
TATARUNAS<sup>1</sup>  
Julia Maria MATERA<sup>1</sup>  
Viviane Higuchi IMAGAWA<sup>1</sup>  
Sandra MASTROCINQUE<sup>1</sup>

1 - Departamento de Cirurgia da Faculdade de Medicina Veterinária e Zootecnia da Universidade de São Paulo, São Paulo - SP

## Abstract

The objective of the present study was to report intra articular changes observed by means of arthroscopic in dogs bearing cranial cruciate ligament injuries. Sixty-three dogs (sixty-five knee joints) with naturally occurring cranial cruciate injury were used. The arthroscopy was carried out before the ligament repair and the observed changes were both recorded and reported. According to the results obtained from this research it is significant to mention the presence of plicae on suprapatellar joint pouch; roughness, neovascularization and osteophytes in patella. The lateral meniscus presented axial fringe tear, fibrillation, neovascularization and complete laceration. The medial meniscus showed bucket handle tear, complete laceration, axial fringe tear, fibrillation, neovascularization and mineralization. The cranial cruciate ligament was completely ruptured, partially ruptured, interstitially ruptured and linked to the structures of the intercondylar notch. The caudal cruciate ligament showed vertical splits, besides fibrillation and partial rupture. Arthroscopy has been used for diagnostic of cranial cruciate ligament injuries in dogs. It permits improved diagnostic capability when evaluating cartilage and sinovial changes, meniscus and ligaments tears.

## Key-words:

Arthroscopic.  
Dogs.  
Knee joint.  
Cranial cruciate ligament.  
Orthopedic surgery.

## Correspondence to:

ANGÉLICA CECÍLIA TATARUNAS  
Departamento de Cirurgia  
Faculdade de Medicina Veterinária e Zootecnia  
Universidade de São Paulo  
Av. Prof. Orlando Marques de Paiva, 87  
05508-900 - São Paulo - SP  
angelvet@usp.br

Received: 22/08/2005  
Accepted: 10/12/2006

## Introduction

The cranial cruciate ligament injury (CrCLI) is the most prevalent disease of the dog's knee joint. The acute lesion where the cause is traumatic is rare and CrCLI generally is associated with ligament, as well as joint degenerative process<sup>1,2,3</sup>. Many clinicians are concerned about the increasing incidence of the CrCLI injury in younger adult dogs of large breeds<sup>1,4,5</sup> and 20% to 40% of dogs with this disease will have rupture of the contralateral ligament<sup>3,6,7</sup>.

The arthroscopic exam provides a minimally invasive means of inspection of the intra-articular ligamentous structures, as well as the synovium, menisci and articular cartilage. By the fact of the structures being highly illuminated and greatly magnified in an aqueous environment, viewing is greatly improved over traditional arthrotomy<sup>8,9</sup>.

Kivumbi and Bennett<sup>10</sup>, through direct arthroscopic visualization showed the

changes remarked in cartilage, ligament, meniscus and synovia. Sequentially, Siemering and Eilert<sup>11</sup> and Lewis, Goring and Parker<sup>12</sup> made arthroscopic intra articular evaluation after experimental cranial cruciate ligament transection. Adamiak<sup>13</sup> studied 40 dogs with CrCLI and between the observed changes mentioned periarticular osteophytes, medial meniscal tear, fibrillation and erosion of the femoral condylar articular cartilage. More recently, Whitney<sup>5</sup> reported by means of arthroscopy the normal and affected knee joint of dogs with special attention to the lesions associated with CrCLI.

In dogs, the CrCLI occurs associated with degenerative process of the others intra-articular structures<sup>4,14,15</sup>. It is known, by arthrotomy, that up to 75% of the medial meniscus will be injured in joints bearing CrCLI<sup>3,16</sup>. Moreover Ralphs and Whitney<sup>17</sup> described 77% of lesion of the lateral meniscus associated with CrCLI in dogs studied in arthroscopy.

Due to informative capacity of the diagnostic arthroscopy and the importance of intra articular alterations detection associated with the CrCLI, besides aiming to promote a full treatment and help in the understanding of this disease, the goal of this research was to report the intra-articular changes observed by arthroscopy in clinical cases of CrCLI injury in dogs.

## Materials and Methods

Sixty three dogs (sixty-five joints) bearing CrCLI, which were referred to the Department of Surgery in the Veterinary Medicine Faculty were studied. The arthroscopy was carried out before the ligament repair. Physical and orthopedic examination and stifle radiography were performed, giving particular attention to detect instability presence (anterior drawer movement) of the affected joint. The preoperative laboratory workup was based on the patient's physical status and included electrocardiogram, hematological and serum biochemical tests.

A 2.7-mm long 30-degree fore oblique arthroscope (Hopkins® Forward Oblique Telescope 30° - Karl Storz GmbH & Co), 4-mm cannula (Arthroscope Sheath - Karl Storz GmbH & Co), blunt obturator (Karl Storz GmbH & Co), switching stick (Karl Storz GmbH & Co), 4-mm multifenestrated cannula (Cânula fenestrada Karl Storz GmbH & Co), grasping and basket forceps (Pinça - Karl Storz GmbH & Co), retractor (Retrator - Karl Storz GmbH & Co), xenon (Xenon Spare Lamp, 175W, 15V 175- Karl Storz GmbH & Co), light source (Cold Light Fountain Xenon Nova - Karl Storz GmbH & Co), 3-mm and 250-cm fiberoptic light cables (Fluid Light Cables - Karl Storz GmbH & Co), color monitor (Color Monitor - Karl Storz GmbH & Co), camera head (Telecam® Câmera Head - Karl Storz GmbH & Co) and video camera system (Telecam® câmera Control Unit - Karl Storz GmbH & Co) were used as arthroscopic equipment.

The patient was clipped as for open arthrotomy and put in dorsal recumbency. Adhesive water impermeable drapes were used (Toban® - 3M - Health Care). The arthroscope and instrument portals, as well as the egress cannula were performed by means of Whitney<sup>5</sup> technique. Lactated Ringer's solution was used to distend the joint by gravity flow. During the exam of the knee joint it was remarked suprapatellar joint pouch, patella, trochlea, lateral and medial femoral condyle, lateral and medial tibial condyle, lateral and medial meniscus, tendon of long digital extensor muscle, cranial and caudal cruciate ligament and synovium. The compartments were opened by flexion, extension, rotation, stress varus and valgus of the joint.

The observed alterations were recorded and registered by using the videoprinter (Vídeo Printer - Sony).

## Results

Of the sixty-three dogs bearing CrCLI and examined by arthroscopy 41 were female and 22 were male, the range of age was 8 months to 12 years and the breeds were Rotweiller (31,7%), Pit Bull (11,1%), Labrador (7,9%), Boxer (7,9%), Poodle (7,9%), Fila Brasileiro (3,2%), Bulldogue Inglês (3,2%), Beagle (1,6%), Yorkshire (1,6%), Fox Paulistinha (1,6%), Chow Chow (1,6%) and Leonberger (1,6%). The mongrels estimated 19%.

During clinical exam all joints had positive cranial drawer movement.

The arthroscopic equipment was satisfactory for the proposed goal, in addition to the operatory technique.

The periarticular infiltration and the obstruction of the field of vision by the infrapatellar fat pad were the main complications of the procedure. In case it was needed the retractor was used to draw back the infrapatellar fat pad. The periarticular infiltration was light in the majority of cases and had spontaneous resolution after the surgery in all dogs.

The results of the observed changes of the intra articular structures obtained from this research and the prevalence which they were observed are in the table 1. It is important to mention the presence of plicae on suprapatellar joint pouch (Figure 1). The lateral meniscus (Figure 2) presented axial fringe tear, fibrillation, neovascularization and complete laceration. The medial meniscus showed bucket handle tear, complete laceration, axial fringe tear, fibrillation, neovascularization and mineralization. The cranial cruciate ligament was completely ruptured, partially ruptured, had absence of fragments, was interstitially ruptured and linked to the structures of the intercondylar notch. The caudal cruciate ligament (Figure 3) showed vertical splits, besides fibrillation and partial rupture.

Synovial membrane hyperplasia was observed mainly in suprapatellar joint pouch, around the margins of the patella, lateral and medial pouch, lateral and medial compartment and intercondylar notch. Synovial villi like fringe-like, twig-like, membranous fan-like and cauliflower-like<sup>18</sup> were predominant in these areas. It was hyperemic mainly around the patella, lateral and medial compartment and intercondylar notch. Opaque synovial villi, with scarce vessel and fibrin deposit were sometimes present in suprapatellar, lateral and medial joint pouch.

The caudal cruciate ligament and also the tendon of long digital extensor muscle had many blood vessels visible in the synovial membrane covering its surface.

In this research it was obtained 42% of the joints with CrCLI total rupture, 38% CrCLI total rupture associated to a medial meniscus lesion, 9% CrCLI partial rupture, 5% CrCLI partial rupture with medial meniscus lesion, and 1,5% of the joints with CrCLI associated to a lateral meniscus lesion, 1,5% CrCLI interstitial rupture, 1,5% CrCLI interstitial rupture associated to a medial meniscus lesion and 1,5% CrCLI with partial rupture of the caudal cruciate ligament.

## Discussion

Despite the CrCLI being an important and prevalent disease in the canine species it can't be completely understood yet. There is a suggestion that large breeding dogs tend to have an injury in the cranial cruciate ligament when they are younger<sup>1,4</sup> and the Rotweiler, the same as the ones in this study, has been accounted for a high proportion of the total number of dogs with CrCLI<sup>1</sup>.

Arthroscopy has been used more and more for diagnostic and treatment of CrCLI in dogs. It permits improved diagnostic capability when evaluating cartilage, synovial changes, meniscal and ligaments tears more than arthrotomy. BARDET (1999) has suggested diagnose arthroscopy in dogs with CrCLI even if the arthrotomy is used for the treatment. This research agrees with him in reference to the obtained result because partly of which would not have been seen if the arthrotomy itself had been performed.

The infrapatellar fat pad of the dog's knee can cause the obstruction of the field of vision during the arthroscopy and jeopardize the surgeon field of vision<sup>5,10,11,20</sup>. This was observed during this research and the retractor was used to draw back the infrapatellar fat pad, which was satisfactory in the majority of the studied joints.

The suprapatellar joint pouch, patella, trochlea, medial and lateral femoral condyle, intercondylar notch, cranial and caudal cruciate ligament, medial and lateral meniscus<sup>13,21</sup>, tendon of long digital extensor muscle<sup>10,11</sup>, medial and lateral tibial condyles, intermeniscal ligament and popliteal tendon<sup>19,22</sup> are intra articular structures able to be visualized by arthroscopy in the dog's knee joint. Excluding the last structure, which belongs to a difficult area to be examined<sup>10,12</sup>, the remainders were observed in this research in different proportions.

Four synovial plicae have been described in the knee joint of the human species and some of them are the result of the incomplete reabsorption of the synovial membrane that splits the joint during the fetal

Table 1 – List of the observed changes on the intra articular structures by arthroscopy on the dog's knee joint with clinical cranial cruciate ligament injury

ANATOMIC STRUCTURE	INTRA ARTICULAR CHANGES	(n)	(%)
Suprapatellar joint pouch	Plicae	19	29,23
Patella	Roughnes	17	26,15
	Neovascularization	13	20,00
	Osteophytes	2	3,10
Proximal trochlea	Roughnes	24	36,92
	Neovascularization	22	33,85
	Fibrillation	15	23,10
	Osteophytes	12	18,46
	Condromalacea	8	12,31
Lateral trochlea	Erosion	4	6,15
	Eburnação	4	6,15
	Osteophytes	40	6,54
	Roughnes	39	60,00
	Neovascularization	21	32,31
Medial trochlea	Condromalacea	5	7,70
	Roughnes	40	61,54
	Osteophytes	38	58,46
	Neovascularization	23	35,38
Lateral femoral condyle	Eburnation	1	1,54
	Roughnes	33	50,77
	Fibrillation	8	12,31
	Condromalacea	3	4,61
	Erosion	2	3,10
Medial femoral condyle	Osteophytes	1	1,54
	Roughnes	44	67,70
	Fibrillation	12	18,46
	Erosion	3	4,61
	Condromalacea	3	4,61
Medial tibial condyle	Neovascularization	2	3,10
	Osteophytes	2	3,10
	Roughnes	4	6,15
	Lateral tibial condyle	Roughnes	2
Lateral meniscus	Axial fringe tear	22	33,85
	Fibrillation	3	4,61
	Neovascularization	2	3,10
	Laceration	1	1,54
Medial meniscus	Bucket handle tear	20	30,80
	Laceration	12	18,46
	Axial fringe tear	11	16,92
	Fibrillation	5	7,70
	Neovascularization	5	7,70
Cranial cruciate ligament	Mineralization	1	1,54
	Complete rupture	40	61,54
	Partial rupture	13	20,00
	Interstitial rupture	2	3,10
	Absence of fragments	9	13,85

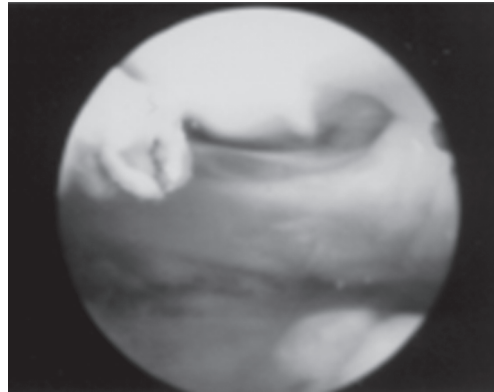


Figure 1 - Arthroscopy of the dog's knee where is observed plicae on suprapatellar joint pouch

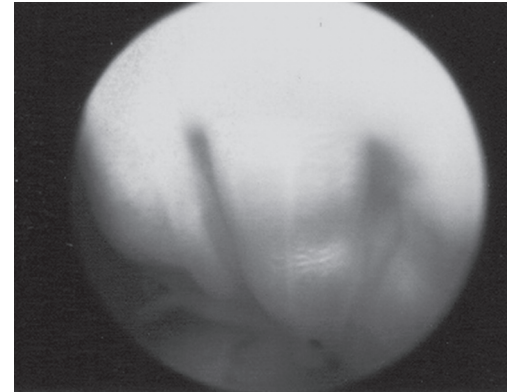


Figure 3 - Arthroscopy of the dog's knee where is observed vertical splits in the caudal cruciate ligament

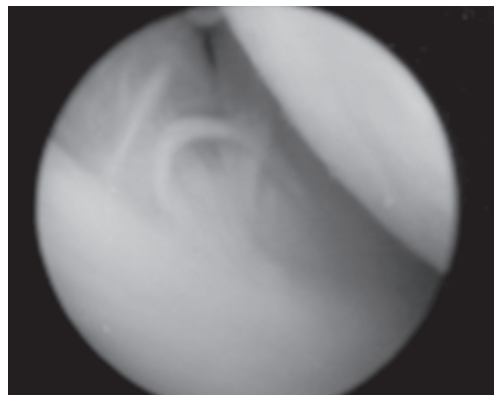


Figure 2 - Arthroscopy of the dog's knee where is observed axial fringe tear in the lateral meniscus

development<sup>15</sup>. In previous study in dog's cadavers we could notice them in the suprapatellar area<sup>23</sup> and whereas similarly in man, the sinovial plicae seemed to be a normal structure of the canine knee joint. Due to the fact that when these injured synovial plicae cause pain and lameness in man we remark the importance of a detailed exam of this structures during arthroscopy so as to detect possible changes like thickness or inflammation occurring concomitantly or not with CrCLI. In this study we couldn't detect any significant change in this structure, which were described by Whitney<sup>5</sup>, for the literature being poor in the subject about dog's knee joint.

The degenerative joint disease following CrCLI is progressive<sup>3,8</sup>. Whitney<sup>5</sup> has observed that the arthroscopic changes

of the degenerative joint disease such as periarticular osteophytes are more severe in joints bearing CrCLI than other diseases of the stifle joint. Neovascularization and roughness on the articular cartilage surface may occur prior to future osteophytes sites. They occur in three predictable locations: the proximal trochlear groove and the medial and lateral trochlear ridge of the femur<sup>5</sup>. A part from the mentioned sites this research showed osteophytes, neovascularization and roughness on the patella proximal and distal extremities. Surface roughness without neovascularization or defined osteophytes were noted on the lateral and medial femoral and tibial condyles.

There seems to be a definitive pathogenesis of the CrCLI in that, an initial stretching, partial rupture and then total rupture have been identified<sup>1,3,4,5,24</sup>. In the first the ligament can show as healthy but its function is abnormal. During this study we can detect all modalities in different proportions. The dogs having interstitial rupture (n=2) showed the ligament abnormally loose and stretching when probing.

Zachos et al.<sup>14</sup> in experimental study founded significant morphological alterations of the caudal cruciate ligament in dogs bearing CrCLI. This associated caudal cruciate ligament lesion (42%) with CrCLI observed by arthroscopy in this research to agree to the microscopic study mentioned.

These changes may be associated with repetitive microtrauma to the caudal cruciate ligament secondary to instability or enzymatic degradation in the hostile synovial environment of an unstable joint<sup>14</sup>. Although to its unknown clinical relevance these results may have implications in the surgical management of CrCLI in dogs. The caudal cruciate ligament becomes the prime stabilizer of the stifle during weight bearing when tibial plateau leveling osteotomy is the surgical treatment of the CrCLI<sup>25</sup>. The arthroscopy may be an option to evaluate the caudal cruciate ligament in dogs bearing CrCLI before to decide the surgical technique but further investigation of the correlation of the histological and arthroscopic visualization is warranted.

In spite of Piermattei and Flo<sup>3</sup> having agreed that the lateral meniscus lesion associated with CrCLI is rare, Ralphs and Whitney<sup>17</sup> have reported 77% of it detected by arthroscopy. This research has got laceration of the lateral meniscus in one dog and lesions such as axial fringe tear, fibrillation and neovascularization in 41,6% of joints. Although being unknown by Ralphs and Whitney<sup>17</sup>, Kivumbi and Bennett<sup>10</sup> have considered these last lesions as an old dog normal finding.

According to Kivumbi and Bennett<sup>10</sup> the arthroscopic exam allows to analyse the synovial morphologic characterization as color, size and pattern and consequently classify it<sup>18</sup>. The arthroscopic appearance of normal synovium is dependent on the area of the joint that is being inspected<sup>5</sup>. Similar

to Lewis, Goring and Parker<sup>12</sup> and Adamiak<sup>13</sup>, who performed experimental and clinical arthroscopy study in dogs bearing CrCLI, respectively, we could see hiperplasia and hyperemia of the sinovial villi with different morphological appearance<sup>10,18</sup> tending to be thicker, filamentous, reddened and vascular. In the lateral and medial compartment and intercondylar notch they were thicker but shorter than other areas.

## Conclusion

The arthroscopy exam permits to obtain detailed and accurate information about the majority of the intra-articular structures, independent of the definitive diagnostic. Consequently it is possible to have a better prognostic for the disease.

We believe that the more the arthroscopy is used in canine species the more knowledge about intra articular lesion in each disease in addition to its real meaning there will be.

Furthermore the outstanding conclusion of this paper suggests that arthroscopy can be helpful in the understanding of the etiopathology of degenerative joint diseases on the stifle after cranial cruciate ligament injury in dogs.

## Acknowledgments

The authors acknowledge the contribution of FAPESP (Foundation of Support to Research of the State of São Paulo).

## Estudo artroscópico da articulação do joelho em cães portadores de lesão do ligamento cruzado cranial

### Resumo

O objetivo do presente estudo foi relatar as alterações intra-articulares observadas através de artroscopia em cães portadores de injúria do ligamento cruzado cranial. Foram utilizados sessenta e três cães (sessenta e cinco articulações) com a afecção. A artroscopia foi realizada anteriormente a reparação do ligamento e as alterações observadas foram relatadas e fotografadas. De acordo com os resultados obtidos nesta pesquisa é significativo mencionar a presença de plicas na bolsa

### Palavras chave:

Artroscopia.  
Cães.  
Articulação do joelho.  
Ligamento cruzado cranial.  
Cirurgia ortopédica.

articular suprapatelar, irregularidade, neovascularização e osteofitos na patela. O menisco lateral apresentou ruptura em franja, fibrilação, neovascularização e completa laceração. O menisco medial mostrou lesão em alça de balde, laceração completa, ruptura em franja, fibrilação, neovascularização e mineralização. O ligamento cruzado cranial estava completamente rompido, parcialmente rompido, com ruptura intersticial ou aderido a estruturas do sulco intercondilar. O ligamento cruzado caudal mostrou fendas verticais, além de fibrilação e ruptura parcial. Artroscopia tem sido utilizada para o diagnóstico de injúria do ligamento cruzado cranial em cães. Ela permite uma maior capacidade diagnóstica quando avaliamos alterações de cartilagem e sinóvia, ruptura de menisco e ligamento.

## References

- 1 BENNETT, D.; TENNANT, B.; LEWIS, D. G.; BAUGHAN, J.; MAY, C.; CARTER, S. A reappraisal of anterior cruciate ligament disease in the dog. **Journal of Small Animal Practice**, v. 29, n. 5, p. 275-297, 1988.
- 2 WHITEHAIR, J. G.; VASSEUR, P. B.; WILLITS, N. H. Epidemiology of cranial cruciate ligament rupture in dogs. **Journal of the American Veterinary Medical Association**, v. 203, n. 7, p. 1016-1019, 1993.
- 3 PIERMATTEI, D. L.; FLO, G. L. The stifle joint. In: \_\_\_\_\_. **Brinker, Piermattei, and Flo's handbook of small animal orthopedics and fracture repair**. 3. ed. Philadelphia: W. B. Saunders, 1997b. p. 516-580.
- 4 VASSEUR, P. B.; POOL, R. R.; ARNOCZKY, S. P.; LAU, R. E. Correlative biomechanical and histologic study of the cranial cruciate ligament in dogs. **American Journal of Veterinary Research**, v. 46, n. 9, p. 1842-1854, 1985.
- 5 WHITNEY, W. O. Arthroscopically assisted surgery of the stifle joint. In: BEALE, B. S.; HULSE, D. A.; SCHULZ, K. S.; WHITNEY, W. O. **Small animal arthroscopy**. Philadelphia: W. B. Saunders, 2003. p. 116-157.
- 6 DUPUIS, J.; HARARI, J. Cruciate ligament and meniscal injuries in dogs. **Compendium of Continuing Education for the Practicing Veterinarian**, v. 15, n. 2, p. 215-232, 1993.
- 7 JOHNSON, A. L.; HULSE, D. A. Diseases of the joints. In: FOSSUM, T. W. **Small animal surgery**. 2. ed. St. Louis: Mosby, 2002. p. 883-993.
- 8 BEALE, B. S.; HULSE, D. A.; SCHULZ, K. S.; WHITNEY, W. O. **Small animal arthroscopy**. Philadelphia: W. B. Saunders, 2003. 229 p.
- 9 VAN RYSSSEN, B.; VAN BREE, H.; WHITNEY, W. O.; SCHULZ, K. S. Small Animal Arthroscopy. In: SLATTER, D. **Textbook of small animal surgery**. 3. ed. Philadelphia: W. B. Saunders, 2003. p. 2285-2312.
- 10 KIVUMBI, C. W.; BENETT, D. Arthroscopy of the canine stifle joint. **Veterinary Record**, v. 109, n. 12, p. 241-249, 1981.
- 11 SIEMERING, G. B.; EILERT, R. E. Arthroscopic study of cranial cruciate ligament and medial meniscal lesions in the dog. **Veterinary Surgery**, v. 15, n. 3, p. 265-269, 1986.
- 12 LEWIS, D. D.; GORING, R. L.; PARKER, R. B. A comparison of diagnostic methods used in the evaluation of early degenerative joint disease in the dog. **Journal of the American Animal Hospital Association**, v. 23, n. 4, p. 305-315, 1987.
- 13 ADAMIAK, Z. Arthroscopy in dogs with cranial cruciate ligament injuries. **Indian Veterinary Journal**, v. 79, n. 2, p. 177-178, 2002.
- 14 ZACHOS, T. A.; ARNOCZKY, S. P.; LAVAGNINO, M.; TASHMAN, S. The effect of cranial cruciate ligament insufficiency on caudal cruciate ligament morphology: an experimental study in dogs. **Veterinary Surgery**, v. 31, n. 6, p. 596-603, 2002.
- 15 JACKSON, R. W. História da artroscopia. In: ANDREWS, J. R.; TIMMERMAN, L. A. **Artroscopia diagnóstica e cirúrgica**. Rio de Janeiro: Revinter, 2000. p. 3-6.
- 16 FLO, G.; DE YOUNG, D. Meniscal injuries and medial meniscectomy in the canine stifle. **Journal of the American Animal Hospital Association**, v. 14, n. 8, p. 683-689, 1978.
- 17 RALPHS, S. C.; WHITNEY, W. O. Arthroscopic evaluation of menisci in dogs with cranial cruciate ligament injuries: 100 cases (1999-2000). **Journal of the American Veterinary Medical Association**, v. 221, n. 11, p. 1601-1604, 2002.
- 18 MCILWRAITH, C. W.; FESSLER, J. F. Arthroscopy in the diagnosis of equine joint disease. **Journal of the American Veterinary Medical Association**, v. 172, n. 3, p. 263-268, 1978.
- 19 BARDET, J. F. Anatomie descriptive arthroscopique du grasset du chien. **Pratique Médicale et Chirurgicale de L' Animal de Compagnie**, v. 34, n. 4, p. 513-522, 1999.
- 20 MCCARTHY, T.C. Arthroscopy. In: FREEMAN, L. J. **Veterinary endosurgery**. Philadelphia: Mosby, 1999. p. 237-250.

- 21 VAN GESTEL, M. A. Arthroscopy of the canine stifle joint. **Veterinary Surgery**, v. 7, n. 4, p. 237-239, 1985.
- 22 PERSON, M. W. A Procedure for arthroscopic examination of the canine stifle joint. **Journal of the American Animal Hospital Association**, v. 21, n. 2, p. 179-186, 1985.
- 23 TATARUNAS, A. C.; MATERA, J. M. Estudo artroscópico da articulação do joelho em cadáveres de cães. **Acta Cirúrgica Brasileira**, v. 19, n. 3, p. 235-285, 2004.
- 24 ARNOCZKY, S. P.; MARSHALL, J. L. The cruciate ligaments of the canine stifle: an anatomical and functional analysis. **American Journal of Veterinary Research**, v. 38, n. 11, p. 1807-1814, 1977.
- 25 WARZEE, C. C.; DÈJARDIN, L. M.; ARNOCZKY, S. P., et al., Effect of tibial plateau leveling on cranial and caudal tibial thrusts in canine cranial cruciate deficient stifles: An in vitro experimental study. **Veterinary Surgery**, v. 30, n. 3, p. 278-286, 2001.