

# Ultrasonography as an ancillary method for the positioning of markers in equine motion analysis

## *Utilização da ultrassonografia como método auxiliar no posicionamento de marcadores em análise de movimento de equinos*

Luanna Ferreira Fasanelo GOMES<sup>1</sup>; Stefano Carlo Filippo HAGEN<sup>2</sup>;  
Ricardo Machado Leite de BARROS<sup>3</sup>; Antônio de QUEIROZ-NETO<sup>4</sup>

<sup>1</sup> Federal University of Mato Grosso, Institute of Health Sciences, Sinop – MT, Brazil

<sup>2</sup> University of São Paulo, School of Medicine Veterinary and Animal Research, Department of Animal Surgery, São Paulo – SP, Brazil

<sup>3</sup> State University of Campinas, Physical Education Institute, Laboratory of Instrumentation for Biomechanics, Campinas – SP, Brazil

<sup>4</sup> São Paulo State University, Faculty of Agriculture and Veterinary Sciences, Animal Morphology and Physiology Department, Jaboticabal – SP, Brazil

### Abstract

Kinematic motion analysis is based on the reconstruction of selected bony anatomical landmarks identified by surface markers. Anatomical landmarks generally do not correspond to points but rather to relatively large and curved areas and their identification by palpation is not easy. Precise placement of surface markers is even more difficult and there is great variability between operators. In this study 16 examiners were asked to identify the lateral border of the left ischial tuberosity in a horse using palpation and ultrasonography for placement of a corresponding skin surface marker. Images of each marking procedure were captured using two video cameras and processed using the DVideow videogrammetry. A custom-written Matlab code was used to determine the position of the respective vectors. The positions of the markers were then compared to assess inter-examiner variability and the precision of the methods employed using the Bartlett test and the paired t-test respectively. Ultrasonography significantly improved the location of the anatomical landmark by each examiner ( $p = 0.04$ ) and reduced the variability in the position of the surface marker when compared to palpation ( $p = 0.0028$ ). The variability of the calculated distances (mean  $\pm$  SD) was  $2.89 \pm 2.24$  cm and  $1.63 \pm 0.98$  cm using palpation and ultrasonography respectively. Ultrasound guidance reduced inter-examiner variability and allowed visualization of the corresponding bony anatomical landmark.

**Keywords:** Anatomical landmarks. Horse. Kinematic analysis. Locomotion. Ultrasound.

### Resumo

A análise cinemática do movimento é baseada na reconstrução de pontos anatômicos específicos identificados por marcadores de superfície. Esses pontos de referência geralmente não correspondem a pontos, mas a áreas relativamente grandes e curvas de difícil identificação pela palpação. A colocação precisa dos marcadores de superfície é ainda mais difícil e há grande variabilidade entre examinadores. Neste estudo, 16 examinadores foram submetidos à identificação da borda lateral da tuberosidade isquiática esquerda de um cavalo usando a palpação e a ultrassonografia para colocar um marcador de superfície. Imagens de cada procedimento de marcação foram adquiridas utilizando-se duas câmeras de vídeo digital e processadas através o sistema de videogrametria DVideow. O software Matlab foi usado para determinar a posição dos respectivos vetores. As posições dos marcadores foram comparadas para avaliar a variabilidade entre os examinadores e a precisão do método empregado através do teste de Bartlett e teste t pareado, respectivamente. A ultrassonografia melhorou significativamente a localização dos pontos anatômicos de cada examinador ( $p = 0,04$ ) e reduziu a variabilidade no posicionamento dos marcadores de superfície quando comparada à palpação ( $p = 0,0028$ ). A variabilidade das distâncias calculadas (média  $\pm$  dp) foi de  $2,89 \pm 2,24$  cm e  $1,63 \pm 0,98$  cm usando a palpação e a ultrassonografia, respectivamente. A ultrassonografia reduziu a variabilidade entre examinadores e permitiu a visualização do ponto anatômico correspondente.

**Palavras-chave:** Pontos anatômicos. Cavalo. Análise cinemática. Locomoção. Ultrassom.

#### Correspondence to:

Luanna Ferreira Fasanelo Gomes  
Universidade Federal do Mato Grosso (UFMT), Instituto de Ciências da Saúde  
Campus de Sinop  
Av. Alexandre Ferronato, 1200 - Setor Industrial  
CEP 78557-267, Sinop, MT, Brasil

e-mail: luannaffgomes@gmail.com

Received: 28/05/2013

Approved: 17/03/2014

## Introduction

Lameness is one of the most common problems in horse veterinary clinics. In the last decades, kinematic motion analysis methods have enabled quantitative studies of equine locomotion. The kinematic analysis requires a rigid body modeling, defined by markers positioned in determined anatomical landmarks. The reliability in kinematic analysis is largely dependent on the precision of the determination of anatomical landmark position used to create a rigid body modeling. Minor asymmetries in the position of surface markers can translate into large errors in kinematic data in equine motion analysis (AUDIGIÉ et al., 1998).

The identification of anatomical landmarks (AL) and the reconstruction of their position in a selected set of axes is a major issue in human motion analysis. Positional uncertainty may be due to several factors: ALs may correspond to relatively large and irregular surfaces that must be translated into a single point, ALs may be covered by a layer of soft tissue of variable thickness and composition and therefore be difficult to palpate, or the identification of ALs may differ depending on the palpation procedure employed (DELLA CROCE et al., 2005). Even examiners with the same expertise have different interpretations on the instructions for anatomical landmarks identification; their definition is prone to misinterpretation, leading to greater inter-examiner dispersion in the location of anatomical landmarks (DELLA CROCE; CAPPOZZO; KERRIGAN, 1999).

Difficulties in palpation of bony ALs due to the thickness of the overlying soft tissues in horses have been reported (AUDIGIÉ et al., 1998; LICKA; PEHAN; ZOHMANN, 2001). Variability in the position of pelvic and lower limb bony landmarks have also been reported in humans due to anatomic variation and errors related to AL identification and placement of corresponding reference markers (WHITE; YACK; WINTER, 1989). Minor asymmetries in the position of surface markers can translate into large errors in kinematic data in equine motion analysis (AUDIGIÉ et al., 1998).

The development of new techniques to improve the location of anatomical landmarks enhances the reliability of kinematic motion analysis data (DELLA CROCE et al., 2005). Imaging techniques such as fluoroscopy and roentgen-photogrammetry have been used to accurately locate anatomical landmarks in horses (FABER et al., 2001) and humans (SMALL et al., 1993), respectively. In horses ultrasound-guided techniques for intra-synovial injection proved to be reliable and more accurate than conventional “blind” techniques (SCHNEEWEISS; PUGGIONI; DAVID, 2012). In humans and horses ultrasound-guided injection techniques are preferable to injections guided by fluoroscopy or computed tomography due to lower duration of the procedure and exposure to radiation (GALIANO et al., 2007; COUSTY et al., 2011).

The present study aimed to evaluate the applicability of diagnostic ultrasound as an ancillary technique for identification and marking of anatomical landmarks in horses.

## Material and Methods

One 10-year-old female Brazilian Sport Horse weighing 420 kg and measuring 1.60 m at the withers was used in the study. The horse was considered sound based on clinical history and physical assessment.

A veterinarian attached to the skin four white spherical plastic markers measuring 19 mm in diameter, overlaying four selected anatomical landmarks on the coxal bone, using double-sided tape. We used three anatomical landmarks to locate three corresponding points that were kept fixed during image acquisition and used for reconstruction of the local coordinate system. The selected anatomical landmarks and respective fixed points corresponded to: left sacral tuberosity (p1), medial border of the left ischial tuberosity (p2) and cranial border of the left coxal tuberosity (p3). The fourth anatomical landmark (test point; p) corresponded to the lateral border of the left ischial tuberosity and was used to assess the variability in the position of the markers (figure 1).

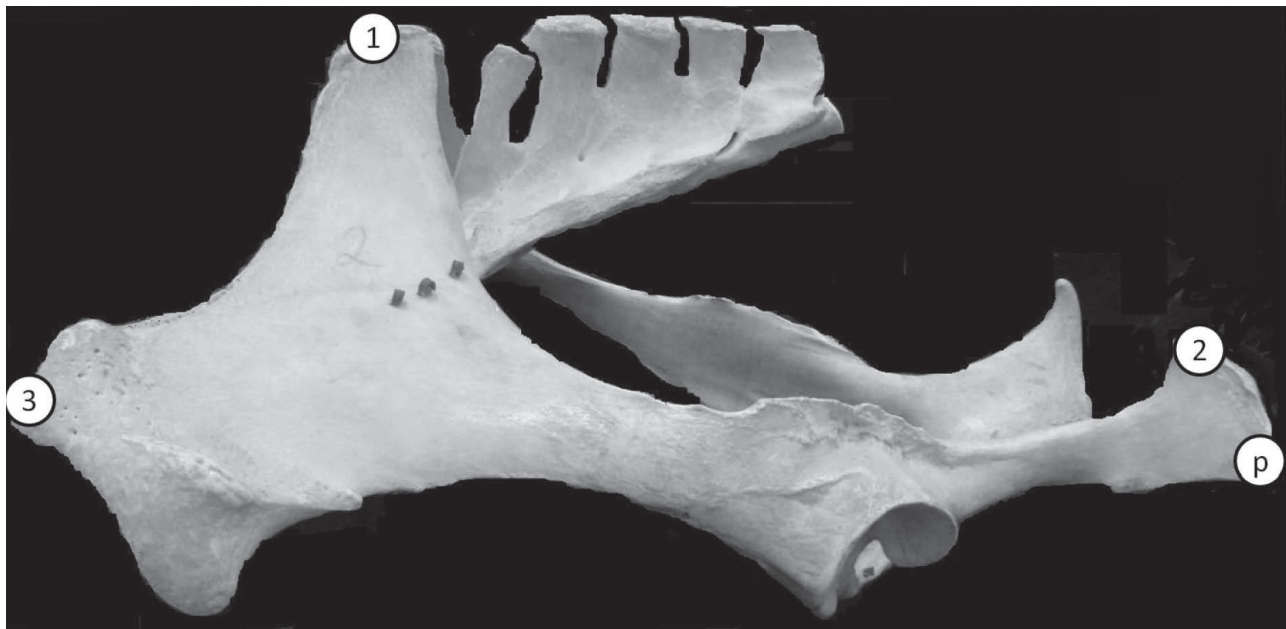


Figure 1 – Location of the fixed reference points p1 (1), p2 (2) and p3 (3) and the test point (p) on the coxal bone. Sinop, 2011  
Source: (GOMES, 2007)

Two digital video cameras (JVC D70U and JVC 9500)\* were positioned on the left side of a calibrated volume measuring approximately 2 m x 2 m x 2 m. To estimate the error of the calibration system, an examiner moved an object of known length in the calibrated space and the object in motion was measured by 283 frames. The estimated mean error and mean deviation were 3.3 mm and 3.0 mm respectively.

Sixteen veterinarians familiar with equine anatomy participated in the study as examiners. The examiners had similar experience with palpation of anatomical landmarks but none of them had experience with ultrasound imaging. Each examiner served as his/her own control. They were first requested to locate and mark the test point based on palpation of the lateral border of the left ischial tuberosity (Group 1), and then the same examiner was instructed to locate and mark the same point under ultrasound

guidance (Group 2). For ultrasonographic location of the selected anatomical landmark, they positioned the transducer parallel to the biceps femoris muscle at the level of the left ischial tuberosity and advanced cranially until visualization of the ischial bone margin. They rotated the transducer 90° and advanced distally for identification of the most lateral aspect of the bone (figure 2a). Without moving the transducer, they introduced the tip of the index finger between the transducer and the skin for location of the test point (figure 2b). Stereophotogrammetric images were obtained following each marking of the test point. We analyzed images using the DVideow\*\* videogrammetry system (FIGUEROA; LEITE; BARROS, 2003) and these images were employed for reconstruction of three-dimensional coordinates for each marker. Data were analyzed using a custom-written Matlab\*\*\* code.

\* JVC Kenwood Corporation, Kanagawa, Japan.

\*\* Unicamp, Campinas, Brazil

\*\*\* MathWorks Inc., Natick, Massachusetts, USA.

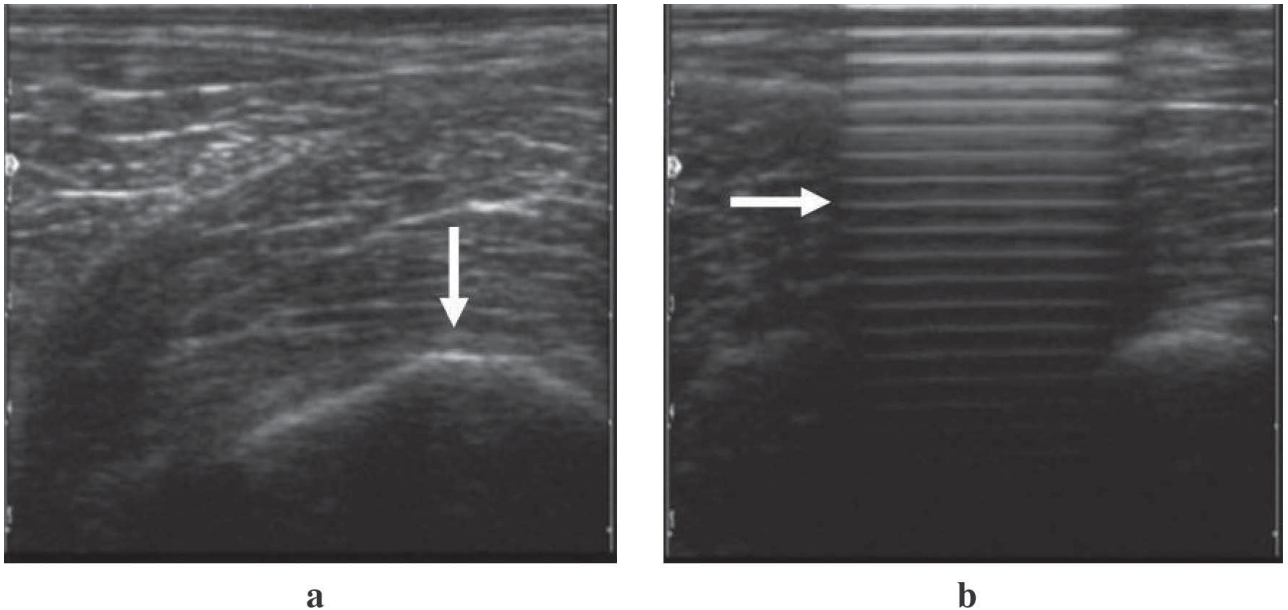


Figure 2 – Ultrasound images of the lateral border of the left ischial tuberosity. (a) Bone margin of the ischial tuberosity used as a reference to mark the test point (arrow). (b) Reverberation artifact caused by placement of the finger on the target point (arrow). Jundiaí, 2007  
Source: (GOMES, 2007)

To compare the position of the test point marked by different examiners, the global coordinate system had to be transformed into a local coordinate system (equation 1). This new coordinate system was fixed at the hip of the horse with  $p_1$  as the point of origin and named coxal bone-based coordinate system (BCS) (figure 3).

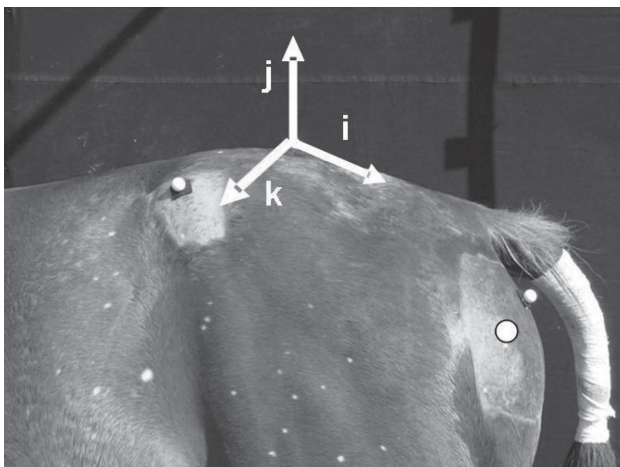


Figure 3 – Image acquisition of the horse's hip displaying the three fixed points and the test point (filled circle). Jundiaí, 2007  
Source: (GOMES, 2007)

For construction of the BCS, we developed a right-handed coordinate system. First, the “i” axis was defined as the vector running from  $p_1$  to  $p_2$ . The “j” axis was then defined as the orthogonal vector formed by vector  $i$  and the vector  $(p_3, p_1)$ . The “k” axis corresponded to the vector orthogonal to vectors  $i$  and  $j$ .

BCS = (O, i, j, k) where

$$\begin{aligned} i &= p_2 - p_1 / |p_2 - p_1| \\ a &= p_3 - p_1 / |p_3 - p_1| \\ j &= i \wedge a / |i \wedge a| \\ k &= i \wedge j \end{aligned} \quad \text{equation 1}$$

A transformation matrix was developed and used to transfer the location of each vector corresponding to the position of the test point ( $vp$ ) from the global coordinate system to the BCS (equation 2).

$$VP = [ijk]^{-1} * vp \quad \text{equation 2}$$

where VP is the position of the vector in the BCS.

Each VP obtained by palpation and under ultrasound guidance was determined in the BCS. A mean vector



position (MVP) was calculated based on the 16 VPs obtained for each group. The distances between VP and MVP were used to assess the variability between the different methods employed.

The Lilliefors test was employed to assess the normality of the results in each group. Given the normal distribution observed the paired t-test was performed to compare the results between examiners and the Bartlett test to compare the variability between groups. The level of significance was set at 5% ( $p < 0.05$ ). Data were analyzed using R Development Core Team (2013).

## Results

Based on comparisons between each examiner (paired t-test), location of the selected AL was more precise using ultrasound guidance than palpation ( $p = 0.04$ ). The maximum and minimum distances documented in group 1 (7.48cm and 0.89 cm respectively) were twice as large as in group 2 (3.63 cm and 0.32cm respectively) (table 1).

Mean distances between MVP and VP were significantly greater in group 1 than group 2 (Table 1).

Table 1 – Distances between mean vector point (MVP) and vector point (VP) documented by each of the 16 examiners using palpation and ultrasonography respectively – Jundiaí – 2005

Examiner	Distances between MVP and VP (cm)	
	Group 1	Group 2
1	0.89	0.69
2	1.07	0.32
3	1.70	1.81
4	0.85	0.43
5	3.16	0.76
6	1.28	1.75
7	1.44	1.43
8	2.10	3.63
9	1.19	1.66
10	2.90	2.92
11	4.86	0.53
12	5.68	2.95
13	7.48	2.33
14	1.62	1.72
15	7.32	1.07
16	2.67	2.00
<b>Mean ± SD</b>	<b>2.88 ± 2.23</b>	<b>1.62 → ± 0.98*</b>

\* Significant difference ( $p < 0.05$ )

According to the results of the Bartlett test variability differed between groups ( $p = 0.0028$ ) with greater variance in group 1 than group 2 (figure 4).

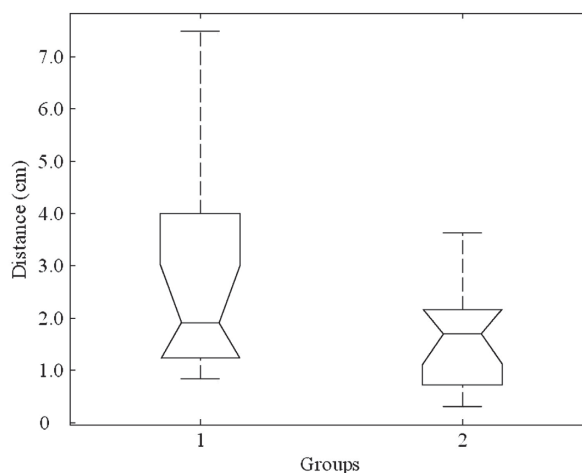


Figure 4 – Distances between the mean vector point (MVP) and the vector point (VP) in each group. Jundiaí, 2007

Source: (GOMES, 2007)

## Discussion

The use of fluoroscopy and computed tomography for more precise location of ALs has been described in equine motion analysis (FABER et al., 2001) and for intra-articular injection purposes in horses (ROSENSTEIN et al., 2001) and humans (AGUIRRE; BERMUDEZ; DIAZ, 2005). According to recent studies ultrasound is superior to either fluoroscopy or computed tomography for intra-articular injection guidance (GALIANO et al., 2007; COUSTY et al., 2011). However, to the authors' knowledge no data concerning the use of ultrasound for location of ALs in motion analysis have been published to date. This study suggests that ultrasound guidance can be used to reduce the variability in the position of ALs in horses.

The thickness of the overlying soft tissue, particularly in the proximal limb, interferes with palpation of ALs in humans (DELLA CROCE; CAPPOZZO; KERRIGAN, 1999) and horses (LICKA; PEHAN; ZOHMANN, 2001). Even for examiners with some expertise, the identification of a point based on large

ALs is difficult and may lead to misinterpretations, with mean errors as large as 2.4 cm in some cases (DELLA CROCE; CAPPOZZO; KERRIGAN, 1999). In this study, when markers were attached using palpation the maximum distance observed was 7.48 cm. However, when ultrasound guidance was employed this was reduced to 3.63 cm.

Examiners in this study reported great difficulty in palpating the test point mainly due to the overlying musculature. Ultrasonography enabled good visualization of the selected anatomical landmark, thus facilitating location of the test point by different individuals. Also, ultrasonography can provide additional clinical and anatomical information that may be useful for biomechanical studies.

In this study the use of ultrasonography to aid in the location of a specific anatomical landmark significantly decreased the variability between examiners. Further studies using additional anatomical landmarks

and comparing ultrasound-guided marking with traditional procedures are warranted to determine the usefulness of ultrasonography as an ancillary method in equine motion analysis and its contribution to the reliability of data obtained.

Previous experience in locating anatomical landmarks using ultrasonography could minimize errors; however, in our study we depended on examiners with no ultrasound imaging skills, and thus, no comparisons could be established. Therefore, further studies may be required to confirm this hypothesis.

## Acknowledgements

The authors would like to thank to Dr. Luciana A. M. Silvano, from Hands On – Veterinary Rehabilitation Clinic, Jundiaí, São Paulo, Brazil, for her assistance with clinical examination of the horse and preparation of the calibration space.

## References

- AGUIRRE, D. A.; BERMUDEZ, S.; DIAZ, O. M. Spinal CT-guided interventional procedures for management of chronic back pain. *Journal of Vascular and Interventional Radiology*, v. 16, n. 5, p. 689-697, 2005.
- AUDIGIÉ, F.; POURCELOT, P.; DEGUEURCE, C.; DENOIX, J.; GEIGER, D.; BORTOLUSSI, C. Asymmetry in placement of bilateral skin markers on horses and effects of asymmetric skin marker placement on kinematic variables. *American Journal of Veterinary Research*, v. 59, n. 8, p. 938-944, 1998.
- COUSTY, M.; FIRIDOLFI, C.; GEFFROY, O.; DAVID, F. Comparison of medial and lateral ultrasound-guided approaches for periarticular injection of the thoracolumbar intervertebral facet joints in horses. *Veterinary Surgery*, v. 40, n. 4, p. 494-499, 2011.
- DELLA CROCE, U.; CAPPOZZO, A.; KERRIGAN, D. C. Pelvis and lower limb anatomical and mark calibration precision and its propagation to bone geometry and joint angles. *Medical & Biological Engineering & Computing*, v. 37, n. 2, p. 155-161, 1999.
- DELLA CROCE, U.; LEARDINI, A.; CHIARI, L.; CAPPOZZO, A. Human movement analysis using stereophotogrammetry Part 4: assessment of anatomical landmark misplacement and its effects on joint kinematics. *Gait Posture*, v. 21, n. 2, p. 226-237, 2005.
- FABER, M.; JOHNSTON, C.; SCHAMHARDT, H.; VAN WEEREN, R.; ROEPSTORFF, L.; BARNEVELD, A. Basic three-dimensional kinematics of the vertebral column of horses trotting on a treadmill. *American Journal of Veterinary Research*, v. 62, n. 5, p. 757-764, 2001.
- FIGUEROA, P. J.; LEITE, N. J.; BARROS, R. M. L. A flexible software for tracking of markers used in human motion analysis. *Computer Methods and Programs in Biomedicine*, v. 72, n. 2, p. 155-165, 2003.
- GALIANO, K.; OBWEGESER, A. A.; WALCH, C.; SCHATZER, R.; PLONER, E.; GRÜBER, H. Ultrasound-guided versus computed tomography-controlled facet joint injections in the lumbar spine: a prospective randomized clinical trial. *Regional Anesthesia and Pain Medicine*, v. 32, n. 4, p. 317-322, 2007.
- LICKA, T.; PEHAM, C.; ZOHMANN, E. Range of back movement at trot in horses without back pain. *Equine Veterinary Journal*, v. 33, p. 150-153, 2001. Supplement.
- R DEVELOPMENT CORE TEAM. **R**: a language and environment for statistical computing. Vienna: R Foundation for Statistical Computing, 2013.
- ROSENSTEIN, D. S.; BULLOCK, M. S.; OCELLO, P. J.; CLAYTON, H. M. Arthrocentesis of the temporomandibular joint in adult horses. *American Journal of Veterinary Research*, v. 62, n. 5, p. 729-733, 2001.
- SCHNEEWEISS, W.; PUGGIONI, A.; DAVID, F. Comparison of ultrasound-guided vs. "blind" techniques for intra-synovial injections of the shoulder area in horses: scapulohumeral joint, bicipital and infraspinatus bursae. *Equine Veterinary Journal*, v. 44, n. 6, p. 674-678, 2012.
- SMALL, C. F.; PICHORA, D. R.; BRYANT, J. T.; GRIFFITHS, P. M. Precision and accuracy of bone landmarks in characterizing hand and wrist position. *Journal of Biomedical Engineering*, v. 15, n. 5, p. 371-378, 1993.
- WHITE, S. C.; YACK, H. J.; WINTER, D. A. A three-dimensional musculoskeletal model for gait analysis. Anatomical variability estimates. *Journal of Biomechanics*, v. 22, n. 8-9, p. 885-893, 1989.