

## Natural infections with filarioidea nematodes in *Hydrochoerus hydrochaeris* in the floodplain of Mato Grosso do Sul, Brazil

### Infecções naturais com nematódeos Filarioidea em *Hydrochoerus hydrochaeris* no Pantanal do Mato Grosso do Sul, Brasil

Adjair Antonio do NASCIMENTO<sup>1</sup>; Marcos Roberto BONUTI<sup>1</sup>; José Hairton TEBALDI<sup>1</sup>; Elaine Bernardo MAPELI<sup>1</sup>; Isaú Gouveia ARANTES<sup>1</sup>

CORRESPONDENCE TO:  
Adjair Antonio do Nascimento  
Departamento de Medicina Veterinária  
Preventiva e Reprodução Animal  
Faculdade de Ciências Agrárias e  
Veterinárias da UNESP  
Campus de Jaboticabal  
Via de Acesso Prof. Paulo Donato  
Castellane, s/n  
14884-900 – Jaboticabal – SP  
e-mail: adjair@fcav.unesp.br

<sup>1</sup>-Departamento de Medicina Veterinária  
Preventiva e Reprodução Animal da  
Faculdade de Ciências Agrárias e  
Veterinárias da UNESP, Campus de  
Jaboticabal – SP

#### SUMMARY

From 36 capybaras, slaughtered between 1989 and 1996, 11 young, less than 6 months old, and 25 adults, in the floodplain region of Mato Grosso do Sul, 570 Filarioidea nematodes were collected. Three hundred and ninety-four specimen of *Cruorifilaria tubero cauda* were collected from the renal arteries (380) and from pulmonary arteries (14) and 176 specimen of *Yatesia hydrochoerus* from the fasciae of skeletal muscles, mainly from the *obliquus externus abdominis* region and from the internal faces of hind limbs.

**UNITERMS:** Nematoda; Filarioidea; Capybara; *Hydrochoerus hydrochaeris*.

#### INTRODUCTION

The capybara (*Hydrochoerus hydrochaeris*, L. 1766), a wild rodent of semi aquatic habits, inhabits the surroundings of river banks, dams, bays and swamps. This rodent is, under domestication in several States of Brazil, with the aim of producing a high quality feedingstuff, of sound proteic value and low caloric content. It can be parasited by helminths which determine from gastrointestinal mucosa erosions to extense ceccum and colon ulcerations, endoarteritis, hypertrophia of vessel walls (intima and media) and renal pyramidal infarction.

The filariases of capybaras have been recently described in Venezuela<sup>2,4,10,11</sup>, Colombia<sup>5,12,13</sup> and Brazil<sup>1,3,8,9</sup>. In these studies, five species of Filarioidea were identified: *Dirofilaria acutuscula*, *Cruorifilaria tubero cauda*, *Yatesia hydrochoerus*, *Mansonella longicapita* and *Mansonella rotundicapita*. The objectives of the present study were to determine the species of Filarioidea which parasite capybaras in the floodplain of Mato Grosso do Sul, as well as to investigate the characteristics of infections, such as: prevalence, intensity, mean intensity and abundance.

#### MATERIAL AND METHOD

#### Physiographic Region

The floodplain region of Mato Grosso do Sul (Paiaguás) is an ecological system with an area of 25,457 km<sup>2</sup>, of open pasture with patches of stunted vegetation, well-defined wet and dry seasons and a mean temperature about 28°C in summer

#### Animals

Thirty-six capybaras, 11 young (less than 6 months old) and 25 adults, infected naturally, slaughtered in the floodplain between 1989 and 1996, in the counties of Pedro Gomes (7), Corumbá (17) and Coxim (12), Mato Grosso do Sul, were used in this study.

#### Methods

Following the slaughter, each animal was esfoliated, and skin and carcass examined macroscopically (muscle fasciae). Approximately 50% of the skin was divided into fragments of 30 cm<sup>2</sup> and maintained for 3 hours in water-bath, in metal trays containing a thin layer (2 cm) of saline solution (0.85% of NaCl) at the temperature of 37°C. At the end of this period, the obtained material was macroscopically examined and the worms found, both in

the muscle fasciae and the skin, were fixed in formol-acetic. Immediately after the host death, the examination of the heart blood vessels, lungs and kidneys was conducted by incision with a 10.5 cm thin end pair of scissors. The morphological studies of nematodes were accomplished<sup>5,13</sup>, after the consecutive diafanization in glacial acetic acid and Faya creosoto. Renal fragments were fixed in Bouin fluid, processed routinely, and stained with hematoxiline-eosin. The ecological terms (prevalence, intensity, mean intensity, abundance) are the committee's recommendations of the American Society of Parasitologists<sup>6</sup>.

### RESULTS

In 13 capybaras Filarioidea nematodes were not found; 11 of these capybaras were young animals aging less than 6 months old. Infections with only one species of worm were observed in ten animals, and in 13 with 2 nematodes species. The total worm burden found in 23 capybaras was 570 nematodes adults, being 176 specimens

of *Y. hydrochoerus* obtained from the fasciae, *obliquus externus abdominis*, region mainly in the internal face of the muscles from the hind limbs, and occasionally from the lumbar region (Fig. 1A) and 394 specimen of *C. tubero cauda* from the renal (380 worms) (Fig. 1B) and pulmonary arteries (14 worms) (Tab. 1).

The number of *Y. hydrochoerus* varied from 1 to 40 worms per animal and *C. tubero cauda* counts ranged from 1 to 134 nematodes.

In relation to the pathogeny of *C. tubero cauda*, which develops mainly in the capybara kidneys, the hystopathological examination showed that the main lesions occurred in the artery walls and consisted of endoarterites, hypertrophia of the vessel walls (intima and media) and rugged protuberance which invades the arterial lumen, causing renal pyramidal infarction. Renal arteries hasting dead and decalcified worms, granulomatous proliferation reached to the renal parenquima (Fig. 1C). Besides these lesions, a renal atrophy and presence of marked depressions on the surface of the organ were observed (Fig. 1D), suggesting cicatricial lesions.

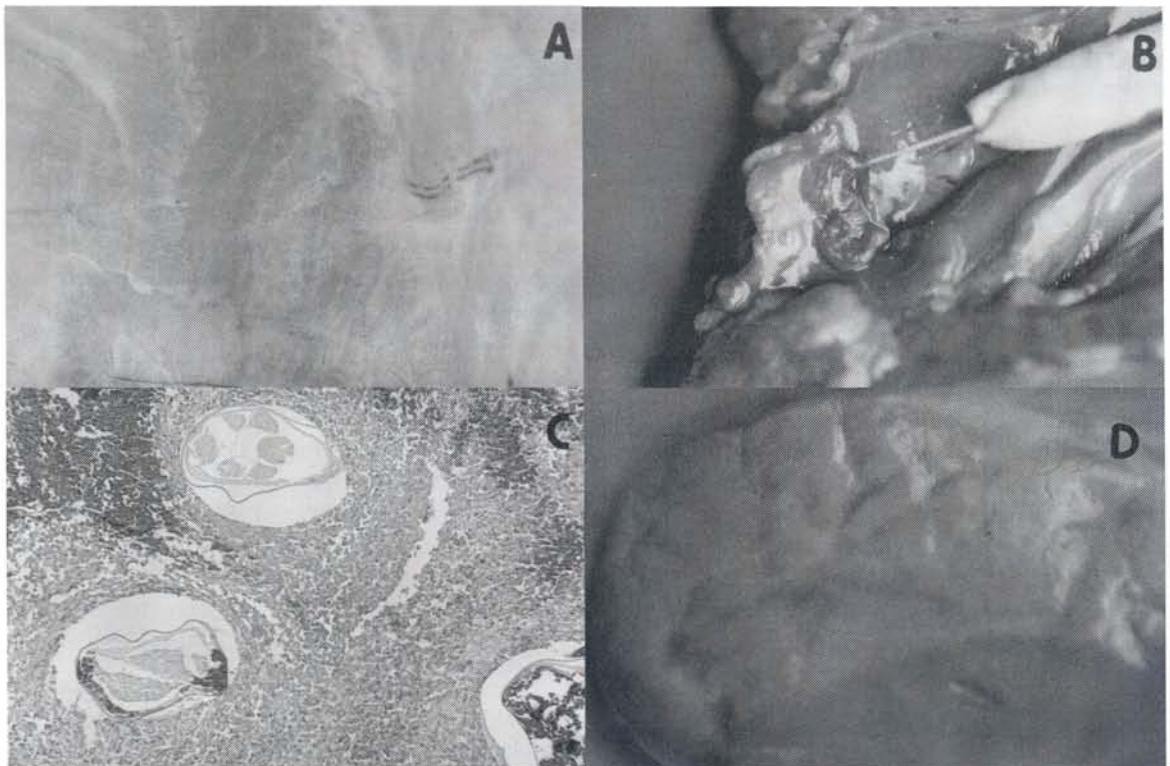


Figure 1

A = Fasciae of skeletal muscles parasitized for *Y. hydrochoerus*; B = Kidney of capybara parasitized by *C. tubero cauda*; C = Renal arteries hasting dead and decalcified worms; D = Marked depression on the surface of kidney parasitized by *C. tubero cauda* HE (obj X).

**Table 1**

Prevalence, intensity, mean intensity and abundance of the Filarioidea nematodes parasites of the renal and pulmonary arteries and fasciae of skeletal muscles, found in capybaras slaughtered between 1986 and 1996 in the counties of Pedro Gomes, Corumbá and Coxim, from floodplain region of Mato Grosso do Sul, Brazil.

Species of Nematodes	Host Location	Number of Animals	Infection Intensity	Mean Intensity	Abundance	Prevalence	Total of Nematodes
<i>Cruorifilaria tubero cauda</i>	Renal and Pulmonary Arteries	36	1 - 134	20,70	10,94	52,70	394
<i>Yatesia Hydrochoerus</i>	Fasciae Skeleptical Muscles	36	1 - 40	10,35	4,88	47,20	176

## DISCUSSION

The careful examination of skeletal muscle fasciae taken immediately after slaughtering the animals, revealed the presence of *Y. hydrochoerus* in 47% of the capybaras. The adult worms do not produce important lesions (Fig. 1A), but their presence in the fasciae represent objections to the commercialization of frozen meat. The results of the infection intensity of *Y. hydrochoerus*, characterized by low and moderate values (Tab. 1), differed from the high rates of prevalence (93.5%) observed in Colombia<sup>13</sup>, but on the other hand were similar to the data obtained in Brazil<sup>3,9</sup>.

The observations on the basic characteristics of

infections of *C. tubero cauda* revealed a prevalence of 52.7%, which are similar to data presented by other authors<sup>2,3,8,9,10</sup> and differed from those reported in Colombia<sup>5</sup>. Besides, low values of mean intensity (20.7 worms) and of abundance (10.94 nematodes) were obtained in this study.

The renal lesions observed in the present study were similar to those in Colombian capybaras<sup>7</sup> that presented villous endarteritis, intimal and medial hypertrophy of the vessel walls and large rugose protuberances that encroached upon the lumen leading to pyramidal infarcts in the kidneys. The renal atrophy and depressions found on the surface of the organ (Fig. 1D) seem to be related to the areas of tecidual retraction, due to the proliferation of the intertubular connective tissue.

## RESUMO

Foram coletados 570 nematódeos Filarioidea de 36 capivaras, sacrificadas entre 1989 e 1996, onze jovens menores que seis meses e 25 adultas, provenientes da região do pantanal do Mato Grosso do Sul (Paiaguás). Cento e setenta e seis (176) espécimes de *Yatesia hydrochoerus* foram encontrados nas fâscias dos músculos esqueléticos, principalmente da região do *obliquus externus abdominis* e na face interna dos membros posteriores e trezentos e noventa e quatro (394) espécimes de *Cruorifilaria tubero cauda* foram coletados das artérias renais (380) e das artérias pulmonares (14) dos animais.

**UNITERMOS:** Nematoda; Filarioidea; Capivaras; *Hydrochoerus hydrochaeris*.

## REFERENCES

- 1- ARANTES, I.G.; ARTIGAS, P.T.; NASCIMENTO, A.A. Helminths parasites of capivaras (*Hydrochoerus hydrochaeris* Linnaeus, 1766) no Brasil. In: ENCONTRO DE PESQUISAS VETERINÁRIAS, 10., Jaboticabal, 1985. **Resumos**. p.68.
- 2- CALDERON-RODRIGUEZ, H.; CASTILLO-BRITO, E.; LOZANO-PEREZ, F. Aspectos fisiológicos y sanitários del chiguire. **Cespedesia**, v.4, p.16-23, 1975.
- 3- COSTA, C.A.F.; CATTO, J.B. Helminths parasites of capivaras (*Hydrochoerus hydrochaeris*) na sub-região de Nhecolândia, Pantanal Sul-Matogrossense. **Revista Brasileira Biologia**, v.54, n.1, p.39-48, 1994.
- 4- EBERHARD, M.L.; CAMPO-AASEN, I.; ORIHIEL, T.C. *Mansonella* (E) *rotundicapita* sp. n. e *Mansonella* (E) *longicapita* sp. n. (Filarioidea: Onchocercidae) from Venezuelan capybaras (*Hydrochoerus hydrochaeris*). **Annales Parasitologie Humaine Compare**, v.59, n.5, p.497-505, 1984.
- 5- EBERHARD, M.L.; MORALES, G.A.; ORIHIEL, T.C. *Cruorifilaria tubero cauda* gen. et sp. n. (Nematoda: Filarioidea) from the capybara, *Hydrochoerus hydrochaeris* in Colombia. **Journal of Parasitology**, v.69, n.3, p.606-9, 1976.
- 6- MARGOLIS, L.; ESCH, G.W.; HOLMES, J.C.; KURIS, A.M.; SCHAD, G.A. Use of ecological terms in parasitology (Report of an Ad Hoc committee of the American Society of Parasitologists). **Journal of Parasitology**, v.68, n.1, p.131-3, 1982.

- NASCIMENTO, A.A.; BONUTI, M.R.; TEBALDI, J.H.; MAPELI, E.B.; ARANTES, I.G. Natural infections with Filarioidea nematodes in *Hydrochoerus hydrochaeris* in the floodplain of Mato Grosso do Sul, Brazil. **Braz. J. vet. Res. anim. Sci.**, São Paulo, v. 37, n. 2, p. 105-108, 2000.
- 7- MORALES, G.A.; GUZMAN, V.H.; ANGEL, D. Vascular damage caused by *Cruorifilaria tubero cauda* in the capybara (*Hydrochoerus hydrochaeris*). **Journal of Wildlife Diseases**, v.14, n.1, p.15-21, 1978.
- 8- NASCIMENTO, A.A.; BONUTI, M.R.; TEBALDI, J.H.; MAPELI, E.B.; ARANTES, I.G. Nematódeos Filarioidea Parasitos de Capivaras (*Hydrochoerus hydrochaeris*) Procedentes do Mato Grosso do Sul. In: CONGRESSO BRASILEIRO DE MEDICINA VETERINÁRIA, 24., Goiânia, 1996. **Anais**. p.234.
- 9- NASCIMENTO, A.A.; TEBALDI, J.H.; FERREIRA, P.S.U.; ARANTES, I.G. *Dipetalonema (Alafilaria) hydrochoerus*, Yates & Jorgenson, 1983, parasito de capivara (*Hydrochoerus hydrochaeris hydrochaeris* L. 1766) no Estado do Mato Grosso do Sul. In: ENCONTRO DE PESQUISAS VETERINÁRIAS, 14., Jaboticabal, 1992. **Resumos**. p.189.
- 10- OJASTI, J. **Estudio biológico del chiguire o capibara**. Caracas: Fondo Nacional de Investigaciones Agropecuarias, 1973. p.181.
- 11- TARBES, M.H. Sobre una coleccion de helmintos del chiguire (*Hydrochoerus hydrochaeris*) de Venezuela. **Revista Facultad Ciencias Veterinarias U.C.V.**, v.28, n.18, p.19-47, 1979/1980.
- 12- YATES, J.A. Microanatomical features of *Yatesia hydrochoerus* (Nematoda: Filarioidea) from Colombian capybaras. **Proceedings of the Helminthological Society Washington**, v.55, n.2, p.140-5, 1988.
- 13- YATES, J.A.; JORGENSON, J.P. *Dipetalonema (Alafilaria) hydrochoerus* subgen. et sp. n. (Nematoda: Filarioidea) from Colombian capybaras. **Journal of Parasitology**, v.69, n.3, p.606-9, 1983.

Received: 03/08/1998

Accepted: 03/09/1999