

## Myelography in healthy dogs using ioversol 240 mg I/ml contrast medium. Clinical and radiological results

### Mielografia em cães sadios com o meio de contraste ioversol 240 mg I/ml. Resultados clínicos e radiológicos

Luciana Virgínia Costa SARMENTO<sup>1</sup>; Eduardo Alberto TUDURY<sup>2</sup>; Eduardo Luiz Cavalcanti CALDAS<sup>2</sup>; Patrícia Karla de Luna MAGALHÃES<sup>2</sup>; Éricka Rejane Correia ALBUQUERQUE<sup>2</sup>

CORRESPONDENCE TO:  
Luciana Virgínia Costa Sarmiento  
Rua Pedro Antônio da Silva, 37 -  
Piedade - 54400-400 - Jaboatão  
dos Guararapes - PE  
e-mail: lvcsarmiento@bol.com.br

1- Médica Veterinária Autônoma  
2- Departamento de Medicina  
Veterinária da Universidade  
Federal de Pernambuco - PE

#### SUMMARY

This study aimed to assess the opacification period and diagnostic quality of ioversol 240 mg I/ml in the thoracic and lumbar regions after intracisternally injected, and evaluate its effects on the nervous system by clinical and neurological examinations. Thirty clinically normal non-descript dogs without sex distinction, weighing 9-12 kg were divided into three groups of 10 animals each. All the animals were anaesthetized using diazepam and thiopental sodium. Ioversol was injected at a dose of 0.5ml/kg. Cervical radiographs after 5 minutes to confirm injection of the contrast, and thoracolumbar radiographs after 30, 40, 50 and 60 minutes to evaluate the opacification period were taken. Clinical and neurological examinations were performed daily until 7, 14 and 28 days for groups I, II and III respectively. Adverse reactions such as pedal movements, preconvulsive behavior, muscular spasms, apnea, dyspnea, and vomit anxiety were observed during the myelographic procedure only. Ioversol showed good radiopacity, diffusion and miscibility with the cerebrospinal fluid. Reduction of costs also was possible since it can be autoclaved. Opacification period with diagnostic value was of 60 minutes in 60% of thoracic radiographs and in 80% of lumbar radiographs. Ioversol showed low incidence of clinical and neurological alterations. It is concluded that ioversol 240 mg I/ml is appropriate and safe to be used for myelography in dogs.

UNITERMS: Myelography; Dogs; Contrast media.

#### INTRODUCTION

Myelography is a spinal cord radiographic study that uses a contrast medium injected into the subarachnoid space<sup>14</sup>. Myelography is indicated if there are neurological alterations and normal survey radiographs; if multiple abnormalities are evident on survey radiographs; if neurological signs do not correspond to survey radiographs; to locate and to characterize a lesion when surgery is needed; if neurological signs recur after decompressive surgery<sup>2,4,5,12</sup> and when the diagnosis of neurological disease is made by exclusion of spinal cord compression<sup>12</sup>. Myelography is contraindicated in patients displaying signs of convulsion, increased intracranial pressure, dehydration, virus or bacteria infection, and cutaneous infection on puncture site<sup>9,10,14</sup>.

Myelography is an important diagnostic aid of neurological diseases. Therefore, researches have studied contrast agents quality<sup>15</sup>, neurotoxicity<sup>11</sup> and opacification period in the subarachnoid space<sup>3,13,19</sup>. The ideal contrast agent for myelography should be radiopaque, miscible with cerebrospinal fluid, non-toxic to the nervous system, water soluble, rapidly absorbed, but with skilful time to obtain multiple radiographs, and affordable<sup>17</sup>.

Ioversol 240 mg I/ml Optiray<sup>®</sup> 240<sup>a</sup> is water soluble, non-ionic and is indicated for human patient myelography<sup>6</sup>. Although

ioversol 240 mg I/ml is still not used normally in animals, researches using other concentrations have found significant qualities. Ioversol 430 mg I/ml was administered via intrathecal routes to rats (0.93-2.79 ml/kg), demonstrating less toxicity than iohexol and iopamidol<sup>11</sup>, the most commonly used drugs for veterinary myelography<sup>17</sup>. In thiopental-anaesthetized dogs, ioversol was injected at 0.37 and 0.56 ml/kg. No deaths, preconvulsive behavior, convulsion or abnormal neurologic reflexes occurred 24 hours and 24 days post-injection<sup>11</sup>. In not anaesthetized monkeys given lumbar intrathecal injection of 0.33 ml/kg, transient tremors and muscular fasciculation were observed<sup>11</sup>.

Etherized rats were given up to a dose of 1,000 mg/kg of ioversol intracisternally (3 ml/kg of ioversol 320 mg I/ml). No deaths were observed, but chewing, dyspnea, apnea, hypoactivity and convulsion occurred<sup>16</sup>.

Ioversol 320 mg I/ml was injected intracisternally at a dose of 0.28 to 0.70 ml/kg in dogs. Opacification period considered diagnostic was between 30-40 minutes<sup>15</sup>. However, abnormalities such as limb retraction, tachycardia, transient apnea, tremors and muscular fasciculation were seen.

The objective of this study was to determine the neurotoxicity of ioversol by clinical and neurological examinations during and after myelography. Also determined myelographic quality and opacification period in the thoracolumbar subarachnoid space when injected into the cisterna magna.

<sup>a</sup> Mallinckrodt Medical Inc. Pointe-Claire, Quebec, Canada.

## MATERIAL AND METHOD

A total of thirty clinically normal non-descript dogs without sex distinction and weighing 9-12 kg of the Animal Surveillance Center of Recife were used in this study. After clinical and neurological examinations the dogs were vaccinated and dewormed. The animals were quarantined for at least 15 days prior to treatment. During this period, if any abnormality was noticed, the animal was discarded and replaced. Canine commercial food and water were provided *ad libitum*. Before the myelography, the dogs were starved for at least 12 hours. The dorsal cranial cervical region was clipped and aseptically prepared. Diazepam 0.5% at a dose of 1 mg/kg and thiopental sodium 2.5% at a dose of 12.5 mg/kg were used as preanesthetic and anaesthetic protocols. Thiopental sodium was reinjected when necessary. Endotracheal tube was used so that ventilation could be possible if necessary. With the animal in lateral recumbency, ioversol 240 mg/ml at a dose of 0.5 ml/kg was injected intracisternally and then the head and trunk were raised to an angle of 45° to facilitate caudal migration of the contrast to the thoracolumbar subarachnoid space. After 5 minutes lateral cervical myelogram was obtained to confirm correct injection and after 30, 40, 50 and 60 minutes thoracolumbar myelogram was taken to determine the opacification period. While radiographs were made, the animal was held in a horizontal position. Qualities characteristics of the contrast agent such as radiopacity, opacification period and miscibility were determined. Ioversol was autoclaved at 120°C during 20 minutes and used in other myelographic procedures. Clinical and neurological examinations following myelography were performed daily until days 7, 14 and 28 for groups I, II and III respectively, with 10 animals each. The animals were divided into groups because cerebrospinal fluid was also analysed before and after myelography until these data and the results were presented in a future work. The diagnostic quality of the contrast until 60 minutes period was graded as follows: no contrast (total absence of contrast), not appropriate (not appropriate for diagnosis), and appropriate (when the contrast columns were perfectly visible allowing diagnosis). Thoracic and lumbar regions were assessed separately.

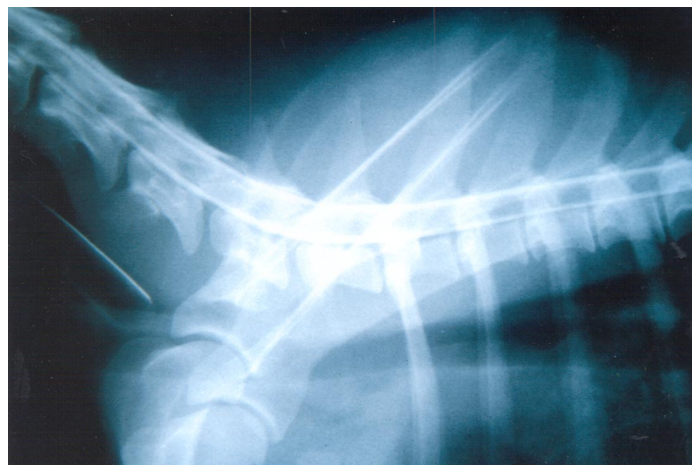## RESULTS

In general, ioversol 240 mg I/ml showed adequate diagnostic quality and miscibility, and excellent subarachnoid diffusion as well. All cervical radiographs taken five minutes after injection of ioversol 240 mg/ml showed the presence of contrast agent in the subarachnoid space (Fig. 1). These following results consider a total of 120 thoracolumbar myelograms, 30 myelograms for each period of time (30, 40, 50 and 60 minutes). Thoracic and lumbar regions were assessed separately (Tab. 1). At 30 minutes period at the thoracic region, 10% of the myelograms showed absence of contrast, 26.6% showed not appropriate opacification and 63.3% showed appropriate opacification. At the same period of time at the lumbar region, there were no cases of absence of contrast, 13.3% were not appropriate and 86.6% were appropriate for diagnosis. At 40 minutes, no contrast was visualized on 6% of the myelograms at the thoracic region, 33.3% were not appropriate and 60% were appropriate. At the lumbar region the results

remained the same as at 30 minutes. At 50 minutes period at the thoracic region 10% showed no contrast, 33.3% were not appropriate and 56.6% were appropriate. At the lumbar region, no cases of absence of contrast were found, 20% did not have diagnostic value, and 80% were appropriate for diagnosis. At 60 minutes 10% of the thoracic myelograms showed no contrast, in 30% the contrast was present but was not appropriate for diagnosis and 60% were appropriate for diagnosis. At the lumbar region the results remained the same as at 50 minutes (Fig. 2).

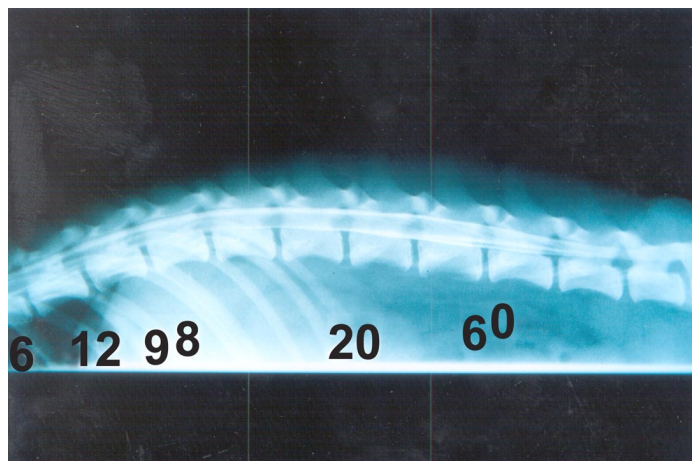
A total of 92 of 120 thoracolumbar myelograms showed the dorsal contrast column thicker than the ventral contrast column. Ioversol 240 mg/ml was repeatedly autoclaved without showing any radiological quality alteration or turbidity.

Minimum clinical and neurological abnormalities were found related to the myelographic procedure. Only five of the 30 animals studied showed myelographic complications. Two animals, one of group I, and another of group II had dyspnea.



**Figure 1**

Presence of ioversol 240 mg I/ml contrast medium in the cervicothoracic region at five minutes.



**Figure 2**

Presence of ioversol 240 mg I/ml contrast medium in the lumbar region at 60 minutes.

The one of group II had also vomit anxiety; another animal of group II presented apnea, and was revived; pedal movements and preconvulsive behavior were found in one animal of group III; and muscular spasms were seen in one animal of group I. No post-myelographic complications were observed until 28 days.

## DISCUSSION

The quality of a contrast agent for myelography has to do not only with its diagnostic quality, but also with the period of time in which it stays in the subarachnoid space causing least adverse reactions. When the contrast is injected intracisternally, it takes 10 to 15 minutes to arrive at the thoracic region<sup>13</sup>. In this experiment, myelograms started to be processed only at 30 minutes. So the fact that there were some cases of not appropriate myelograms for diagnosis at 30 minutes at the thoracic region (26,6%); myelograms with ioversol 240 mg/ml should be taken between 15 and 30 minutes after injection to avoid a second injection of the contrast. Not appropriate opacification at the thoracic region at 30 minutes can be explained by fast diffusion of the contrast to the lumbar region<sup>15</sup>. That was noticed with all the lumbar myelograms that did not show any case of contrast absence during the 60 minutes studied. At the lumbar region, it was expected that the contrast would be present after 30 minutes (Tab. 1), but with diagnostic quality only until 40 minutes as reported Tudury et al.<sup>15</sup> with ioversol 320 mg/ml. Instead, at 60 minutes the myelograms showed the contrast was still present, whereas 80% with diagnostic value. Comparing with ioversol 320 mg/ml, ioversol 240 mg/ml demonstrated more efficiency not only because of its opacification period, but also its diagnostic quality.

Because of anatomical variation that occurs between the dorsal and ventral subarachnoid space, when the contrast is injected, the dorsal contrast column appears to be thicker than the ventral one<sup>7</sup>. It was possible to observe this in the majority of the cases, but not in all of them, due to myelograms with absence of contrast and not appropriate opacification.

Iodinated non-ionic contrast agents like ioversol can be autoclaved, supporting well high temperatures without deterioration<sup>2</sup>. This is very important when the myelographic procedure is being done in small animals and not all the contrast is used. The advantage is that you can lower the costs<sup>15</sup>, what makes myelography more affordable to animal owners and, therefore, a procedure that can be included in the routine of clinics and hospitals.

Similar or more serious abnormalities seen in this experiment were previously reported using other contrast mediums<sup>1,8,9</sup>, using ioversol 320 mg I/ml<sup>15,16</sup> and using ioversol

430 mg I/ml<sup>11</sup>. The low incidence of adverse reactions observed in this study was expected because ioversol has the highest hydrophilicity when compared to other contrast agents currently used for myelography. Ioversol 240 mg I/ml when compared with other concentrations has lower osmolality and consequently lower neurotoxicity. Apnea was previously reported using ioversol<sup>15,16</sup>. This episode was associated to its pharmacology<sup>18</sup> and also with its interaction with anaesthetics agents. Because of the small number of dogs presenting complications, the authors of this work considered the individuality of each animal also responsible for these complications.

## CONCLUSIONS

The opacification period with diagnostic value of ioversol 240 mg I/ml contrast medium injected intracisternally was of 60 minutes in 60% of thoracic radiographs and in 80% of lumbar radiographs. The stability of the contrast to heat when autoclaved was confirmed and cost reduction was possible. Minimum adverse reactions were observed. The contrast demonstrated adequate radiopacity, diffusion and miscibility with cerebrospinal fluid. It is concluded that ioversol 240 mg I/ml is appropriate and safe to be used for myelography in dogs.

**Table 1**

Diagnostic quality of ioversol contrast medium expressed in number of animals related to radiographic time and spine regions. Recife – PE, 1999.

Diagnostic Quality	Radiographic Time (Minutes)							
	30		40		50		60	
	T*	L**	T	L	T	L	T	L
No Contrast	3	0	2	0	3	0	3	0
Not Appropriate	8	4	10	4	10	6	9	6
Appropriate	19	26	18	26	17	24	18	24

\* T: thoracic region; \*\*L: lumbar region.

## ACKNOWLEDGMENTS

Fundação de Amparo à Ciência e Tecnologia (FACEPE), Humana Produtos Hospitalares, Bayer do Brasil S.A., Laboratórios Konig S.A. e Coopers Brasil Ltda.

## RESUMO

Este trabalho teve por objetivo avaliar o período de opacificação e a qualidade diagnóstica do ioversol 240 mg I/ml, nas regiões torácica e lombar após sua injeção na cisterna magna, e verificar seus efeitos sobre o sistema nervoso por meio de observações clínicas e neurológicas. Utilizaram-se 30 cães saudáveis, sem distinção de sexo ou raça, com peso entre 9 e 12 kg, divididos em três grupos de 10 animais cada. Nos animais anestesiados com diazepam e tiopental sódico, o ioversol foi injetado na dose de 0,5 ml/kg. Foram obtidas radiografias cervicais aos cinco minutos para confirmar a injeção do contraste e toracolombares aos 30, 40, 50 e 60 minutos para avaliar o período de opacificação. Exames clínicos e neurológicos foram realizados diariamente até os 7, 14 e 28 dias para os grupos I, II e III respectivamente. Efeitos adversos como movimentos de pedalagem, início de convulsão, espasmos musculares, apnéia, dispnéia e ânsia de vômito foram observados apenas durante o procedimento mielográfico. O ioversol apresentou boas radiopacidade, difusão e miscibilidade com o

líquor, oferecendo também a possibilidade de redução de custos, já que pode ser autoclavado. O tempo de opacificação do contraste com valor diagnóstico atingiu 60 minutos em 60% das radiografias torácicas e em 80% das radiografias lombares. Havendo baixa incidência de alterações clínicas e neurológicas, e apropriadas qualidades radiográficas, concluiu-se que o ioversol na concentração de 240 mg I/ml é adequado e seguro para ser utilizado em mielografia de cães.

UNITERMOS: Mielografia; Cães; Meios de contraste.

## REFERENCES

- 1- ADAMS, W. M. Myelography. **The Veterinary Clinics of North America: Small Animal Practice**, v. 12, n. 2, p. 295-311, 1982.
- 2- ALMEN, T. Development of nonionic contrast media. **Investigative Radiology**, v. 20, p. 2-9, 1985. Supplement 1.
- 3- COX, F. H.; JAKOVljeVIC, S. The use of iopamidol for myelography in dogs: a study of 27 cases. **Journal of Small Animal Practice**, v. 27, n. 3, p. 159-165, 1986.
- 4- KEALY, J. K. The skull and vertebral column. In: **Diagnostic radiology of the dog and cat**. Philadelphia: W. B. Saunders, 1987. p. 439-526.
- 5- KIRBERGER, R. M. Recent developments in canine lumbar myelography. **Compendium on Continuing Education for the Practicing Veterinarian**, v. 16, n. 7, p. 847-854, 1994.
- 6- LABORATÓRIO MALLINCKRODT MEDICAL. **Optiray. (Ioversol)**: classificação terapêutica e farmacológica. Rio de Janeiro, 1998. 15 p.
- 7- LAMB, C. R. Common difficulties with myelographic diagnosis of acute intervertebral disc prolapse in the dog. **Journal of Small Animal Practice**, v. 35, n. 11, p. 549-558, 1994.
- 8- LEWIS, D. D.; HOSGOOD, G. Complications associated with the use of iothexol for myelography of the cervical vertebral column in dogs: 66 cases (1988-1990). **Journal of the American Veterinary Medical Association**, v. 200, n. 9, p. 1381-1384, 1992.
- 9- LUTTGEN, P. J.; PECHMAN, R. D.; HARTSFIELD, S. M. Neuroradiology. **The Veterinary Clinics of North America: Small Animal Practice**, v. 18, n. 3, p. 501-528, 1988.
- 10- MORGAN, J. P. Neurological procedures in the dog and cat. In: **Techniques of veterinary radiography**. 5.ed. Iowa State: University Press/Ames, 1993. p. 239-254.
- 11- RALSTON, W. H.; ROBBINS, M. S.; COVENEY, J. R.; BLAIR, M. Acute and subacute toxicity studies of ioversol in experimental animals. **Investigative Radiology**, v. 24, n. 1, p. 2-9, 1989.
- 12- ROBERTS, R. E.; SELCER, B. A. Myelography and epidurography. **The Veterinary Clinics of North America: Small Animal Practice**, v. 23, n. 2, p. 307-328, 1993.
- 13- THILAGAR, S.; GOPAL, M. S.; MOHAMMED, M. S. Opacification time and period of iothexol and iopamidol myelograms. **Indian Veterinary Journal**, v. 73, n. 8, p. 863-865, 1996.
- 14- TUDURY, E. A. **Radiologia da coluna vertebral de pequenos animais**. Guia de estudo. Londrina: UEL, 1997. 38 p.
- 15- TUDURY, E. A.; ARIAS, M. V. B.; CAMARGO, P. L.; FARIA, M. L. E.; MACHADO, C. E. G. Meio de contraste ioversol em neurroradiologia canina. **Ciência Rural**, Santa Maria, v. 27, n. 4, p. 1-5, 1997.
- 16- WIBLE, J. H.; BARCO, S. J.; SCHERRER, D. E.; WOJDYLA, J. K.; ADAMS, M. D. Neurotoxicity of non-ionic X-ray contrast media after intracisternal administration in rats. **European Journal of Radiology**, v. 19, p. 206-211, 1995. Supplement.
- 17- WIDMER, W. R. Iothexol and iopamidol: new contrast media for veterinary myelography. **Journal of the American Veterinary Medical Association**, v. 194, n. 12, p. 1714-1716, 1989.
- 18- WIDMER, W. R.; BLEVINS, W. E. Veterinary myelography: A review of contrast media, adverse effects and technique. **Journal of American Animal Hospital Association**, v. 27, n. 2, p. 163-177, 1991.
- 19- WOOD, A. K. V.; FARROW, B. R. H.; FAIRBURN, A. J. Cervical myelography in dogs using iothexol. **Acta Radiology**, v. 26, n. 6, p. 767-770, 1985.

Received: 02/08/2000

Accepted: 02/07/2001