

doi: <http://dx.doi.org/10.11606/issn.1679-9836.v97i3p308-313>

Micropenis

Micropênis

**Bruno Nicolino Cezarino, Roberto Iglesias Lopes, Marcos Gianetti Machado,
Lorena Macalo Oliveira, Amilcar Martins Giron, Alessandro Tavares,
Maria Helena Sircilli, Francisco Tibor Denes**

Cezarino BN, Lopes RI, Machado MG, Oliveira L, Giron AM, Tavares A, Sircilli MH, Denes FT. Micropenis / *Micropênis*. Rev Med (São Paulo). 2018 May-June;97(3):308-13.

ABSTRACT: Micropenis refers to a normally structured penis, which is abnormally small, with a stretched length of less than 2.5 standard deviations (SD) below the mean of age or stage of sexual development. Patients with true micropenis usually have a 46,XY karyotype, associated to normally located male gonads, without any sign of other penile malformations. Penile length is measured from the point where the penis meets the pubic bone to the distal tip of the glans on maximal stretch, compressing any fat over suprapubic area. Differential diagnosis include buried penis (inability to adequately expose the penis, due to a severe phimosis associated to a decreased length of penile skin, which retain the shaft inside the preputial cavity), and obesity with excess fat pad over supra pubic area. The causes of congenital or true micropenis can be divided into three major groups: hypogonadotropic hypogonadism (pituitary/hypothalamic failure), hypergonadotropic hypogonadism (primary testicular failure) and idiopathic (associated with a functional hypothalamus–pituitary–testicular axis). Clinical treatment is based on testosterone therapy. Surgical treatment options are used after failed penile enlargement with testosterone therapy and include penile elongation, suprapubic fat pad aspiration and eventually neophalloplasty.

Keywords: Penis/abnormalities; Penis/pathology; Penis/physiopathology; Urology; Pediatrics; Endocrinology.

RESUMO: Micropênis refere-se a um pênis normalmente formado, anormalmente pequeno, com um comprimento inferior a 2,5 desvios-padrão (DP) abaixo da média da idade ou do estágio de desenvolvimento sexual. Pacientes com micropênis verdadeiro geralmente apresentam cariótipo 46, XY, associado a gônadas masculinas normalmente localizadas, sem qualquer sinal de outras malformações penianas. O comprimento do pênis é medido a partir do ponto onde o pênis encontra o osso púbico até a ponta distal da glândula no alongamento máximo, comprimindo qualquer gordura sobre a área suprapúbica. O diagnóstico diferencial inclui *buried penis* - penis embutido (incapacidade de expor adequadamente o pênis, devido a uma severa estomia associada à diminuição do comprimento da pele do pênis, que retém o eixo dentro da cavidade prepucial) e obesidade com excesso de gordura na região supra púbica. As causas do micropênis congênito ou verdadeiro podem ser divididas em três grandes grupos: hipogonadismo hipogonadotrófico (falência hipofisária / hipotalâmica), hipogonadismo hipergonadotrófico (insuficiência testicular primária) e idiopático (associado a um eixo hipotálamo-hipofise-testicular funcional). O tratamento clínico é baseado na terapia com testosterona. As opções de tratamento cirúrgico são usadas após falha do aumento do pênis com terapia de testosterona e incluem alongamento do pênis, aspiração de gordura suprapúbica e, eventualmente, neofaloplastia.

Descritores: Pênis/anormalidades; Pênis/patologia; Pênis/fisiopatologia; Urologia; Pediatria; Endocrinologia.

Departamento de Urologia Pediátrica, Hospital das Clínicas HCFMUSP, Faculdade de Medicina, Universidade de São Paulo, São Paulo, SP, BR.

ORCID: Cezarino B - <https://orcid.org/0000-0001-9161-7337>; Lopes RI - <https://orcid.org/0000-0002-6636-7679>; Machado M - <https://orcid.org/0000-0002-1657-1356>; Oliveira LM - <https://orcid.org/0000-0002-2540-164X>; Tavares A - <https://orcid.org/0000-0001-6783-8893>; Denes F - <https://orcid.org/0000-0003-2445-187X>.

Emails: bruno.cezarino@hc.fm.usp.br, robertoiglesias@terra.com.br, mgmduc@uol.com.br, lorena.macalo@gmail.com, amgiron@uol.com.br, alessandrotrzs@yahoo.com.br, mhps_msm@yahoo.com, stdenes@gmail.com.

Endereço para correspondência: Departamento de Urologia. Av. Dr. Eneas de Carvalho Aguiar, 455 - 7º andar. São Paulo, SP, BR.

INTRODUCTION

Micropenis refers to a normally structured penis, which is abnormally small, with a stretched length of less than 2.5 standard deviations (SD) below the mean of age or stage of sexual development¹ (Figure. 1). Micropenis may occur as an independent abnormality by itself or as a clinical finding with many syndromes. The reported incidence of true micropenis was reported to be 1.5 in 10,000 male children born between 1997 and 2000². Patients with true micropenis usually have a 46,XY karyotype, associated to normally located male gonads, without any sign of other penile malformations, such as hypospadias³ (Figure 2).



Figure 1 - Habitus in a 10-year-old boy with micropenis

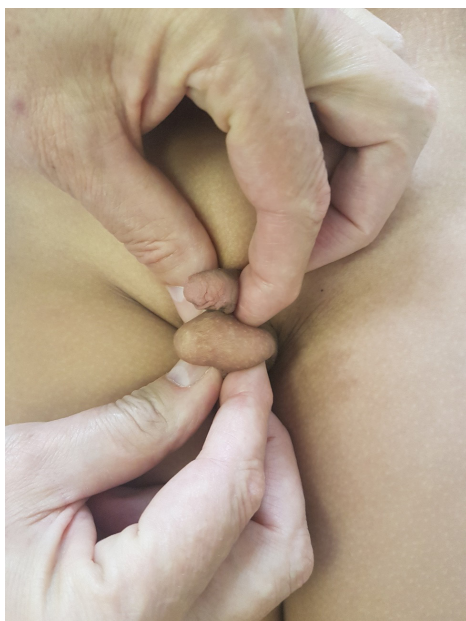

Figure 2 - Testes and urethra are topic

Normal Development

Normal development of male genitalia is a complex process that includes fetal gonadal stimulation by the placental Human Chorionic Gonadotrophin (hCG) starting at fifth week of gestation, leading to the production of Mullerian Inhibitory Substance (MIS) and 5- α -dihydrotestosterone (DHT), which are required for the development of male internal genital structures and differentiation of male external genitalia⁴. After eight weeks of gestation, testosterone itself begins to be produced and stimulates the intra-utero penile growth.

Without satisfactory hypothalamic or pituitary function, inadequate growth will occur despite a normal shaped penis. Similarly, a primary testicular disorder that causes insufficient testosterone production near the end of gestation also can result in minimal penile growth⁵.

Adequate Measurement and Diagnostic criteria

To prevent confounding diagnoses, the examining clinician must have a clear understanding of definition of micropenis. Penile length is measured from the point where the penis meets the pubic bone to the distal tip of the glans on maximal stretch, compressing any fat over suprapubic area⁶ (Figure 3).

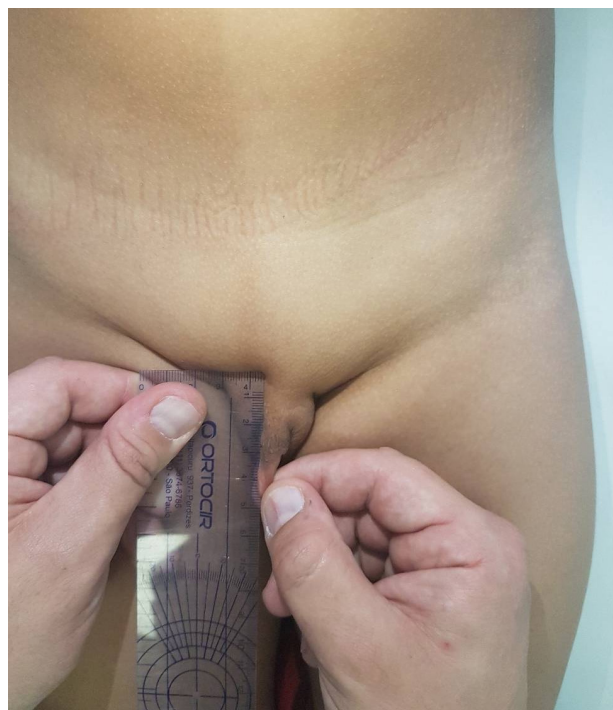

Figure 3 - Adequate measurement of penile length: note the depressed prepubic fat by the ruler, placed upon the pubic bone

Important to note that as the child body grows in a constant fashion until puberty, the penile growth is induced mostly by testosterone action⁷. As a result, immediately before puberty, children commonly have a large size disproportion between the penis and the rest of the body, causing anxiety and confusing parents about penile size. Table 1 shows the penile length and the standard deviation according to age. As stated before, micropenis is defined when the penile length is below 2.5 standard deviations when adequately measured.

Table 1 - Stretched penile length (in centimeters) by age

Age	Mean ± SD
Newborn (30 weeks)*	2.5 ± 0.4
Newborn (term)*	3.5 ± 0.4
0 to 5 months [†]	3.9 ± 0.8
6 to 12 months [†]	4.3 ± 0.8
1 to 2 years [†]	4.7 ± 0.8
2 to 3 years [†]	5.1 ± 0.9
3 to 4 years [†]	5.5 ± 0.9
5 to 6 years [†]	6.0 ± 0.9
10 to 11 years [†]	6.4 ± 1.1
Adult [‡]	12.4 ± 2.7

[†]Source: Schonfeld and Beebe (Feldman K. 1975;86:395-8).

[‡]Source: Wessells et al. (Schonfeld W, 1942).

*Source: Feldman and Smith (Wessells H, 1996).

Differential diagnoses

A) Buried penis

Buried Penis (BP) is an uncommon anomaly first described by Keyes in 1919 as “an apparent absence of the penis which occurs when it lacks its proper sheath of skin and lies buried beneath the integument of the abdomen, suprapubic fat or scrotum” (Figure 4). It is caused by the inability to adequately expose the penis, due to a severe phimosis associated to a decreased length of penile skin, which retain the shaft inside the preputial cavity, sometimes precluding adequate measurement of its length. Other terms used to describe the situation include concealed penis, inconspicuous penis, hidden penis, congenital mega-prepuce, trapped penis and webbed penis. Important to mention is that in buried penis the penile shaft is anatomically normal, presenting adequate size for the age of the patient. True buried penis is an uncommon condition and corrective surgery, that aims reconfiguration of the penile skin and prepuce, is always necessary¹¹ (Figure 5).

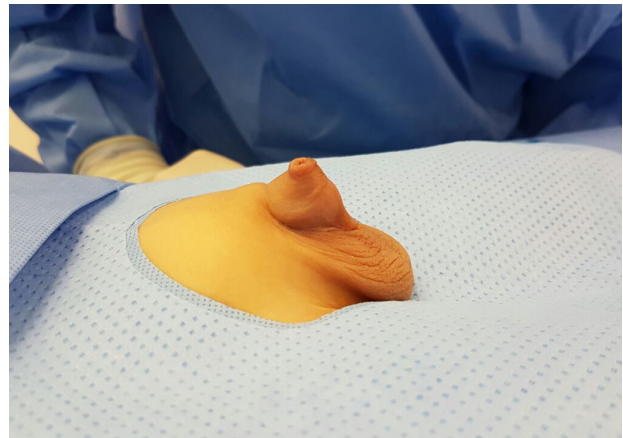


Figure 4 - Buried penis

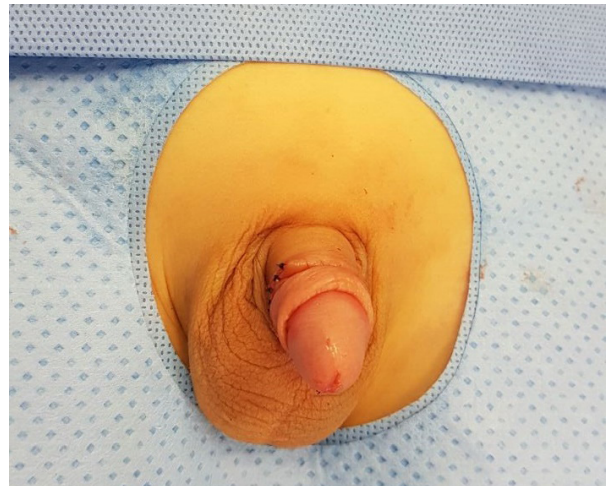

Figure 5 - Post-operative aspect of a buried penis, after reconfiguration of penile and preputial skin

B) Obesity and “fat over upper pubic area” (FOUPA) excess

As the number of infantile obesity increases, a crescent number of parents search medical attention complaining about the small penis of their sons. Obesity among children nowadays reaches approximately 8% in the first 5 years of life in Brazil, an increase of 79% when compared to 2008.

In these patients, besides the obvious obesity, the penis is also concealed within the pubic fat, extruding somewhat the penile skin and prepuce, therefore giving the appearance of a very small penis (Figure 6 and 7). Nevertheless, contrary to buried penis, it is possible to normally expose the penis, even if it is covered with an excess fat pad and if there is a slight phimosis. As in buried penis, the shape and size of the penis is normal for the age of the patient, but while buried penis requires surgical correction, the main treatment of FOUPA excess is weight control with physical and alimentary reeducation of the children.

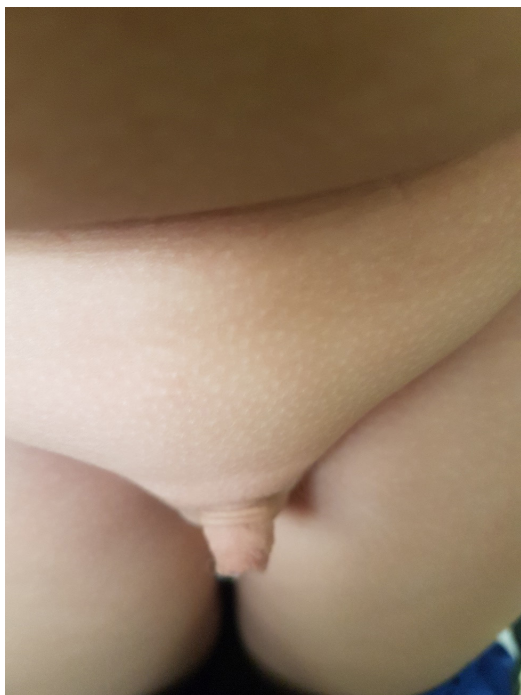


Figure 6 - Obese child with FOUPA simulating a micropenis

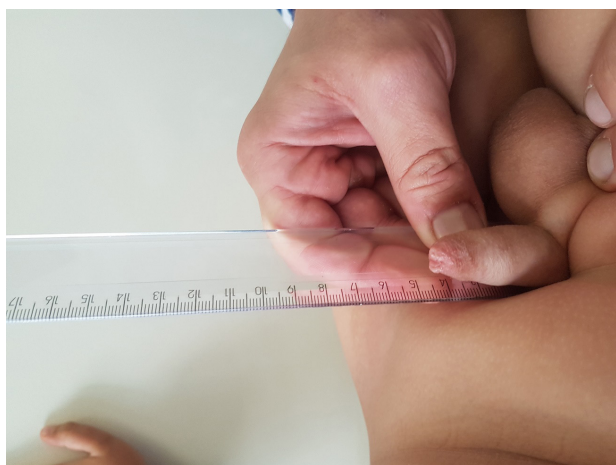

Figure 7 - Obese patient with FOUPA. Note that with compression of the prepubic fat the penile measurement is normal

Etiology and diagnostic tests

The causes of congenital or true micropenis can be divided into three major groups: hypogonadotropic hypogonadism (pituitary/hypothalamic failure), hypergonadotropic hypogonadism (primary testicular failure) and idiopathic (associated with a functional hypothalamus–pituitary–testicular axis). An isolated micropenis seems to occur more commonly with gonadotropin deficiency, whereas micropenis associated with hypospadias and/or undescended testes is often caused by lack of testosterone.

Endocrinologic assessment helps determine at what level is the cause of micropenis in the hypothalamic-pituitary-testicular axis. In addition to the central endocrine functions, testicular functions also need to be evaluated. Hence, serum testosterone levels are to be measured before and after administering exogenous hCG. This test is performed by intramuscular administration of hCG in a dose of 1000 units for 3 days: testosterone levels below 300 ng/dL may indicate gonadal dysgenesis. If LH and FSH levels are elevated, and there is no increase in testosterone levels following administration, testicular insufficiency or dysgenesis should be considered. In addition, measuring 17 hydroxyprogesterone, dehydroepiandrosterone, and androstenedione levels before or after the hCG stimulation test can reveal enzyme defects that play a role in testosterone synthesis¹².

Clinical treatment

Treatment of micropenis aims the increase of penile size sufficient for the patient to have an appropriate body image, normal sexual function, and standing micturition⁶. Treatment is based on testosterone supplementation administered for a short period to evaluate penile response. There is no consensus on the dose, method of administration or duration of testosterone therapy for micropenis¹³. Hatipoglu et al.¹² suggested that administration could be by intramuscular injection or topical application. In order to observe initial progress, four doses of 25 mg of testosterone cypionate or enanthate in oil can be administered intramuscularly once every 3 weeks for 3 months. Topical treatment is also employed. Arisaka et al.¹⁴ demonstrated increase in penile lengths in 50 infants and children aged between 5 months and 8 years, by administering 5% testosterone cream topically for 30 days. Testosterone absorbed transdermally was also shown to stimulate growth hormone (GH) secretion from the pituitary gland and promote bone growth by increasing insulin-like growth factor-1 production. Therefore, long-term dermal application of testosterone can also promote skeletal growth, as well as penile growth. Topical testosterone can be applied both directly at the penile skin or at internal thighs if any reaction occurs during the course of treatment.

Topical Dihydrotestosterone (DHT) is an alternative topical treatment. The enzyme 5α -reductase catalyzes the formation of DHT from testosterone in certain tissues including the prostate gland, seminal vesicle, epididymus, skin, hair follicle, liver, and brain. Relative to testosterone, DHT is considerably more potent as an agonist of the androgen receptor (AR). In prepubertal patients with androgen insensitivity, topical application of DHT gel to the periscrotal region 3 times daily for a total of 5 weeks has been shown to increase serum DHT levels¹². This treatment can provide penile length improvement in patients who did not respond to topical testosterone.

RESULTS

Usually a 100% fold or 3.5 cm increase in penile length is considered a good response. Repeat testosterone application or DHT gel can be used in cases of non-satisfactory penile size increase. Clinical studies have shown that testosterone treatment has positive effects on penile growth during infancy. However, these studies do not show whether this growth continues during adolescence and adulthood and a decrease of penile size gain can be observed in some patients late after the treatment.

Adverse reactions

Side effects are minimal. Topical or systemic testosterone treatment may cause temporary acceleration in growth rate and advance of bone age. Cutaneous reactions due to topic testosterone application were related. Changes in local application (i.e. inner thigh) may be required.

Long-term follow-up

The major problem regarding the management of micropenis is the lack of knowledge in term of long-term outcome. A number of studies^{15,16,17} showed that patients with micropenis reported normal male gender identity, good quality erections and sexual intercourse, even if always concerned with their genital appearance. Overall, it may safely be said that evidence points to normal gender identity and normal sexual function even in patients with failed treatment.

Surgical treatment

If endocrine treatment does not accomplish a satisfactory result, surgical therapy can offer an alternative in the management of micropenis. A simple procedure involves the elongation of the penis, despite the fact that it doesn't really improve the penile size. This technique aims to extend the pendular portion of penis, therefore improving the perception of penile size, by sectioning the suspensory ligament. Additional manouvers, such as suprapubic lipectomy and partial detachment of the *crura* from the pubic rami may further improve the cosmetic result. Satisfaction rates range from 30-65%²⁰. Important to note is that this elongation procedures are indicated to be performed only after puberty and after failed hormonal therapies. Corporal augmentation procedures have also been described in the setting of micropenis, with acceptable short term results, although no long-term data exist²⁰.

Other surgical options for a very small sized penis that failed hormonal treatment include neophalloplasty, with techniques that vary from osteocutaneous fibula flap, free scapular or forearm flaps, suprapubic abdominal wall flap and vertical rectus abdominis flap. These options are extremely challenging, with high complications rates even

in most experienced hands. Functional results, namely micturition and sexual activity of neophallus are variable: urethral strictures are often observed¹⁸ and sexual activity depends on the secondary successful implant of a penile prosthesis¹⁹.

REFERENCES

- Zenaty D, Dijoud F, Morel Y, Cabrol S, Mouriquand P, Nicolino M, et al. Bilateral anorchia in infancy: occurrence of micropenis and the effect of testosterone treatment. *J Pediatr*. 2006;149:687-91. doi: 10.1016/j.jpeds.2006.07.044.
- Nelson CP, Park JM, Wan J, Bloom DA, Dunn RL, Wei JT. The increasing incidence of congenital penile anomalies in the United States. *J Urol*. 2005;174(4 Pt2):1573-6.
- Vogt K. Microphallus. Emedicine from WebMD [cited 2007 Dec.]. Available from: <http://www.emedicine.com/PED/topic1448.htm>.
- Byne W. Developmental endocrine influences on gender identity, implications for management of disorders of sex development. *Mount Sinai J Med*. 2006;73:950-9.
- Shirley Tsang. When size matters: a clinical review of pathological micropenis. *J Pediatr Health Care*. 2010;231-40. doi: 10.1016/j.pedhc.2009.05.001.
- Wiygul J, Palmer LS. Micropenis. *Scientific World J*. 2011;1462-9. doi: 10.1100/tsw.2011.135.
- Feldman K, Smith D. Fetal phallic growth and penile standards for newborn male infants. *J Pediatr*. 1975;86:395-8.
- Schonfeld W, Beebe G. Normal growth and variation in male genitalia from birth to maturity. *J Urol* 1942;64:759-77.
- Wessells H, Lue T, McAninch J. Penile length in the flaccid and erect states: guidelines for penile augmentation. *J Urol*. 1996;156:995-7. [https://doi.org/10.1016/S0022-5347\(01\)65682-9](https://doi.org/10.1016/S0022-5347(01)65682-9).
- Hadidi AT. Buried penis: classification surgical approach. *J Pediatric Surg*. 2013;374-9. doi: 10.1016/j.jpedsurg.2013.09.066.
- Nihal Hatipoğlu, Selim Kurtoğlu. Micropenis: etiology, diagnosis and treatment approaches. *J Clin Res Pediatr Endocrinol*. 2013;217-23. doi: 10.4274/Jcrpe.1135.
- Sultan C, Paris F, Jeandel C, Lumbroso S, Galifer RB. Ambiguous genitalia in the newborn. *Semin Reprod Med*. 2002;181-8. doi: 10.1055/s-2002-35382.
- Arisaka O, Hoshi M, Kanazawa S, Nakajima D, Numata M, Nishikura K, Oyama M, Nitta A, Kuribayashi T, Kano K, Nakayama Y, Yamashiro Y. Systemic effects of transdermal testosterone for the treatment of micropenis in children. *Pediatr Int*. 2001;43:134-6. <https://doi.org/10.1046/j.1442-200x.2001.01353.x>.
- Reilly JM, Woodhouse. Small penis and the male sexual role. *J Urol*. 1989;142(2 Pt2):569-71. [https://doi.org/10.1016/S0022-5347\(17\)38818-3](https://doi.org/10.1016/S0022-5347(17)38818-3).

15. Lee PA, Houk CP. Outcome studies among men with micropenis. *J Pediatr Endocrinol Metabol.* 2004;1043-53.
16. Wisniewski AB, Migeon CJ. Long-term perspectives for 46,XY patients affected by complete androgen insensitivity syndrome or congenital micropenis. *Semin Reprod Med.* 2002;20:297-304. doi: 10.1055/s-2002-35376.
17. Rohrmann, D. Urethroplasty in female-to-male transsexuals. *Eur Urol.* 2003;44:611-4. [https://doi.org/10.1016/S0302-2838\(03\)00356-7](https://doi.org/10.1016/S0302-2838(03)00356-7).
18. Monstrey S, Hoebeke P, Selvaggi G, Ceulemans P, Van Landuyt K, Blondeel P, Hamdi M, Roche N, Weyers S, De Cuypere G. Penile reconstruction: is the radial forearm flap really the standard technique? *Plast Reconstr Surg.* 2009;124(2):510-8. doi: 10.1097/PRS.0b013e3181aeeb06.
19. Yang B, Liu XR, Hong QQ, Qiu RS, Ji CY. A comparative study on two kinds of surgical procedures of penile corpora cavernosa augmentation. *J. Plast. Reconstr. Aesthet. Surg.* 2009;62(3):357-64. doi: 10.1016/j.bjps.2008.11.033.
20. Campbell J, Gillis J. A review of penile elongation surgery. *Transl Androl Urol.* 2017;6(1):61-4.
21. Tomova A, Deepinder F, Robeva R, Lalabonova H, Kumanov P, Agarwal A. Growth and development of male external genitalia a cross-sectional study of 6200 males aged 0 to 19 years. *Arch Pediatr Adolesc Med.* 2010;164(12):1152-7. doi: 10.1001/archpediatrics.2010.223.

Submitted for publication: May 22, 2018

Accepted in: June 29, 2018